

A STUDY ON THE USE OF MUSA SPECIES IN THE MANAGEMENT OF RENAL CALCULI

PRASOBH G R^{1*}, REVIKUMAR K G²¹Moulana College of Pharmacy, Malappuram-679321, Kerala. ²Al Shifa College of Pharmacy, Malappuram-679322, Kerala.
Email: prasobhgr@yahoo.com

Received: 2 April 2014, Revised and Accepted: 17 May 2014

ABSTRACT

Objective: To study the use of *Musa* species in the management of renal calculi.**Methods:** Formulation and evaluation of *Musa AAB*.**Results:** A significant decrease in the size of kidney stone under *in vitro* condition was observed. This is due to the presence of organic constituents like β -sitosterol, quercetin, tannins, saponins and inorganic constituents like magnesium, potassium and nitrate. The result from these experiment demonstrate the potential of concentrated *Musa AAB* formulations extract was a good natural remedy against kidney stone.**Conclusion:** The recent treatment of urolithiasis involves NSAID's, Antidiuretics and Extracorporeal Shock Wave Lithotripsy. Recurrence is quite common with these therapies. The liquid formulation of the *Musa AAB* formulations may be useful to overcome the major drawback of surgical procedures which is recurrence of stones.**Keywords:** Allopurinol, Cystone, Kidney stones, *Musa AAB*, Urolithiasis

INTRODUCTION

Banana plants (*Musa* species) are of the family Musaceae. They are economic, easily available and found native to the tropical region. Many Indian plants have been quoted to be useful as antilithiatic agents. They are effective with fewer side effects and are also inexpensive. One of the important phenomena that characterize renal calculi is its high recurrence. Plantain juice is used as an antidote for snake bite. Studies in rats demonstrate effectiveness for stone lysis. The roots can arrest hemoptysis and possess strongly astringent and anthelmintic properties.[1] *Musa paradisiaca* is available in tincture or capsule. No toxicities and contraindication are reported in human yet. The easy digestibility and nutritional content make ripe banana an excellent food, particularly suitable for young children and elderly people. Bananas contain considerable amounts of vitamin B₆, vitamin C, and potassium.[2,3,4] In India, juice is extracted from the corm and used as a home remedy for jaundice, sometimes with the addition of honey, and for kidney stones. Kidney stones are a painful disorder of the urinary tract. Stones occur four times more often in men than in women. If the crystals remain tiny enough, they will travel through the urinary tract and pass out of the body in the urine without being noticed. The kidneys must maintain an adequate amount of water in the body to remove waste products. If dehydration occurs, high level of substances that do not dissolve completely (eg. Calcium, oxalate, uric acid) may form crystal that slowly build up into kidney stones. [5,6] Citrate binds with calcium in the urine, thereby reducing the amount of calcium available to form calcium oxalate stone. It also prevent tiny calcium oxalate crystals from growing and massing together into larger stones. Finally, it makes the urine less acidic, which inhibits the developments of both calcium oxalate and uric acid stone.[7,8] Magnesium is also one of the crystal inhibitor which present in urine. It act by increasing calcium solubility (especially in the urine) and reducing calcium absorption, magnesium can help to prevent kidney stone specially those composed of calcium oxalate. It is thought that calcium oxalate stone are most likely to form in people who are magnesium deficient, so it may just correct that deficiency. Literature has proved the explosive and solubilizing property of potassium nitrate. Extracts of stem showed the presence of alkaloids, steroids like β -sitosterol, saponins, flavonoids like

quercetin, reducing sugar, tannins and anthraquinones by chemical tests, UV, IR, Flame photometric studies and HPTLC studies.[9,10]

MATERIALS AND METHODS

Preparation of plant extract and *Musa AAB* syrup with materials

The stem of *Musa AAB*, cultivated in Thrissur (Kerala), identified by Agricultural University (Dr. Rema Menon, Kerala) and the specimen, herbarium no: 243/PHCG/Mlna was preserved in the Pharmacognosy laboratory, Malappuram. The stem were dried under shade, powdered and then extracted with methanol. Alcoholic extract was subjected for spray drying and made as a powder and that was subjected for *Musa AAB* syrup formulation by preparing decoction and made as a syrup and conducted evaluation procedures based on standard procedures. Allopurinol and cystone tablets was procured from Bangalore. The urea kit, creatinine monoreagent test kit and triglycerides test kit were procured from laboratory. *Musa AAB* syrup were prepared in Moulana College of Pharmacy, Angadippuram, Malappuram, Kerala using suitable equipments.

Animal selection and requirements

Healthy adult male albino wistar rats weighing between 150-250g were selected for the antiurolithiatic activity. The animals were acclimatized to standard laboratory conditions and maintained as per standard guidelines. Animals were provided with regular rat food and drinking water ad libitum. The animal care and experimental protocols were approved by Institutional Animal Ethical Committee (IAEC) Reg. No: (CADD/30/282/CPCSEA).

Study design

Animals were divided into five groups containing three animals in each. Group I served as control and received regular rat food and drinking water ad libitum. Ethylene glycol (0.75%) in drinking water was fed to Groups II to V for induction of renal calculi for 28 days. Group III received standard antiurolithiatic drug, Allopurinol (500mg/kg body weight) from 15th till 28th day. Group IV received *Musa AAB* syrup and Group V received Cystone from 15th till 28th day.

Sample analysis

The urine samples of 24 hour were collected on 28th day from all animals and they were priorly kept in individual metabolic cages. Animals had free access to drinking water during the urine collection period. A drop of concentrated hydrochloric acid was added to the urine before being stored at 4°C. Urine was analysed for calcium, phosphate and oxalate content.[11,12,13] After the experimental period, blood was collected from the retro-orbital under anesthetic condition and animals were sacrificed by cervical decapitation. Serum was separated by centrifugation and analysed for creatinine, uric acid and urea nitrogen. All animals were placed in separate metabolic cages for 24 hours and the total urinary volume was measured using the measuring cylinder and reported in ml. Uric acid crystals were found to be deposit most frequently in the concentrated urine. Thus the acidity of the urine was tested using the pH meter.[14,15] All rats were anaesthetized by diethylether at the end of the experiment say, 28th day and the kidneys were removed. For histological processing, the kidneys were fixed in 10% formalin, dehydrated in a gradient of ethanol, embedded in paraffin and cut into 5 µm serial sections. Ten slides containing five sections from each kidney were deparaffinized, stained with hematoxylin-eosin and examined by light microscope. Aggregations of calcium oxalate deposits were counted in fifty microscopic fields.[16,17,18] This was done by using one-way analysis of variance (ANOVA) followed by the Bonferroni test. The statistical significant was set at $P < 0.05$. The results were presented as mean ± standard error of mean

RESULT AND DISCUSSION

Oral administration of ethylene glycol aqueous solution to male albino rats produced hyperoxaluria. Oxalate, calcium and phosphate excretion were grossly increased in the calculi induced animals. Supplementation of *Musa AAB* formulations significantly lowered the increased levels of calcium, oxalate and phosphate in urine when compared to calculi induced group (Table I). Level of creatinine, blood urea nitrogen and serum were found to increase in calculi-induced animals (Table II). In case of *Musa AAB* formulations and Allopurinol the treatment significantly ($P < 0.001$) lowered the elevated level of creatinine, uric acid and blood urea nitrogen. Urine volumes were increased by *Musa AAB* formulations and Allopurinol as compared to the model control group. Urinary pH was significantly increased in the animals treated with the 0.75% v/v of ethylene glycol. *Musa AAB* formulations and Allopurinol significantly decreased the pH (Table III). Examination of kidney sections in control group showed no calcium oxalate deposits or other abnormalities in various segments of nephrons. Whereas in case of ethylene glycol group calcium oxalate deposits were found abundantly in different segments of nephron including proximal tubules, loop of Henle, distal tubules, collecting ducts and even in kidney calyces (Figure I and II). Renal tubular dilation with epithelial damage and leukocyte reaction were also observed on pathology examination (Figure III). The average number of calcium oxalate deposits in 50 microscopic fields in the kidney specimens of ethylene group was significantly higher than control group ($P < 0.001$). In present investigation there was a significant decrease in the size of kidney stone under *invitro* condition. This is due to the presence of organic constituents like β-sitosterol, quercetin, tannins, saponins and inorganic constituents like magnesium, potassium and nitrate. The result from these experiment demonstrate the potential of concentrated *Musa AAB* stem juice extract was a good natural remedy against kidney stone. Antioxidant property of *Musa AAB* have been proved by both superoxide scavenging activity and thiobarbituric acid methods.[19,20]

Table 1: Effect of *Musa AAB* extract on urinary salts of experimental animals (mg/g):

Sl.No	Group	Urine parameter		
		Oxalate (mg/g)	Calcium (mg/g)	Phosphate (mg/g)
1	Normal control	0.29±0.17**	0.40±0.31**	2.99±0.32**
2	Calculi	3.66±0.33	3.91±0.49	5.09±0.38

Sl.No	Group	Serum parameter		
		Blood urea nitrogen (mg/dl)	Creatinine (mg/dl)	Uric acid (mg/dl)
3	induced			
4	Allopurinol	0.43±0.27**	1.11±0.56***	3.26±0.14**
5	<i>Musa AAB</i> syrup	0.55±0.19*	1.34±0.28***	3.89±0.74**
5	<i>Musa AAB</i> tablet	0.56±0.42**	1.35±0.11**	4.12±0.25*

n = 3, * $P < 0.05$, ** $P < 0.01$, *** $P < 0.001$ vs model control; values are expressed in mean ± SEM; Statistics: one way ANOVA followed by the Bonferroni test

Table 2: Effect of *Musa AAB* extract on serum parameters of experimental animals (mg/dl):

Sl.No	Group	Serum parameter		
		Blood urea nitrogen (mg/dl)	Creatinine (mg/dl)	Uric acid (mg/dl)
1	Normal control	29.00±1.41**	0.27±0.41**	1.75±0.47***
2	Calculi induced	41.55±0.61	2.07±0.52	2.18±0.54
3	Allopurinol	29.00±0.02**	0.82±0.71***	1.38±0.23**
4	<i>Musa AAB</i> syrup	33.12±0.20**	0.84±0.43***	2.42±0.11**
5	<i>Musa AAB</i> tablet	29.20±0.46***	0.83±0.29*	2.49±0.01**

n = 3, * $P < 0.05$, ** $P < 0.01$, *** $P < 0.001$ vs model control; values are expressed in mean ± SEM; Statistics: one way ANOVA followed by the Bonferroni test

Table 3: Total urinary volume and pH of urine observed in *Musa AAB* extract

Sl.No.	Groups	Total urinary volume (ml)	pH of urine
1	Normal control	1.79±0.13**	7.44±0.06***
2	Calculi induced	1.26±0.08	9.01±0.11
3	Allopurinol	4.19±0.03***	6.59±0.06**
4	<i>Musa AAB</i> syrup	4.08±0.02***	6.17±0.02*
5	<i>Musa AAB</i> tablet	4.06±0.11**	6.17±0.05*

n = 3, * $P < 0.05$, ** $P < 0.01$, *** $P < 0.001$ vs model control; values are expressed in mean ± SEM; Statistics: one way ANOVA followed by the Bonferroni test

Renal calculi assessment:




Fig 1: Normal control

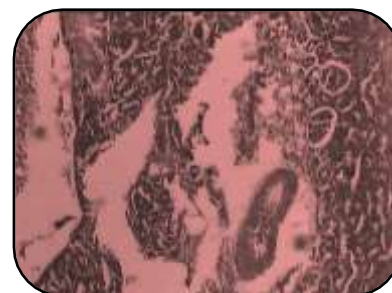

Fig 2: Calculi induced

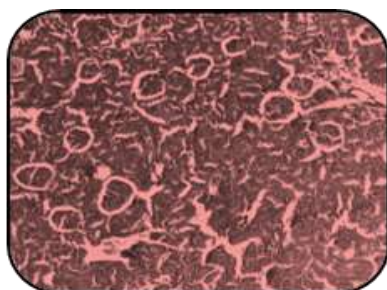


Fig 3: Allopurinol treated group

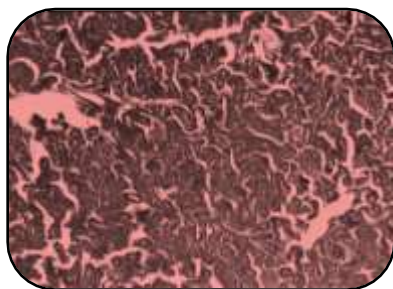


Fig 4: Musa AAB tablet

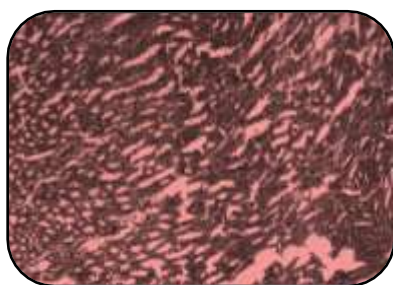


Fig 5: Musa AAB syrup

CONCLUSION

In the present study, calcium and oxalate excretion were increased in calculi induced animals. Increased urinary phosphate excretion along with oxalate seems to provide an environment appropriate for stone formation by forming calcium oxalate deposition. *Musa AAB* formulations restored the phosphate level, thus reducing the risk of stone formation. In calculi-induced rats (Group II), marked renal damage was seen by the elevated serum levels of creatinine, uric acid and blood urea nitrogen. Curative treatment of *Musa AAB* formulations and Allopurinol caused diuresis and hastened the process of dissolving the preformed stones and prevention of new stone formation in the urinary system. The diuretic effect of *Musa AAB* formulations was evident from urine volumes collected when compared to the model control group. The results indicated that the administration of *Musa AAB* formulations to albino wistar rats with ethylene glycol induced lithiasis reduced the growth of the urinary stones. The present study aims to give data highlighting the present trends in research of medicinal plants accredited with

antiurolithiatic activity. The recent treatment of urolithiasis involves NSAID's, Antidiuretics and Extracorporeal Shock Wave Lithotripsy. Recurrence is quite common with these therapies. The liquid formulation of the *Musa AAB* formulations may be useful to overcome the major drawback of surgical procedures which is recurrence of stones. The present study will be an initiative towards the commercialization of Herbal preparations in the Pharmaceutical market.

REFERENCE

1. Indian Journal of Natural products and Resources, Vol.2, June 2011: 204-210.
2. Santhosh K S, Geeta W. Assessment of glycemic potential of *Musa paradisiaca* stem juice. Indian Journal of Clinical Biochemistry, 2007; 222: 48-52.
3. Debaandya M, Namrata S. Banana and its by-product utilization: An overview, Journal of Scientific and Industrial Research, 2010: 323-329.
4. Text book of Pharmacognosy, 2nd edition, Mohammed Ali: 139- 140.
5. Moro FD, Bassi P, Mancini M. Cellular and molecular gateways to urolithiasis. International Journal of Urology, 2005; 74: 193-7.
6. Begun FP, Lawson RK. Chronic effects of focused electro hydraulic shock waves on renal function and hypertension. International Journal of Urology, 1991; 145: 635-9.
7. Moe OW. Kidney stones: Pathophysiology and medical management. Lancet, 2006; 367: 333-44.
8. Christina AJ, Kurian S. Modulatory effect of *Cycla peltata* Lam on stone formation induced by ethylene glycol treatment in rats. Experimental Clinical Pharmacology, 2002; 24: 77-9.
9. Comprehensive Practical and Viva in Biochemistry; Aravind S Yadav, Sharda R Deshmukh, Pramod S Kambel: 20- 29.
10. Bahuguna Y, Rawat MM. Antilithiatic effect of flower *Jasmin auriculatum* Vahl. International Journal of Green Pharmacy; 3: 155-63.
11. Atef M, Attar A. Antilithiatic influence of spirulina on ethylene glycol-induced nephrolithiasis in male rats. American Journal of Biochemistry and Biotechnology, 2010; 6: 25-6.
12. Park S, Pearle MS. Pathophysiology and management of calcium stones. Urology and Clinical aspect of North America, 2007; 34: 323-34.
13. Hajzadeh MA. Effect of thymoquinone on ethylene glycol-induced kidney in rats. Bangladesh Journal of Urology, 2008; 5: 149-54.
14. Marzieh Ahmadi, Nafiseh ST. *Alcea rosea* root extract in ethylene glycol-induced urolithiasis in rats. Indian Journal of Pharmacology, 2012; 304-307.
15. Grieve M, Plantain fruit, Botanical website 1996
16. Mukharjee T, Bhalla N, Jain H C, Herbal drugs for Urinary stones, Indian Drugs, 1984; 224- 228.
17. Prasad K V, Bharathi K, Srinivasan K K, Evaluation of *Musa paradisiaca* stem juice for antilithiatic activity in albino rats, Indian Journal of Physical pharmacology, 1993; 337.
18. Kulkarni S K, Hand book of experimental Pharmacology, 2nd edition, 1993: 78- 81.
19. Aulton ME, Pharmaceutics: The science of dosage form design, 2nd edition, Harcourt Publishers Limited, 2002; 15-32.
20. Tripathi KD, Essentials of Medical Pharmacology; 6th ed.; Jaypee Brothers Private Ltd, 2008; 184-188.