

NEUROPROTECTIVE POTENTIAL OF AZADIRACHTA INDICA LEAVES IN DIABETIC RATSNAVEEN KUMAR GUPTA^{1,2}, NIDHI SRIVASTVA^{2*}, SANJEEV PURI¹, PARVESH BUBBER³, VEENA PURI⁴¹Department of Biotechnology, University Institute of Engineering and Technology, Panjab University, Chandigarh, Punjab, India.²Department of Biotechnology, Banasthali University, Banasthali, Rajasthan, India. ³Department of Biochemistry, Indra Gandhi National Open University, New Delhi, India. ⁴Department of System Biology, Panjab University, Chandigarh, Punjab, India.

Email: mrs.nidhibu@gmail.com

Received: 16 December 2016, Revised and Accepted: 25 January 2017

ABSTRACT

Objective: *Azadirachta indica* is a treasure of multiple pharmacological properties and presently leaves of this plant have been explored to evaluate the neuroprotective potential in diabetic rats.

Methods: Male Sprague-Dawley rats were injected with single intra peritoneal dose of streptozotocin (STZ) (60 mg/kg body weight [BW]) to develop animal model of diabetes. Post 21 days of STZ induction, animals were treated with aqueous *A. indica* leaf extract (ALE, 600 mg/kg BW) for seven consecutive days. Followed this, all animals were evaluated for the levels of blood glucose, lipid peroxidation (LPO), C-reactive proteins (CRP), pro-oxidant biomarkers and histological changes.

Results: STZ treated rats exhibited elevated levels of blood glucose, LPO, CRP, and altered pro-oxidant biomarkers in comparison to control rats. Besides this, histological alterations/damage was evidenced as fragmentation, vacuolization, inflammation, etc. However, ALE treatment to these rats significantly decreased blood glucose levels, LPO, CRP levels, and restored pro-oxidants status. Light microscopic and ultramicroscopic analysis also indicated less damage, tissue architectural changes in comparison to untreated diabetic rats. Further, decrease in hyperalgesia and inflammation levels along with protective and restorative changes following ALE treatment suggested the neuroprotective potential of *A. indica* leaves in diabetic rats.

Conclusion: The oral administration of ALE to STZ induced diabetic animals resulted in neuroprotection against degenerative oxidative stress associated with metabolic and histopathological damage in the brain.

Keywords: *Azadirachta indica*, Antioxidants, Hyperalgesia, Neuroprotection.

© 2017 The Authors. Published by Innovare Academic Sciences Pvt Ltd. This is an open access article under the CC BY license (<http://creativecommons.org/licenses/by/4.0/>) DOI: <http://dx.doi.org/10.22159/ajpcr.2017.v10i4.16657>

INTRODUCTION

Diabetic neuropathy has become a major concern during the past few years, as it is the most common and troublesome form of complication leading to higher hospitalization rate if compared to other diabetic complications [1]. Approximately, 50-60% of patients with long-standing diabetes have been documented to develop chronic or acute neurological complications [2-4]. Hyperglycemia is the major driving force that leads to functional as well as structural damage to a variety of organs including nervous system. Various metabolic pathways are associated with the development and progression of diabetic neuropathy and neurodegeneration [5]. Thus, alternations in the metabolic pathways may result in damaged mitochondria leading to increased production of reactive oxygen species and impaired antioxidant associated immunity [3,6-8]. Pathological changes such as vascular alterations, disturbed synaptic plasticity, and alteration in neurotransmission have been reported in diabetic neuropathy [6,9]. Besides this, other neuropathological changes including damage to neurons, Schwann cells, axons and inflammation have also been reported in several diabetic cases [10]. Thus, poor control or uncontrolled hyperglycemia is an important factor responsible for the late-stage neural complications and inflammation in the brain which further increase the levels of inflammatory markers such as C-reactive proteins (CRP) in the tissue as well in the blood [11].

The current treatment methods of diabetes include chemical drugs and insulin injections; most of the treatment methods are not user-friendly and sometime associated with side effects. For instance, the invasive process of insulin injections exposes the patients to

high risk of premature atherosclerosis, hypoglycemic episodes, lipodystrophy [12]. Sulfonylureas and lidocaine may be effective in ameliorating neuropathic pain, but they have reported debilitating side effects [9]. On the other hand, plants and their extracts are easily available, efficacious, cost-effective, and considered less toxic. World Health Organization has also recommended the usage of herbal drugs for treating various diseases in developing countries [13].

Azadirachta indica (neem) is very important among the herbal medicinal treasure due to its long list of associated medicinal properties [6,14]. All parts of *A. indica* are used in the treatment of various diseases such as malaria fever, tooth decay, ulcers, liver infections, diarrhea, and diabetes. [14,15]. It is widely used in soaps, detergents, and pest control management systems [16]. The hydroalcoholic extracts, aqueous extracts, crude ethanol extracts, and petroleum ether extract of *A. indica* have been reported to have blood glucose lowering effect in several animal models including diabetic rats, dogs, rabbits, and mice [6,12]. Thus, based on this knowledge and considering the pharmacological properties of *A. indica*, the leaves of this plant are used in this study to evaluate the antioxidative and tissue protective potential in streptozotocin (STZ) induced diabetic rats.

METHODS**Chemicals**

All the chemicals used in the study were of analytical grade. STZ was procured from Hi Media (Mumbai, India). Glutathione reductase (GRx), purchased from Sigma (St. Louis MO, USA). CRP, ELISA kit (Affymetrix eBiosciences, Santa Clara, CA, USA).

Preparation of aqueous *A. indica* leaf extracts (ALE) and dose selection

The leaves of *A. indica* were collected from botanical garden of Panjab University (PU), Chandigarh, and duly certified by National Institute of Science Communication and Information Resources, New Delhi, India. The aqueous extract was prepared according to the method of Hussein [17], by taking fresh leaves of *A. indica* (200 g) and grinded in 1 L of double distilled water, and suspension was filtered through Whatman filter paper no 1. The filtrate was lyophilized to obtain powder extract. Everyday required quantity of powder extract was dissolved in distilled water to prepare a fresh dose of ALE (600 mg/kg body weight [BW]) and dose was selected on the basis of our previously published study [18].

Animal models of diabetes

Healthy male Sprague-Dawley rats weighing 160 ± 10 g were obtained from Central Animal House PU, Chandigarh, and housed in the polypropylene cages at ambient temperature with 12 hrs dark and 12 hrs light cycle. Animals were fed on standard pellet diet with free access to water. All procedures and treatment were duly approved by the Animal Ethics Committee (CPCSEA) of P. U. Chandigarh (IAEC/346-356 dated 11.2.2013).

After 1 week of acclimatization to laboratory conditions, animals were randomly divided into three groups, Group 1 - Control, Group 2 - Diabetic, and Group 3 - Diabetic treated with ALE (D+ALE). Each group had six animals. Animals of Group 2 and Group 3 were induced diabetes by a single intraperitoneal injection of STZ (60 mg/kg BW.) prepared in saline solution [19]. Post STZ induction (72 hrs), diabetes was established (fasting blood glucose level ≥ 250 mg/dl) in Group 2 and Group 3 animals.

All animal groups were kept under observation for 21 days following STZ treatment. After this, animals of Group 3 were treated with an oral dose of ALE (600 mg/kg BW. volume 0.5 ml), while the animals in Group 1 and Group 2 received the same volume of distilled water once in a day for next 7 days. After 28 days, all animals were sacrificed under mild ether anesthesia, brain tissues were isolated, and blood was collected in clean test tubes. The brain tissues were homogenized (10% w/v) in 0.1 M Tris HCl buffer (pH 7.4) to prepare post-mitochondrial supernatant (PMS), and blood was centrifuged to prepare plasma.

Antioxidant profile

Antioxidants analysis was performed in PMS using standard methods. The activity of catalase CAT was measured using the method of Luck [20]. The activity GRx was assayed by the method of Carlberg and Mannervik [21]. The activity of glutathione peroxidase (GPx) was measured by the method of Flohé and Gunzler [22]. Superoxide dismutase (SOD) activity was determined by the method of Kono [23]. Reduced glutathione (GSH) was measured by the method of Ellman [24] and lipid peroxidation (LPO) by the method of Wills [25]. Protein content was estimated by the method of Lowry *et al.* [26]. Blood glucose levels were estimated using Glucometer, Abbott Labs Ltd. The optical density of all biochemical estimations was read on Shimadzu ultraviolet-visible spectrophotometer 1240.

Histological analysis

The study was conducted using light microscopic (LM) and transmission electron microscopic examination (TEM). For LM brain (cerebral cortex) was fixed in formalin saline and washed with distilled water. Then, tissues were processed through different percentages of alcohol and cleared through xylene treatment. Finally, thin sections of 5-6 μ m were cut and stained with hematoxylin and eosin stain and viewed under light microscope. However, for TEM very thin sections of the brain (cerebral cortex) were cut and fixed in Karnovsky fixative (Glutaraldehyde based fixative). Dehydration and clearing steps were performed with acetone and toluene, respectively. Sections were embedded using liquid Araldite and ultrathin sections (60-80 nm) were cut with special microtome

followed by staining and viewed under TEM (Morgagni 268D) at AIIMS, New Delhi.

Estimation of CRP

The levels of CRP in blood plasma were estimated using commercially available ELISA kit.

Behavior studies

The behavior studies were conducted to evaluate the pain perception and hyperalgesia using hot plate test and tail immersion test. Hot plate test was performed according to the method of Woolfe and MacDonald [27] while tail immersion test was performed according to the method of Ben-Bassat [28].

Statistical analysis

All observations including nonceptive thresholds were expressed as mean \pm standard error of mean for six animals and variation in the data was analyzed using one-way analysis of variance followed by LSD post-hoc test using SPSS software version 16.0. The $p \leq 0.05$ was considered statistically significant.

RESULTS

Blood glucose and BW

STZ is a routinely used diabetogen to induce diabetes in animals. In this study, Group 2 and Group 3 animals developed hyperglycemia (≥ 250 mg/dl) on the 3rd day of STZ injection. The blood glucose levels in these animals were found to be significantly high ($p \leq 0.001$) in comparison to control animals. However, the oral administration of ALE significantly reduced blood glucose levels ($\sim 55\%$) in Group 3 animals (Fig. 1), as compared to Group 2 animals. On the other hand, STZ treated animals reflected a significant reduction ($p \leq 0.001$) in their BWs, i.e., both Group 2 and Group 3 animals. However, in Group 2 animals the decrease in BW remained continues till the end of experimental period (28th day), while in Group 3 animals the decrease in BW was prevented with ALE treatment (Fig. 2). In totality, the Group 2 animals reduced ~ 9 g of their BW while the Group 3 animals reduced ~ 2.2 g of their BWs during the 7 days treatment period (21st to 28th day).

Antioxidants profile

The STZ treated rats showed significant changes in their antioxidant parameters in comparison to control animals. Fig. 3 illustrates the antioxidant profile in diabetic rats, where the LPO levels were found to be increased by $\sim 65\%$, and GSH levels decreased by $\sim 25.4\%$ in comparison to control rats. However, on ALE treatments to diabetic rats, the levels of LPO were found to be decreased by $\sim 31\%$, and levels of GSH increased by $\sim 18.5\%$ in comparison to untreated diabetic rats (Group 2 animals). Thus, ALE treatment significantly decreased LPO ($p \leq 0.001$) and improved GSH levels ($p \leq 0.001$) in Group 3 animals. The change in the activities of various antioxidant enzymes CAT, SOD, GPx, and GRx illustrated in Fig. 3. Diabetic rats exhibited a significant

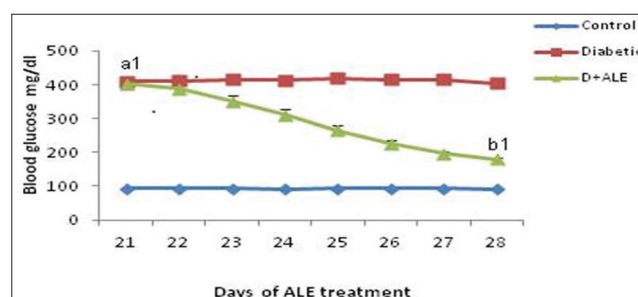


Fig. 1: Blood glucose profile during *Azadirachta indica* leaf extract (ALE) treatment. D+ALE: Diabetes treated with *A. indica* leaf extract. All the values are expressed as mean \pm SEM, n=6. Statistically significant difference from control ^{a1} $p \leq 0.001$. Statistically significant difference from diabetic ^{b1} $p \leq 0.001$

increase in the activities of CAT, SOD, and GPx as ~191.8%, ~127.7%, and ~36.7%, respectively, while the activity of GRx was found to be decreased by ~28% in comparison to controls. The ALE treatment to Group 3 animals restored these enzymes activities toward control levels as ~33.2%, ~51.3%, ~27.1%, and ~25%, respectively, for CAT, SOD, GPx, and GRx enzymes. Thus, the ALE treatment improved the antioxidant profile in Group 3 animals.

Histological analysis

Fig. 4 represents the results of LM examination (Fig. 4a-c) and TEM (Fig. 4d-f) analysis of control, diabetic, and D+ALE brains,

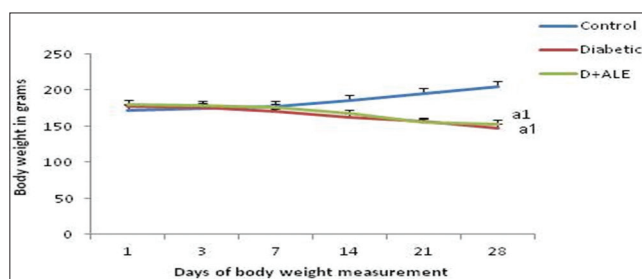


Fig. 2: Change in body weight during diabetes and *Azadirachta indica* leaf extract (ALE) treatment. D+ALE: Diabetic treated with *A. indica* leaf extract. All the values are expressed as mean±standard error of mean, n=6. Statistically significant difference from control ^{a1}p≤0.001

respectively (cerebral cortex). The control brain showed (Fig. 4a) normocytic neurons, few blood vessels, normal neuronal density, and compact arrangement of tissue. Morphologically most of the neurons appeared round or oval in shape. Similarly, at ultrastructural level, the tissue architecture in control animals (Fig. 4d) was found to be well maintained, without any morphological changes in mitochondrial structure and other organelles. However, the section taken from diabetic brain (Fig. 4b) revealed degenerative changes (red arrows), necrotic cells that indicated necrosis. Besides this, vacuolization, fragmentation, and alteration in the morphology of some of the neurons were also observed. The ultrastructural analysis of such untreated diabetic brains (Fig. 4e) reflected swollen or deformed mitochondria and appearance of myelination was also recorded. The analysis of the sections taken from D+ALE treated rats showed improvement in the morphology of neurons and tissue compactness. The ALE treated rats also revealed decrease in the necrotic cells and fragmentation in comparison to untreated diabetic rats. Further vacuolization around the neurons was found to be decreased. The ultrastructural analysis (Fig. 4f) demonstrated considerably decreased in the mitochondrial swelling and inflammation. The overall structural integrity was found to be improved in D+ALE animals in comparison to untreated diabetic animals.

Inflammatory markers

Fig. 5 represents the analysis of CRP in all the three groups of animals. The diabetic animals showed significantly (p≤0.001) elevated levels of CRP (~97%) with respect to control animals. The ALE treatment to diabetic rats significantly reduced (p≤0.001) these elevated levels and brought them toward control levels.

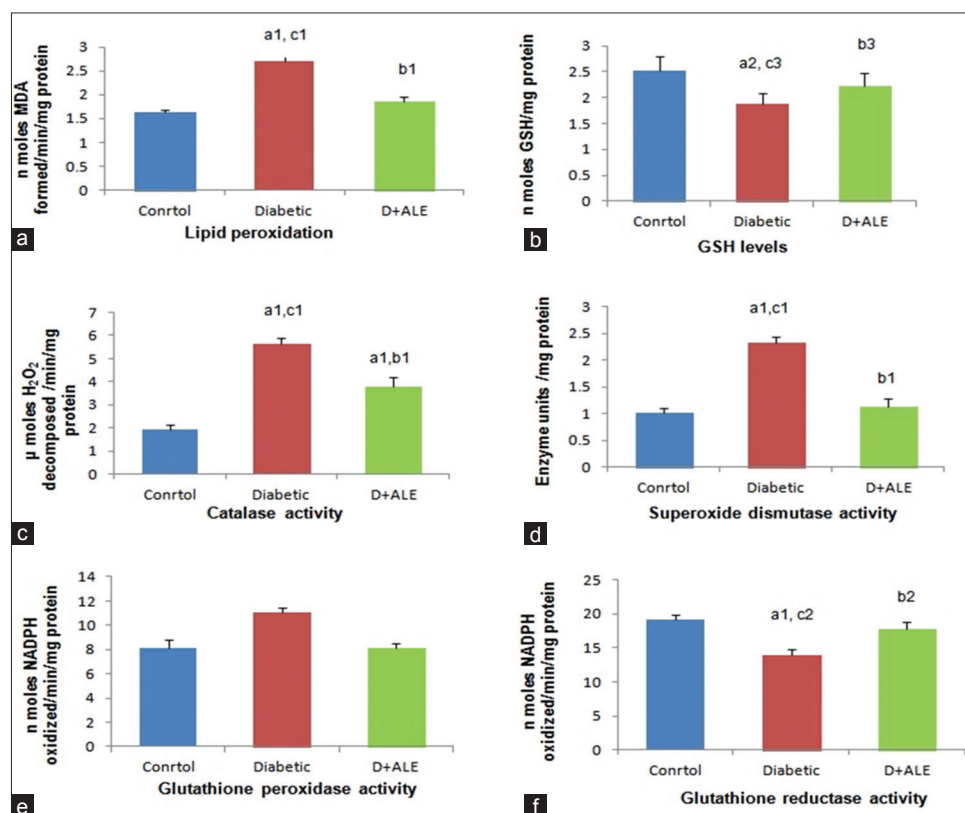


Fig. 3: Evaluation of antioxidant profile in the brain tissue of three groups of animals. (a) lipid peroxidation levels expressed as nmoles malondialdehyde formed/min/mg protein (b) glutathione (GSH) levels expressed as nmoles/mg protein (c) catalase activity expressed as μmoles hydrogen peroxide H₂O₂ decomposed/min/mg protein (d) superoxide dismutase activity expressed as enzyme units/mg protein where one unit of enzyme is the amount of enzyme inhibiting the rate of reaction (nitro blue tetrazolium reduction) by 50%. (e) Glutathione peroxidase activity expressed as nmoles nicotinamide adenine dinucleotide phosphate (NADPH) oxidized/min/mg protein (f) glutathione reductase activity expressed as nmoles NADPH oxidized/min/mg protein. D+ALE: Diabetes treated with *Azadirachta indica* leaf extract. GSH reduced. All the values are expressed as mean±standard error of mean, n=6. Statistically significant difference from control ^{a1}p≤0.001, ^{a2}p≤0.01. The statistically significantly difference from diabetic ^{b1}p≤0.001, ^{b2}p≤0.01, ^{b3}p≤0.05. Statistically significantly difference from D+ALE ^{c1}p≤0.001, ^{c2}p≤0.01, ^{c3}p≤0.05

Behavior analysis

Hyperalgesia was evaluated by performing tail immersion and hot plate tests. Fig. 6a demonstrates the results of hot plate test, where diabetic rats were observed to have ~61% lower pain threshold, i.e., low reaction time as compared to control rats. However, ALE treatment to diabetic rats improved pain threshold and observed to have ~33% with respect to control animals. Thus, a significant decrease in the pain threshold was observed in diabetic rats ($p \leq 0.001$) and ALE treatment reversed the same significantly ($p \leq 0.001$) toward control levels.

Similarly, Fig. 6b demonstrates the analysis of thermal hyperalgesia through tail immersion test where diabetic rats were observed to have ~58% decrease in pain threshold (reaction time increased) as compared to control rats. However, after ALE treatment, the pain threshold was observed to have decreased ~27.08% with respect to controls. Thus, the oral administration of ALE to diabetic rats significantly improved reaction time ($p \leq 0.001$) in comparison to untreated diabetic rats.

DISCUSSION

Diabetic neuropathy is the most perilous complication associated with sensory neurons, motor neurons, and structural alterations in the nervous tissue [1]. STZ induced diabetic models are the most accepted animal models of diabetic neuropathy owing to their reproducibility and irreversible diabetes [29,30]. The mechanism of STZ action involved alkylation and fragmentation of beta cells DNA. Similar results were observed in this study with the development of hyperglycemia post 3 days of STZ induction in Group 2 animals. Besides this, the parallel reduction in the BWs of diabetic animals was also observed, which could be due to the over breakdown of stored glycogen and fat under the increased metabolic demand, during hyperglycemic state [31]. However, on ALE treatment, the Group 3 animals showed a remarkable reduction in their blood glucose levels and partially prevented weight loss. According to the previous reports, ALE is a concoction of many polyphenols and antioxidants compounds [12,32,33]. Most of these compounds are associated with the peripheral utilization of glucose, which might have resulted in lowering of blood glucose levels in Group 3 animals. Further, the blood glucose lowering effect of ALE may have inhibited the degradation of structural proteins which in turn prevented the weight loss in D+ALE animals [34,35].

Hyperglycemia affects the pro-oxidant state of the tissue. Oxidative stress and neuroinflammation combined with decline in antioxidative defense potential have been documented as the key pathophysiological mechanism, involved in various complications including diabetic neuropathy [3,7,36]. In this study, the activities of various antioxidant enzymes, viz., CAT, SOD, GRx, and GPx had been found to be modulated in diabetic animals. The hyper activities of CAT and SOD could be a response of overproduction of H_2O_2 and free radicals in the diabetic brain. The significant difference in the activities of various biomarkers in diabetic versus control animals indicated the augmented oxidative stress and tissue response during diabetes. Moreover, nervous tissue is considered to be rich in polyunsaturated fatty acids mainly arachidonic acid and docosahexaenoic acids which are highly sensitive to LPO and depleted antioxidant status [3,37]. The diabetic animals exhibited the similar biochemical imbalance in terms of increased LPO levels and decreased GSH levels. Hence, these levels revealed the magnitude of oxidative stress and extent of structural and functional damage to the nervous system.

During oxidative stress, many reactive molecules crosstalk and augment the delirious effect by causing alterations in the tissue architecture. However, the effect of LPO has widely been reported in the neural degeneration in various diseases including Alzheimer's disease, Parkinson's disease, Huntington's disease, amyotrophic lateral sclerosis, and Down syndrome [38]. In this study, LM and ultrastructural analysis reported significant changes in the tissue architectural and compactness indicated deteriorated condition of nervous tissue during hyperglycemia. Further decrease in neuronal

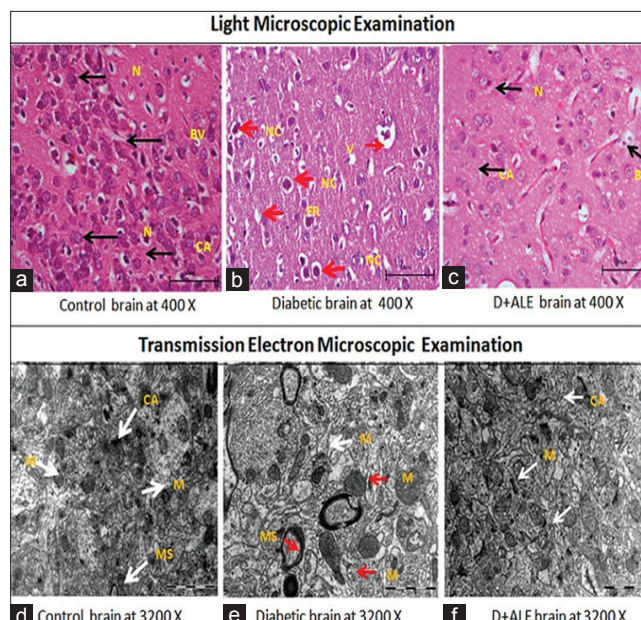


Fig. 4: Histological analysis of brain. Sections a-c represent light microscopic examination, and section d-f represent transmission electron microscopy examination. D+ALE: Diabetic rats treated with *Azadirachta indica* leaf extract, M: Mitochondria, MS: Myelin sheath, BV: Blood vessels, CA: Compact arrangement, Fr: Fragmentation, N: Neuron, NC: Necrotic cells. Black and white arrows: Normal structures, Red arrows: Abnormal structures

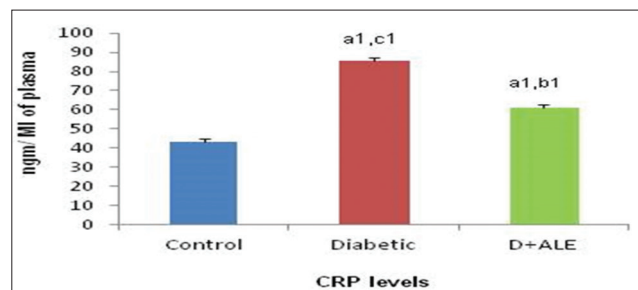


Fig. 5: Analysis of C-reactive proteins levels. Concentration expressed as ng/ml of plasma. D+ALE: Diabetes treated with *Azadirachta indica* leaf extract. All the values are expressed as mean \pm standard error of mean, n=6. Statistically significant difference from control ^{a1} $p \leq 0.001$, ^{a2} $p \leq 0.01$, ^{a3} $p \leq 0.05$. Statistically significant difference from diabetic ^{b1} $p \leq 0.001$. Statistically significant difference from D+ALE ^{c1} $p \leq 0.001$.

density, neuromorphological changes and axonal sheath changes indicated neuronal injury and brain damage in diabetic animals. The observation of swelling of mitochondria or deformed mitochondria in diabetic brain substantiated the findings of light microscopy and pointed out the critical role of this organelle in diabetes. In addition, less availability of GSH and elevated levels of LPO in the diabetic state might have also caused the structural damage and developed neuronal alterations [39]. However, decreased levels of LPO and increased levels of GSH with ALE treatment improved the tissue architecture and reduced the neuropathological complication in Group 3 animals indicated a protective role of ALE.

Further, the observation of inflammation in diabetic brain suggested the neuronal injury and development of neuropathy. Kuhard *et al.* reported the inflammation in brain tissue of STZ treated animals [40]. Earlier inflammation was thought to be a part of Type II diabetes, but recently

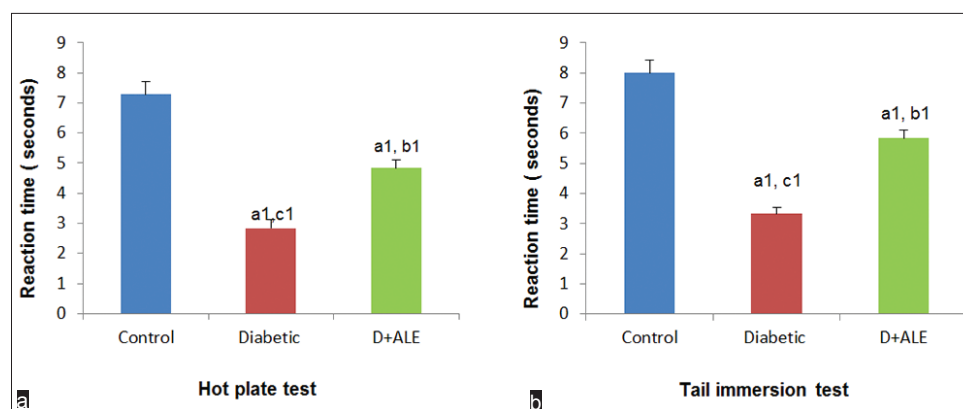


Fig. 6: Evaluation of hyperalgesia in three groups of animals. (a) Hot plate test expressed as response/struggle time in seconds, (b) tail immersion test expressed as response/struggle time in seconds. D+ALE: Diabetic treated with *Azadirachta indica* leaf extract. All the values are expressed as mean±standard error of mean, n=6. Statistically significant difference from control ^{a1}p≤0.001. Statistically significant difference from diabetic ^{b1}p≤0.001. Statistically significant difference from D+ALE ^{c1}p≤0.001

inflammation has been considered as an important component of Type I diabetes and included as parameters in diabetes diagnosis [41,42]. CRP is another important marker of acute phase inflammation and well reported in diabetic patients as well as in diabetic animals [43,44]. The observation of elevated levels of CRP in diabetic animals confirmed the inflammation in the brain tissue and corroborated the histopathological findings. However, *A. indica* is considered as a rich source of natural products, viz., azadirachtin, nimbin, quercetin, gallic acid catechin, epicatechin and salannin [45] and most of these natural products have been reported to be useful in reducing inflammation [46,47]. Hence, the natural antioxidants of ALE might have reduced the inflammation and reversed the CRP levels in Group 3 animals.

Neuropathic pain or hyperalgesia is a manifestation of diabetic neuropathy [48]. Several studies have reported oversensitivity (feeling of excessive pain) in diabetic patients and animals [49-51]. Presently, diabetic animals exhibited decrease in threshold for pain perception and reported hyperalgesia. Hyperalgesia develops mainly due to local metabolic and microvascular changes in the nervous tissue [48]. The involvement of superoxide, peroxynitrite and hydroxyl radicals has already been well established in various animal models of hyperalgesia [52]. Besides this, the role of cytokines and inflammatory markers cannot be ignored in neuropathic pain and diabetic complications [53,54]. The results of this study also revealed metabolic changes and variation in the antioxidant profile of diabetic animals. Thus, alterations in the biochemical parameters seem to be akin with the microangiopathic effects which suggested the development of hyperalgesia in diabetic animals. However, the ALE treatment decreased neuronal inflammation, LPO, increased GSH content; suggested reduction in neuronal stress levels hence attenuated the hyperalgesia.

Thus in totality, this study suggests the oral administration of ALE to STZ induced diabetic animals resulted in neuroprotection against degenerative oxidative stress associated with metabolic and histopathological changes.

ACKNOWLEDGMENT

The authors are grateful to the Department of UIET and Banasthali University for providing infrastructure and facilities to carry out this research.

REFERENCES

1. Yadav SK, Nagori BP, Desai PK. Pharmacological characterization of different fractions of *Calotropis procera* (Asclepiadaceae) in streptozotocin induced experimental model of diabetic neuropathy.

- J Ethnopharmacol 2014;152(2):349-57.
- Deli G, Bosnyak E, Pusch G, Komoly S, Feher G. Diabetic neuropathies: Diagnosis and management. *Neuroendocrinology* 2014;98(4):267-80.
 - Gupta A, Gupta Y. Diabetic neuropathy: Part. *J Pak Med Assoc* 2014;64:714-21.
 - Pandhare RB, Sangameswaran B, Mohite PB, Khanage SG. Attenuating effect of seeds of *Adenanthera pavonina* aqueous extract in neuropathic pain in streptozotocin-induced diabetic rats: An evidence of neuroprotective effects. *Rev Bras Farmacogn* 2012;22(2):428-35.
 - Prabhakar PK. Pathophysiology of secondary complications of diabetes mellitus. *Asian J Pharm Clin Res* 2016;9(1):32-6.
 - Pandey RK, Singh SN, Shah Nawaz K. Comparative study of aegle marmelos, *Azadirachta indica* and glimepiride on blood sugar in experimentally induced hyperglycemia in albino rats. *J Evol Med Dent Sci* 2015;4:3815-22.
 - Yang H, Fan S, Song D, Wang Z, Ma S, Li S, et al. Long-term streptozotocin-induced diabetes in rats leads to severe damage of brain blood vessels and neurons via enhanced oxidative stress. *Mol Med Rep* 2013;7(2):431-40.
 - Vojtková J, Čiljaková M, Bánovčín P. Diabetic microangiopathy etiopathogenesis, new possibilities in diagnostics and management in Microangiopathy. In: *Microangiopathy*. 1st ed. Europe, Rijeka, Croatia: In Tech; 2012. p. 37-66.
 - Hama AT, Plum AW, Sagen J. Antinociceptive effect of ambroxol in rats with neuropathic spinal cord injury pain. *Pharmacol Biochem Behav* 2010;97(1):249-55.
 - Zenker J, Ziegler D, Chrast R. Novel pathogenic pathways in diabetic neuropathy. *Trends Neurosci* 2013;36(8):439-49.
 - Dong Q, Wright JR. Expression of C-reactive protein by alveolar macrophages. *J Immunol* 1996;156(12):4815-20.
 - Sreenivasan V, Kandasamy CS, Kumar MG, Prabhu KG, Arulraj P, Johnson JS, et al. Review on different natural herbals associated with the anti-diabetic activity. *World J Pharm Pharmsci* 2015;4(8):581-95.
 - World Health Organization. WHO traditional medicine strategy 2002-2005 glucose metabolism to neurodegeneration. *J Diabetes Res* 2003;4:303-12.
 - Nduka SO, Daniel AL, Ilodigwe EE, Adimorah U, Mbagwu SI. Pharmacodynamic herb-drug interactions: The effects of *Azadirachta indica* leaf extracts on two commonly used second generation sulfonylureas. *World J Pharm Pharm Sci* 2015;4(7):1702-11.
 - Raphael E. Phytochemical constituents of some leaves extract of *Aloe vera* and *Azadirachta indica* plant species. *Glob Adv Res J Environ Sci Toxicol* 2012;1(2):14-7.
 - Pandey G, Verma KK, Singh M. Evaluation of phytochemical, antibacterial and free radical scavenging properties of *Azadirachta indica* (neem) leaves. *Int J Pharm Pharm Sci* 2014;6(2):444-7.
 - Hussein HE. Reversal of diabetic retinopathy in streptozotocin induced diabetic rats using traditional Indian anti-diabetic plant, *Azadirachta indica* (L.). *Indian J Clin Biochem* 2002;17(2):115-23.
 - Gupta NK, Srivastva N, Bubber P, Puri S. The Antioxidant potential of *Azadirachta indica* ameliorates cardioprotection following diabetic mellitus induced microangiopathy. *Pharmacogn Mag* 2016;12(3):371-8.

19. Verma VK, Sarwa KK, Zaman KM. Antihyperglycemic activity of *Swertia chirayita* and *Andrographis paniculata* plant extracts in streptozotocin induced diabetic rats. *Int J Pharm Pharm Sci* 2013;5(3):305-11.
20. Luck H. Catalase. In: Bergmeyer HU, editor. *Methods of Enzymatic Analysis*. 2nd ed. Weinheim, New York: Verlag Chemie and Academic Press; 1963. p. 885-8.
21. Carlberg IN, Mannervik BE. Purification and characterization of the flavoenzyme glutathione reductase from rat liver. *J Biol Chem* 1975;250(14):5475-80.
22. Flohé L, Günzler WA. Assays of glutathione peroxidase. *Methods Enzymol* 1984;105:114-21.
23. Kono Y. Generation of superoxide radical during autoxidation of hydroxylamine and an assay for superoxide dismutase. *Arch Biochem Biophys* 1978;186(1):189-95.
24. Ellman GL. Tissue sulfhydryl groups. *Arch Biochem Biophys* 1959;82(1):70-7.
25. Wills ED. Mechanisms of lipid peroxide formation in animal tissues. *Biochem J* 1966;99(3):667-76.
26. Lowry OH, Rosebrough NJ, Farr AL, Randall RJ. Protein measurement with the Folin phenol reagent. *J Biol Chem* 1951;193(1):265-75.
27. Woolfe G, MacDonald AD. The evaluation of the analgesic action of pethidine hydrochloride (demerol). *J Pharmacol Exp Ther* 1944;80(3):300-7.
28. Ben-Bassat J, Peretz E, Sulman FG. Analgesimetry and ranking of analgesic drugs by the receptacle method. *Arch Int Pharmacodyn Ther* 1959;122:434-47.
29. Sima AA, Zhang WX, Tze WJ, Tai J, Nathaniel V. Diabetic neuropathy in STZ-induced diabetic rat and effect of allogeneic islet cell transplantation: Morphometric analysis. *Diabetes* 1988;37(8):1129-36.
30. Hussein JI, El-Matty D, El-Khayat ZA, Abdel-Latif YA. Brain neurotransmitters in diabetic rats treated with CO enzyme Q10. *Int J Pharm Pharm Sci* 2012;4:554-6.
31. Inzucchi SE, Sherwin RS. Type 1 diabetes mellitus. *Cecil Medicine*. 24th ed. Philadelphia, PA: Saunders, Elsevier; 2011. p. 78-81.
32. Chattopadhyay RR. Possible mechanism of antihyperglycemic effect of *Azadirachta indica* leaf extract. Part IV. *Gen Pharmacol* 1996;27(3):431-4.
33. Gupta R, Bajpai KG, Johri S, Saxena AM. An overview of Indian novel traditional medicinal plants with antidiabetic potentials. *Afr J Trad Complement Altern Med* 2008;5(1):1-17.
34. Chatterjee MN, Shinde R. *Textbook of Medical Biochemistry*. 8th ed. New Delhi: Jaypee Brothers Medical Publishers; 2011. p. 380-5.
35. Roy S, Mondru AK, Dontamalla SK, Vaddepalli RP, Sannigrahi S, Veerareddy PR. Methoxy VO-salen stimulates pancreatic β cell survival by upregulation of eNOS and downregulation of apoptosis in STZ-induced diabetic rats. *Biol Trace Elem Res* 2011;144(1-3):1095-11.
36. Sandireddy R, Yerra VG, Areti A, Komirishetty P, Kumar A. Neuroinflammation and oxidative stress in diabetic neuropathy: Futuristic strategies based on these targets. *Int J Endocrinol* 2014;2014:1-10.
37. Hashmat I, Azad H, Ahmed A. Neem (*Azadirachta indica* A. Juss) - A nature's drugstore: An overview. *Int Res J Biol Sci* 2012;1(1):76-9.
38. Reed TT. Lipid peroxidation and neurodegenerative disease. *Free Radic Biol Med* 2011;51(7):1302-19.
39. Hassler SN, Johnson KM, Hulsebosch CE. Reactive oxygen species and lipid peroxidation inhibitors reduce mechanical sensitivity in a chronic neuropathic pain model of spinal cord injury in rats. *J Neurochem* 2014;131(4):413-7.
40. Kuhad A, Chopra K. Tocotrienol attenuates oxidative-nitrosative stress and inflammatory cascade in experimental model of diabetic neuropathy. *Neuropharmacology* 2009;57(4):456-62.
41. Eizirik DL, Colli ML, Ortis F. The role of inflammation in insulinitis and β -cell loss in Type 1 diabetes. *Nat Rev Endocrinol* 2009;5(4):219-26.
42. Spranger J, Kroke A, Möhlig M, Hoffmann K, Bergmann MM, Ristow M, et al. Inflammatory cytokines and the risk to develop Type 2 diabetes results of the prospective population-based European Prospective Investigation into Cancer and Nutrition (EPIC)-Potsdam Study. *Diabetes* 2003;52(3):812-7.
43. Dandona P, Aljada A, Bandyopadhyay A. Inflammation: The link between insulin resistance, obesity and diabetes. *Trends Immunol* 2004;25(1):4-7.
44. Mahmoud MF, Hassan NA, El Bassossy HM, Fahmy A. Quercetin protects against diabetes-induced exaggerated vasoconstriction in rats: Effect on low grade inflammation. *PloS One* 2013;8(5):e63784.
45. Schumacher M, Cerella C, Reuter S, Dicato M, Diederich M. Anti-inflammatory, pro-apoptotic, and anti-proliferative effects of a methanolic neem (*Azadirachta indica*) leaf extract are mediated via modulation of the nuclear factor- κ B pathway. *Genes Nutr* 2011;6(2):149-60.
46. Bharati S, Rishi P, Koul A. *Azadirachta indica* exhibits chemopreventive action against hepatic cancer: Studies on associated histopathological and ultrastructural changes. *Microsc Res Tech* 2012;75(5):586-95.
47. Mishra J, Dash AK, Dash DK. Nature's drug store: The free tree of India. *World J Pharm Pharm Sci* 2013;2(6):4778-98.
48. Sharma S, Kulkarni SK, Agrewala JN, Chopra K. Curcumin attenuates thermal hyperalgesia in a diabetic mouse model of neuropathic pain. *Eur J Pharmacol* 2006;536(3):256-61.
49. Ohsawa M, Kamei J. Possible involvement of spinal protein kinase C in thermal allodynia and hyperalgesia in diabetic mice. *Eur J Pharmacol* 1999;372(3):221-8.
50. Lee-Kubli CA, Mixcoatl-Zecuatl T, Jolivald CG, Calcutt NA. Animal models of diabetes-induced neuropathic pain. *Behavioral Neurobiology of Chronic Pain*. Berlin, Heidelberg: Springer; 2014. p. 147-70.
51. Zychowska M, Rojewska E, Przewlocka B, Mika J. Mechanisms and pharmacology of diabetic neuropathy-experimental and clinical studies. *Pharmacol Rep* 2013;65(6):1601-10.
52. Janes K, Neumann WL, Salvemini D. Anti-superoxide and anti-peroxynitrite strategies in pain suppression. *Biochim Biophys Acta* 2012;1822(5):815-21.
53. Hidmark A, Fleming T, Vittas S, Mendler M, Deshpande D, Groener JB, et al. A new paradigm to understand and treat diabetic neuropathy. *Exp Clin Endocrinol Diabetes* 2014;122(4):201-7.
54. Skundric DS, Lisak RP. Role of neurotrophic cytokines in development and progression of diabetic polyneuropathy: From glucose metabolism to neurodegeneration. *J Diabesity Res* 2003;4(4):303-12.