

DIABETIC NEPHROPATHY AN OBVIOUS COMPLICATION IN LONG TERM TYPE 1 DIABETES MELLITUS: A CASE STUDYJAHIDUL ISLAM MOHAMMAD^{1*}, SRIDEVI CHIGURUPATI^{2*}, AZLI SHAHRIL OTHMAN¹,
MUHAMMAD ZAHID IQBAL³¹Department of Pharmacology, Faculty of Medicine, Cyberjaya University College of Medical Sciences, CUCMS, Cyberjaya, Malaysia.²Department of Pharmaceutical Chemistry, Faculty of Pharmacy, AIMST University, Semeling, Bedong, Kedah, Malaysia. ³Department of Clinical Pharmacy, Faculty of Pharmacy, AIMST University, Semeling, Bedong, Kedah, Malaysia.

Email: dr.jahid1980@gmail.com

Received: 14 June 2017, Revised and Accepted: 07 August 2017

ABSTRACT

Most overwhelming complications of Type 1 diabetes mellitus patients are responsible for complications related to the microvascular system most likely with kidney. In the kidney, hyperglycemia induced microangiopathy resulting not only thickening of the glomerular capillary basement membrane but also to the proliferation of the mesangial matrix and solidifying of the tubular basement membrane. Several biochemical and pathological, factors are concerned for the development of diabetic renal microangiopathy. These include the glomerular hyperperfusion and hyperfiltration, transformed morphology of podocytes accompanies these basement membrane modifications, Type IV collagen augmented synthesis following the hyperglycemia, and increased expression of tissue matrix metalloproteinase. The aim of this case review is to highlight the recent advances in understanding the pathogenesis, diagnosis, the overview and the potential renoprotective therapeutic agents that would prevent the development or the progression of diabetic nephropathy.

Keywords: Type 1 diabetes mellitus, Albuminuria, Diabetic nephropathy.© 2017 The Authors. Published by Innovare Academic Sciences Pvt Ltd. This is an open access article under the CC BY license (<http://creativecommons.org/licenses/by/4.0/>) DOI: <http://dx.doi.org/10.22159/ajpcr.2017.v10i11.20699>**INTRODUCTION**

Diabetic nephropathy (DN) signifies one of the utmost common microvascular problems of Type 1 diabetes mellitus (T1DM) with an increasing frequency worldwide [1]. Which is well-defined as the presence of trace albuminuria followed by a diminished glomerular filtration rate (GFR) [2]. This signifies the inability of kidneys to prevent urinary protein leakage characterizes a significant primary sign of renal impairment in patients with T1DM [3]. One-third of T1DM patient's progress to DN, on the other hand, this incidence is much lower with T1DM [4]. The most common complications of diabetes include macrovascular and microvascular events likewise-retinopathy induced blindness, heart attack, kidney failure, stroke, and leg amputation [5]. At present antidiabetic drugs are effective but implies very cost burden to the family. Moreover, a lot of cofactors such as patient devotion, education interrelated to diabetes, lifestyle modification, and associated comorbid diseases has an association with glycemic control [6]. The hall mark characteristics of DN is accompanied by numerous histological and functional anomalies, which includes loss of podocyte, thickening of glomerular basement membrane mesangial growth due to increased density of mesangial matrix and hypertrophy of mesangial cells (MCs) and hemodynamic changes in the initiation and progression of diabetic glomerulosclerosis, which resulting interruption and crumbling of the normal glomerular architecture which resulting microaneurysm formation [7]. American Diabetes Association characterized DN based on the extent of albuminuria and GFR. Renal hyperfunction and hypertrophy are categorized by the earliest stage (Stage 1) of DN. In the course of time and with the coexistence of risk factor such as uncontrolled hypertension, and persistent increase in urine albumin excretion (UAE) develops. This stage is called incipient nephropathy (Stage 3) characterized by GFR 30-59 ml/min/1.73 m², UAE>30 mg/day, >20 µg/min, or urine albumin to creatinine ratio (ACR) > 33 mg/g of creatinine. Stage 4 or overt nephropathy (renal failure) characterized as GFR shows a consistent decline (15-29 ml/min/1.73 m²) that becomes distinct with the continuous increase of UAE above

300 mg/day, 200 µg/min, or when urine ACR exceeds 300 mg/g. Stage 5 renal failure or end-stage renal disease signify constant increase of UAE above 300 mg/day and GFR below 15 ml/min/1.73 m² [8-10].**CASE REPORT**

A 37-year-old woman is brought to the emergency department of a hospital with the complaints of unintentional weight loss, confused mental status, and dyspnea since last night. According to the patient, she is a known case of T1DM since her age is 8. It was treated with insulin lispro since diagnosis. Her family transfers to a new place and started an irregular follow-up in the diabetic outpatient care unit. The patient noticed that recently she has lost 5 kg body weight without dieting and has been complaining of fatigue for 2 or 3 weeks. She appeared confused, forgetfulness, carelessness in dress and daily hygiene for the last 3 days. She also observed that her daughter is dyspneic during walking around the house, washing, dressing, and even during eating since last night. 6 months before the admission, the patient also noticed swelling of the face and legs which are associated with scanty micturition during daytime and frequently at night, which disturbs her sleep. For the last 1 month, she noticed gradual swelling of whole body and puffiness of the face, which is more marked after getting up from sleep in the morning. She is hypertensive for past 5 years but no history of allergy or bronchial asthma. She is under medication with insulin lispro and tablet losartan. Her parents are suffering from hypertension with dyslipidemia. However, they denied about diabetes or bronchial asthma. She was experiencing severe emotional trauma because of sudden loss of her 5 years old younger brother. There is no history of fever, abdominal pain, loin pain, itching, joint pain, skin rash, or hematuria.

On general examination, the patient is ill looking and pale, with puffy face and baggy eyelids, moderately anemic, pitting edema-present, she appears dehydrated with a dry tongue, loss of skin turgor, no clubbing, jaundice, cyanosis or koilonychia, no lymphadenopathy or thyromegaly,

pulse-110/min, blood pressure (BP)-160/95 mmHg, respiratory rate: 30 breaths/min (with deep and rapid respirations/kussmaul respiration). On systemic examination reveals following findings, lip, teeth, oral cavity-normal, her breath has a "fruity" odor; kidneys are not ballotable, fluid thrill-absent, there is no tenderness over the renal angle, and shifting dullness absent, no renal bruit. Higher psychic functions reveal drowsy and confused. Bedside urine examination: Sugar present and protein +++. Examination of the other systems reveals no abnormalities.

On laboratory investigation reveals hemoglobin: 9.3 g/dl (12-16), fasting blood glucose: >18 mmol/L. HbA1c: 12.2% (4.4-6.4), albumin: 2.4 mg/dl (4.1-5.1), globulin: 4.1 mg/dl (1.5-3.9), urea: 31 mg/dl (8-20), creatinine: 2.9 mg/dl (0.35-0.58), Na⁺: 138 mEq/l (135-150), K⁺: 6 mEq/l (3.5-5.0), Cl:100 mEq/l (98-106), HCO₃: 13 mEq/l (24-30), anion gap: 32 (12±4), arterial blood gas reveals pH 7.25 with PCO₂: 30 mmHg, PO₂: 92 mmHg, urinary ketone bodies: +++, and urinary proteins: +++. Renal biopsy investigation shows gradual loss of podocyte foot processes and narrowing of the filtration slits, with the simultaneous events of decrease number of podocytes. Basement membrane proliferation is associated with the changes of the visceral glomerular epithelial cells (periodic acid-schiff stain) as shown in Fig. 1. Ovoid or spherical, often laminated nodules of matrix located in the fringe of the glomerulus known as intercapillary glomerulosclerosis as shown in Fig. 2.

DISCUSSION

The effect of hyperglycemia and sudden weight loss is usually mediated through hemodynamic and multiple metabolic pathways in long term Type 1 diabetic patient [11,12]. Glucose homeostasis is accomplished through the coordinated actions of multiple vital organs, but mostly through equilibrium between the access of glucose into the circulation from the liver, and the uptake of glucose by skeletal muscle, adipose tissues and brain by the various glucose transporters [13]. Insulin, the principal controller of glucose metabolism and storage in retort to an increase in plasma glucose [14]. T cell-mediated autoimmune disorder relating destruction of the insulin secreting β cells in the pancreatic islets and reasons T1DM. Hyperglycemia due to more than 80% of β cells destruction leads to glycosuria, dehydration, causing fatigue, polyuria, nocturia, thirst, and polydipsia [15]. Insulin is the chief regulator not only of glucose metabolism but also of fatty acid and amino acid metabolism. Unrestrained lipolysis and proteolysis due to a severe lack of insulin consequence in sudden severe weight loss [16]. When the formation of ketone bodies exceeds the capacity for their metabolism in the liver, which is triggered by rapid lipolysis in the absence of insulin, leading to elevated circulating free fatty acid levels which are referred as diabetic ketoacidosis [17]. The free fatty acids are catabolized into fatty acyl-CoA inside the liver cells, which later on converted to ketone bodies within the mitochondria of liver cells. Metabolic acidosis is resulting from the accumulation of ketone bodies in the plasma, which is a well-known complication of T1DM [18].

As per previous some studies, T1DM can induce expression of intrarenal RAS genes [19-21]. Mechanical stress increases angiotensin II (A2) production and up-regulates AT1R in podocytes at the basement membrane [22]. Increased A2 exacerbates glomerular hypertension. A2 causes the express of the protein component of the slit diaphragm of podocyte is called nephrin. Notch1 is a transmembrane receptor that plays a part in cell differentiation and renal development. Notch1 couples A2 with nephrin results its receptor down regulation. Activation of Notch1 receptor leads to the release of the active Notch1 intracellular domain (ICN1). On Notch1 signaling both ICN1 and snail translocate to the nucleus and share in repression of nephrin expression and podocyte apoptosis [23,24]. Increased activity of polyol pathway by increased glucose absorption raises intracellular glucose availability with resulting increased fructose synthesis. Fructose metabolism leads to increased intracellular uric acid (UA) synthesis [25]. Nicotinamide adenine dinucleotide phosphate (NADPH) oxidase enzyme stimulate by UA and causing increased intracellular oxidative stress, endothelial

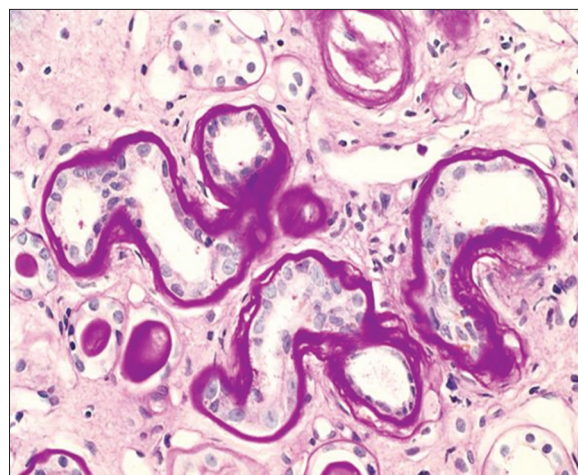


Fig. 1: Renal cortex showing solidifying of tubular basement membranes with loss of podocytes (periodic acid-schiff stain)

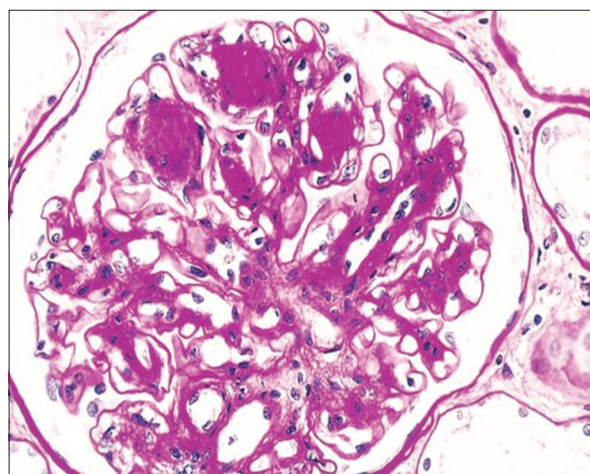


Fig. 2: Diffuse and nodular diabetic glomerulosclerosis (periodic acid-schiff stain)

injury, RAS activation, increased epithelial-mesenchymal transition mitochondrial injury and adenosine triphosphate depletion [26]. Human glomerular MCs express NADPH oxidase and activates protein kinase C, mitogen activated protein kinase, and nuclear factor-κB (NF-κB) which eventually results in overproduction of extracellular matrix proteins [27]. Excess fibroblasts infiltrate the interstitium with consequent progressive interstitial fibrosis [28]. Hyperglycemia triggers increased intracellular fibroblast growth factor 23 (FGF23) is a phosphatonin responsible for renal phosphate elimination. FGF23 inhibits 1-α hydroxylase gene with consequent decreased calcitriol synthesis. The previous study shown an inverse relationship between calcitriol and renin levels [29,30].

Dipeptidyl peptidase-4 (DPP-4) is a cell surface amino-peptidase enzyme is found in many cell types, including the endothelial cells in multiple organs including the kidney, which plays a significant part in glucoregulation by thought-provoking insulin release in a glucose-dependent manner [31]. Recent data, however, recommend that DPP-4 action is progressive in patients with T1DM related to healthy controls independently of islet cell autoimmune antibody status, C-peptide concentration, over all disease period or glycated hemoglobin (HbA1c) [32]. In normoglycemic status, microRNA-29 (miR29) controls membrane DPP-4 through suppression of its gene. Such effect is lost when miR29 levels decrease in hyperglycemic environment [33]. Elevated endothelin level is a constant feature of diabetic patients. Endothelin-1 (ET-1) is involved in the development

of DN [34]. DN is allied with increased countenance of surface DPP-4, predominantly on endothelial and tubular epithelial cells. This increased expression and activity targets a broad range of peptides within its vicinity [35]. Activated DPP-4 interacts with integrin b1 and induces its phosphorylation. Activated DPP-4 phosphorylated integrin b1 complex triggers transforming growth factor- β (TGF- β) receptor dimerization and activation of vascular endothelial growth factor receptor Type 1 [36]. Hyperglycemia, free oxygen radicals, and proteinuria causes activation of NF- κ B within the diabetic kidney [37]. Activated NF- κ B binds within the nucleus to the promoter regions of several genes that mediate the pathogenesis of DN like those encoding TGF- β 1, chemokine ligand 2 also recognized as MCP-1 and intercellular adhesion molecule 1 [38]. As a consequence, the diabetic kidney would be the site of macrophage recruitment and excess collagen deposition resulting solidifying of tubular basement membranes and nodular diabetic glomerulosclerosis which facilitates microangiopathy [39].

CONCLUSION

Managing diabetic patients to control blood sugar and its consequences only by insulin or oral hypoglycemic agents is often very tedious. The use of RAS gene blockers offers favorable effect on glomerular hyperfiltration. Sodium-glucose co-transporter-2 (SGLT-2) inhibitors offer a new addition to hyperfiltration control, does not require dose adjustment with progressive renal disease. Control of hyperuricemia and renal leukocyte recruitment inhibition can be achieved by Nrf2 agonists. Control of hyperphosphatemia and improvement of metabolic acidosis is required once the patient proceeds to Stage 4 chronic kidney disease. Finally, it should be emphasized that the oral hypoglycemic agents, namely, Metformin, pioglitazone, and SGLT2 inhibitors can be used in T1DM patients when developing DN.

ACKNOWLEDGMENTS

The authors would like to thank Collogues form AIMST university, Cyberjaya university college of medical science, Department of Pharmacology and most thankful to Prof. Dr. Sharfuddin Ahmed, the honorable Deputy vice chancellor of Bangabandhu Sheikh Mujib Medical University.

REFERENCES

1. Wen CP, Chang CH, Tsai MK, Lee JH, Lu PJ, Tsai SP, et al. Diabetes with early kidney involvement may shorten life expectancy by 16 years. *Kidney Int* 2017;92(2):388-96.
2. Allison SJ. Diabetic nephropathy: Glucose metabolic flux in DN. *Nat Rev Nephrol* 2017;13(7):384.
3. Axelgaard E, Østergaard JA, Thiel S, Hansen TK. Diabetes is associated with increased autoreactivity of mannan-binding lectin. *J Diabetes Res* 2017;2017:6368780.
4. Aoki Y, Tanimoto I, Miyauchi Y, Suzuki Y, Shiojiri T. A case of anti-glomerular basement membrane glomerulonephritis complicated by Type 1 diabetes mellitus, mimicking urinary tract infection. *Am J Case Rep* 2017;18:308-12.
5. Begum SM, Hemalatha S. Characterization, *in silico* and *in vitro* determination of antidiabetic and anti-inflammatory potential of ethanolic extract of sargassum wightii. *Asian J Pharm Clin Res* 2017;10(4):297-301.
6. Haghghatpanah GT, Jha A, Mallayasamy S. Study on prescribing pattern of anti-diabetic drugs among Type 2 diabetes patients with complication in South Indian teaching hospital. *Asian J Pharm Clin Res* 2016;9 Suppl 1:194-7.
7. Feigerlová E, Battaglia-Hsu SF. IL-6 signaling in diabetic nephropathy: From pathophysiology to therapeutic perspectives. *Cytokine Growth Factor Rev* 2017. pii: S1359-610130030-8.
8. Haneda M, Utsunomiya K, Koya D, Babazono T, Moriya T, Makino H, et al. A new classification of Diabetic Nephropathy 2014: A report from Joint Committee on Diabetic Nephropathy. *J Diabetes Invest* 2015;6:242-6.
9. Amutha A, Anjana RM, Venkatesan U, Ranjani H, Unnikrishnan R, Venkat Narayan KM, et al. Incidence of complications in young-onset diabetes: Comparing Type 2 with Type 1 (the young diab study). *Diabetes Res Clin Pract* 2017;123:1-8.

10. Noreen T, Taha M, Imran S, Chigurupati S, Rahim F, Selvaraj M, et al. Synthesis of alpha amylase inhibitors based on privileged indole scaffold. *Bioorg Chem* 2017;72:248-55.
11. Al-Waili N, Al-Waili H, Al-Waili T, Salom K. Natural antioxidants in the treatment and prevention of diabetic nephropathy; A potential approach that warrants clinical trials. *Redox Rep* 2017;22(3):99-118.
12. Imran S, Taha M, Selvaraj M, Ismail NH, Chigurupati S, Mohammad JI. Synthesis and biological evaluation of indole derivatives as a-amylase inhibitor. *Bioorg Chem* 2017;73:121-7.
13. Ahola AJ, Harjutsalo V, Thorn LM, Freese R, Forsblom C, Mäkimattila S, et al. The association between macronutrient intake and the metabolic syndrome and its components in Type 1 diabetes. *Br J Nutr* 2017;117(3):450-6.
14. Al Hussain T, Al Mana H, Hussein MH, Akhtar M. Podocyte and parietal epithelial cell interactions in health and disease. *Adv Anat Pathol* 2017;24(1):24-34.
15. Alicic RZ, Rooney MT, Tuttle KR. Diabetic kidney disease: Challenges, progress, and possibilities. *Clin J Am Soc Nephrol* 2017. pii: CJN.11491116.
16. Bragg F, Holmes MV, Iona A, Guo Y, Du H, Chen Y, et al. Association between diabetes and cause-specific mortality in rural and Urban areas of China. *JAMA* 2017;317(3):280-9.
17. Dabelea D, Stafford JM, Mayer-Davis EJ, D'Agostino R Jr, Dolan L, Imperatore G, et al. Association of Type 1 diabetes vs Type 2 diabetes diagnosed during childhood and adolescence with complications during teenage years and young adulthood. *JAMA* 2017;317(8):825-35.
18. Dugbartey GJ. Diabetic nephropathy: A potential savior with “rotten-egg” smell. *Pharmacol Rep* 2017;69(2):331-9.
19. Hirakawa Y, Tanaka T, Nangaku M. Mechanisms of metabolic memory and renal hypoxia as a therapeutic target in diabetic kidney disease. *J Diabetes Investig* 2017;8(3):261-71.
20. Homma K, Yoshizawa J, Shiina Y, Ozawa H, Igarashi M, Matsuoka T, et al. A dipeptidyl peptidase-4 inhibitor, teneligliptin, decreases plasma triglyceride-rich lipoprotein remnants in diabetic patients with chronic kidney disease undergoing hemodialysis. *Drugs R D* 2017.
21. Irannejad A, Ghajar A, Afarideh M, Khajeh E, Noshad S, Esteghamati S, et al. Association of peripheral nesfatin-1 with early stage diabetic nephropathy. *Pathophysiology* 2017;24(1):17-22.
22. Jin L, Wang T, Jiang S, Chen M, Zhang R, Hu C, et al. The association of a genetic variant in SCAF8-CNKS3 with diabetic kidney disease and diabetic retinopathy in a Chinese population. *J Diabetes Res* 2017;2017:6542689.
23. Kemmer S, Lorenz G, Wobst J, Kessler T, Wen M, Günthner R, et al. Dietary nitrate load lowers blood pressure and renal resistive index in patients with chronic kidney disease: A pilot study. *Nitric Oxide* 2017;64:7-15.
24. Khidr EG, Ali SS, Elshafey MM, Fawzy OA. Association of irisin and FNDC5 rs16835198 G>T gene polymorphism with Type 2 diabetes mellitus and diabetic nephropathy. An Egyptian pilot study. *Gene* 2017;626:26-31.
25. Xing Y, Lai J, Liu X, Zhang N, Ming J, Liu H, et al. Netrin-1 restores cell injury and impaired angiogenesis in vascular endothelial cells upon high glucose by PI3K/AKT-eNOS. *J Mol Endocrinol* 2017;58:167-77.
26. Xu Z, Diao Z, Liu R, Liu W. Molecular mechanism of smurf2 in regulating the expression of SnoN in diabetic nephropathy. *Mol Med Rep* 2017;15(5):2560-6.
27. Yao M, Gao F, Wang X, Shi Y, Liu S, Duan H. Nox4 is involved in high glucose-induced apoptosis in renal tubular epithelial cells via Notch pathway. *Mol Med Rep* 2017;15(6):4319-25.
28. Zhang H, Nair V, Saha J, Atkins KB, Hodgins JB, Saunders TL, et al. Podocyte-specific JAK2 overexpression worsens diabetic kidney disease in mice. *Kidney Int* 2017. pii: S0085-253830230-2.
29. Zanchi C, Macconi D, Trionfini P, Tomasoni S, Rottoli D, Locatelli M, et al. MicroRNA-184 is a downstream effector of albuminuria driving renal fibrosis in rats with diabetic nephropathy. *Diabetologia* 2017;60(6):1114-25.
30. Yuan CM, Nee R, Ceckowski KA, Knight KR, Abbott KC. Diabetic nephropathy as the cause of end-stage kidney disease reported on the medical evidence form CMS2728 at a single center. *Clin Kidney J* 2017;10(2):257-62.
31. Zha D, Wu X, Gao P. Adiponectin and its receptors in diabetic kidney disease: Molecular mechanisms and clinical potential. *Endocrinology* 2017.
32. Yokoi H, Mukoyama M. Analysis of pathological activities of CCN proteins in fibrotic diseases: Kidney fibrosis. *Methods Mol Biol* 2017;1489:431-43.
33. Xu L, Niu M, Yu W, Xia W, Gong F, Wang O. Associations

- between FGF21, osteonectin and bone turnover markers in Type 2 diabetic patients with albuminuria. *J Diabetes Complications* 2017;31(3):583-8.
34. Xue R, Gui D, Zheng L, Zhai R, Wang F, Wang N. Mechanistic insight and management of diabetic nephropathy: Recent progress and future perspective. *J Diabetes Res* 2017;2017:1839809.
 35. Yang S, Han Y, Liu J, Song P, Xu X, Zhao L, *et al.* Mitochondria: A novel therapeutic target in diabetic nephropathy. *Curr Med Chem* 2017.
 36. Vitova L, Tuma Z, Moravec J, Kvapil M, Matejovic M, Mares J, *et al.* Early urinary biomarkers of diabetic nephropathy in Type 1 diabetes mellitus show involvement of kallikrein-kinin system. *BMC Nephrol* 2017;18(1):112.
 37. Wanner N, Bechtel-Walz W. Epigenetics of kidney disease. *Cell Tissue Res* 2017;369(1):75-92.
 38. Wasik AA, Dumont V, Tienari J, Nyman TA, Fogarty CL, Forsblom C, *et al.* Septin 7 reduces nonmuscle myosin IIA activity in the SNAP23 complex and hinders GLUT4 storage vesicle docking and fusion. *Exp Cell Res* 2017;350(2):336-48.
 39. Wimalasena S, Kendrick-Jones J, Hawkins S, Talreja H. Renal artery embolisation for uncontrolled hypertension in ESRD. *N Z Med J* 2017;130(1448):73-6.