

**TOTAL ANKLE REPLACEMENT FOR TREATMENT OF AVASCULAR NECROSIS OF THE TALUS****JIN AUN TAN, MOHD YAZID BAJURI\*, JUZAILY FEKRY LEONG, LEVIN KB, AZAMMUDDIN ALIAS**

Department of Orthopaedic and Traumatology, Faculty of Medicine, Universiti Kebangsaan, Malaysia Medical Centre, Kuala Lumpur, Malaysia. Email: ezeds007@yahoo.com.my

Received: 03 March 2018, Revised and Accepted: 23 April 2018

**ABSTRACT**

Avascular necrosis (AVN) of talus is a well-known complication following talar neck fracture that leads to osteoarthritis of the ankle joint. Tibiotalar fusion is the gold standard of treatment in end-stage ankle osteoarthritis with predictable good outcome. With the introduction of newer generation of total ankle replacement (TAR), it is gaining popularity as an alternative treatment in selected cases of ankle joint osteoarthritis secondary to AVN talus. We present here a case of ankle joint osteoarthritis secondary to AVN talus in a 30-year-old female in which a TAR was performed. We wish to highlight that TAR can be done in ankle joint osteoarthritis with AVN talus in properly selected cases.

**Keywords:** Talus fracture, Avascular necrosis, Total ankle replacement.© 2018 The Authors. Published by Innovare Academic Sciences Pvt Ltd. This is an open access article under the CC BY license (<http://creativecommons.org/licenses/by/4.0/>) DOI: <http://dx.doi.org/10.22159/ajpcr.2018.v11i8.25602>**INTRODUCTION**

Avascular necrosis (AVN) of the talus is a well-known complication of talus fractures. For most, ankle arthrodesis has been the gold standard to treat end-stage ankle post-traumatic arthritis due to underlying talar AVN. However, ankle arthrodesis does not come without complications. Its common complications include non-union, malunion, prolonged immobilization and no weight-bearing, and decreased functional ability [1]. Due to prolonged periods of immobilization, the patients undergoing ankle arthrodesis would have more muscle atrophy of the affected limb resulting in dysfunctional gait even after union has been achieved. Besides that, ankle joint osteoarthritis may affect the adjacent joints, namely the talonavicular, subtalar, calcaneocuboid, naviculocuneiform, and tarsometatarsal joints. We present a case of ankle joint osteoarthritis secondary to AVN talus in a 30-year-old female in which a total ankle replacement (TAR) was done.

**CASE REPORT**

Miss H, a 30-year-old female, with a history of the right talar neck and calcaneal fracture 18 years ago, presented with chronic pain over her right ankle. It was associated with stiffness and difficulty in walking, especially when she going up the stairs and required crutches for ambulation. Clinical assessment revealed the right ankle joint was infixed plantar flexion of 10° with tenderness of the tibiotalar joint on palpation. There was no movement of the subtalar joint. The hindfoot was in approximately 5° valgus, and there was no tenderness over the talonavicular joint. Her hindfoot and ankle scale of the American Orthopedic Foot and Ankle Society (AOFAS) scored only a mere 25 points.

The radiograph of her right ankle revealed secondary osteoarthritis of the right tibiotalar joint with more than 50% collapse of the talar dome. The subtalar joint appears to have fused, and there were minimal degenerative changes over the talonavicular joint (Fig. 1).

She was given two options regarding treatment mainly the right ankle arthrodesis or total ankle replacement (TAR). The advantages and disadvantages of both procedures were properly discussed and explained to her, and she opted for TAR. The risk of future implant loosening, implant subsidence, particularly of the talar component, and possibility of periprosthetic fractures was among the main

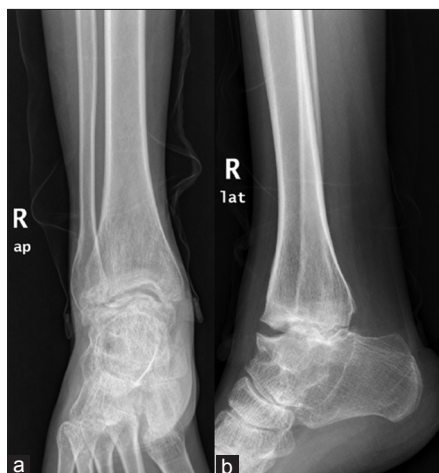complications of TAR. She chose to undergo TAR as she wanted to preserve her ankle joint motion. The surgeons knew that the decision for TAR may be controversial in the presence of talus AVN; however, the patient's insistence and willingness of undergoing TAR led to this mutual decision. She underwent right TAR using a three-component mobile-bearing HINTEGRA prosthesis.

Incision was made according to the extensile anterior approach whereby the right ankle joint was exposed. Intraoperative findings showed partial fusion of the tibiotalar joint. Take-down fusion was carried out, followed by performing the tibial cut and then the talar cut. The talar bone stock was assessed, and it was sufficient for adequate press fit of the talar component. Trials of implants were done followed by insertion of the talar component, the tibial component, and the mobile-bearing polyethylene. The talar and tibial components were hammered by means of an impactor to ensure adequate press fit to the bones. The wound was closed and below knee backslap was applied to keep the ankle in neutral position to prevent plantar flexion postoperatively. Wound inspection was done on the 3<sup>rd</sup> post-operative day, and she was allowed to be discharged with strict no weight-bearing.

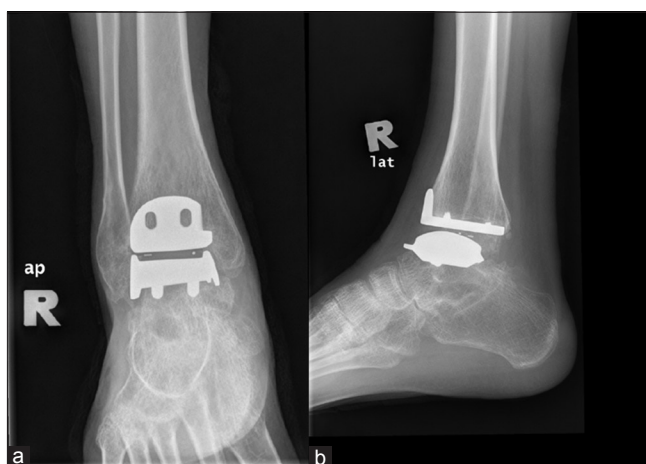
At the most recent follow-up which is 12-month post-surgery, the patient presented with satisfactory clinical outcome and radiological result. She is able to ambulate without pain and has regained range of movement of her right ankle enabling her to walk on uneven surfaces and climb upstairs more easily. Radiographs of the right ankle showed that the tibial and talar components are well aligned with no signs of loosening or implant migration (Fig. 2). The patient was satisfied and the score on the AOFAS hindfoot and ankle scale has improved to 84 points.

**DISCUSSION**

To overcome the limitations of ankle arthrodesis, surgeons may offer patients TAR as it preserves joint motion. In the earlier designs for the first generation TAR, cement was used and hence made the components very constrained. This ended up with high failure rates such as implant loosening and periprosthetic fracture [2]. Several improvements were made, and the newer generations of TAR are less constrained and cementless, being more porous coated to allow interdigitation at the bone-implant interface, and hence, the fixation depends on osteointegration rather than cementation [3].



**Fig. 1: (a) Anteroposterior and (b) lateral views of the right ankle during presentation in the clinic**



**Fig. 2: (a) Anteroposterior and (b) lateral images of the right ankle 12-month post right total ankle replacement**

A requirement for osteointegration to occur when using cementless TAR is that there is enough viable bone, so as to provide a solid bone-implant interface for good stability. Based on this, using cementless TAR to treat AVN of the talus affecting more than 30% of the talar body is relatively contraindicated, while AVN affecting more than 50% of the body is absolutely contraindicated, as there is insufficient viable bone over the talus to ensure good bony ingrowth [4]. If this requirement is not met, this may result in talar component subsidence or migration in which it is an undesired outcome.

A phenomenon known as creeping substitution whereby areas of necrotic bone at the talar body is revascularized over time, providing sufficient support and area for good bony ingrowth had been explained. The authors also suggested that this phenomenon would require a minimum of 2–3 years to occur. However, as of now, there are no gold standard investigatory modalities to ascertain when and how much an avascular talus has revascularized. Magnetic resonance imaging used together with radionuclide bone scanning has been recommended to ascertain the extent of talar AVN [5].

In this case, the talar bone stock was adequate intraoperatively and was enough to provide good press fit for the talar component. The long duration from time of accident to this current surgery would have allowed creeping substitution to occur, resulting in adequate bone stock. Intraoperatively, only approximately 20% of the talar body

had poor bone stock allowing TAR to be carried out. Postoperatively, this patient was suggested to do combination of circuit training with interferential therapy and isometric therapy to achieve the maximum effectiveness of functional outcome of the ankle movement [6]. Besides that, the combination of pregabalin with NSAIDS group had proven to reduce the pain, improve activity daily living and quality of life as well [7]. Another effective combination therapy that shown to improve osteoarthritis symptoms was diacerein and meloxicam in which this combination has a significant effect at the 3<sup>rd</sup> week of usage [8]. Another major factor that should be considered is body weight management in obese patient who has chronic disease such as osteoarthritis. Osteoarthritis patients who are body mass index above 25 and considered safe are strongly recommended to take antiobesity treatment such as sibutramine and orlistat because it can losses weight up to 10% in combination of good dietary and sufficient exercise [9]. This will enhance the good overall outcome of the procedure.

Although we are suggested TAR for the treatment of AVN of talar bone in this case, ankle arthrodesis remained as well-known procedure with reliable technique [10]. Nevertheless, ankle arthrodesis poses multiple limitations and sometimes reduces patients' quality of life in the long term.

## CONCLUSION

The good clinical outcome and patient satisfaction attained from this case pave way for the role of TAR in the treatment of AVN of the talus in selected cases. Surgeons may counsel patient for TAR, however, must also explain that conversion to ankle arthrodesis intraoperatively may occur. TAR is a possible alternative to ankle arthrodesis and ought not to be taken as an absolute contraindication in the treatment of AVN of the talus.

## AUTHOR'S CONTRIBUTION

All the authors contributed equally to conductance of the study, writing and editing the article.

## CONFLICTS OF INTEREST

None of the authors have any conflicts of interest to be declared.

## ACKNOWLEDGMENT

The authors would like to thank Dr. Abdul Muhaimin Ali for his technical help in publishing this article.

## REFERENCES

1. Nihal A, Gellman RE, Embil JM, Trepman E. Ankle arthrodesis. *Foot Ankle Surg* 2008;14:1-0.
2. Kitaoka HB, Patzer GL. Clinical results of the Mayo total ankle arthroplasty. *JBJS* 1996;78:1658-64.
3. Younger A, Penner M, Wing K. Mobile-bearing total ankle arthroplasty. *Foot Ankle Clin* 2008;13:495-508.
4. Hintermann B, Knupp M, Zwicky L, Barg A. Total ankle replacement for treatment of end-stage osteoarthritis in elderly patients. *J Aging Res* 2012;2012:1-8.
5. Lee KB, Cho SG, Jung ST, Kim MS. Total ankle arthroplasty following revascularization of avascular necrosis of the talar body: Two case reports and literature review. *Foot Ankle Int* 2008;29:852-8.
6. Pallavi B, Vaishali J, Devi TP. Effect of circuit training in osteoarthritis of knee. *Asian J Pharm Clin Res* 2017;10:333-5.
7. Tamilslevan T, Kalaivani H. A clinical study on management of post-operative pain and quality of life of osteoarthritis patients after total knee arthroplasty. *Asian J Pharm Clin Res* 2018;11(4):93-5.
8. Oka DN, Prayitno SA. Comparison of pain score in osteoarthritis patients treated with a combination of diacerein and meloxicam and meloxicam alone. *Int J Pharm Pharm Sci* 2017;9:69-73.
9. Kumar BM, Manjula S, Kumar RS. Obesity: Development, epidemiology, factors affecting, quantity, health Hazards, management and natural treatment-a review. *Int J Pharm Pharm Sci* 2017;9:12-26.
10. Bajuri MY, Abdullah A. Ankle arthritis: Which to choose—arthrodesis or arthroplasty. *J Surg Acad* 2017;7:4-8.