

STEREOTACTIC BRAIN BIOPSY: A REVIEW OF 15 CASES WITH OUTCOMES

ASHOK KUMAR^{1*}, CARVALHO AS¹, SURENDER², RAPPAL TJ¹¹Department of Neurosurgery, Surgical Division Command Hospital, Lucknow, Uttar Pradesh, India. ²Department of Anaesthesiology, Muzaffarnagar Medical College, Muzaffarnagar, Uttar Pradesh, India. Email: ashoktanwar8695@gmail.com

Received: 19 August 2020, Revised and Accepted: 04 October 2020

ABSTRACT

Objectives: Despite improvements in the imaging techniques which aid pre-operative diagnosis, starting specific treatment requires confirmation by histopathological examination (HPE). However dilemma arises in deep seated lesions, lesions in eloquent areas, and lesion in a patient with a poor performance score for palliation/adjuvant therapy. The aim of this study is to determine the diagnostic accuracy and benefits of stereotactic biopsy (STB) in cases of clinical dilemma plus its effect on post-operative stay, morbidity and mortality, and overall management of patients.

Methods: In this study, a prospective analysis of 15 patients who underwent STB in our hospital from September 2019 to July 2020 was made. The histopathological data derived from the STB, its clinical benefits, and post-operative hospital stay were analyzed.

Results: In terms of histopathology, glial tumor (66.7%) was the most common lesion. The success of obtaining positive STB samples in our study was 100%. Average post-operative stay was 3 days. The clinical benefits were immense as seen in the varied presentations and clinical dilemma with which the patients presented and a how a safely sourced tissue for histopathological diagnosis by STB greatly altered the treatment of the patient.

Conclusion: STB is a multifaceted tool in clinical practice. It can be used in diagnostic and therapeutic situations. Furthermore, in recurrent high-grade cases, it aids in providing HPE diagnosis for a more logical adjuvant treatment than one that follows an assumed diagnosis based on image findings/undergo a high-risk interventional procedure to get a specimen. It is a relatively safe procedure.

Keywords: Brain lesion, Radiology, Stereotactic biopsy.

© 2020 The Authors. Published by Innovare Academic Sciences Pvt Ltd. This is an open access article under the CC BY license (<http://creativecommons.org/licenses/by/4.0/>) DOI: <http://dx.doi.org/10.22159/ajpcr.2020.v13i12.39447>

INTRODUCTION

Stereo taxis in neurosurgery was first used in the 1950s [1,2]. Histopathological diagnosis is of utmost importance in determining treatment modalities in neuro-oncology. Stereotactic biopsy (STB) is used as the first choice in diagnosing deep seated cerebral lesions, multifocal lesions, and lesions located in functional eloquent areas. However, its applications and benefits are far more than just these as seen in our series. This is the first of its kind of study being conducted at any tertiary care hospital in India. The objective of this study to emphasize about safety, avoidance of general anesthesia (GA), and that how STB has changed the course of management of patients. In this study, we present the data of 15 STB of 15 selected patients.

METHODS

Study site

This study was conducted in Defense Hospital, Lucknow, Uttar Pradesh. It is an Tertiary Care Hospital, providing specialized health-care services to all dependent defense population.

Study design

This is a hospital-based prospective study conducted on in-patients to determine the diagnostic accuracy and benefits of STB in cases of clinical dilemma plus its effect on post-operative stay, morbidity and mortality, and overall management of patients.

Sample size

A total of 15 cases underwent stereotactic brain biopsy for various brain lesions.

Study period

A prospective study was conducted for a period of 11 months from September 2019 to July 2020.

Stereotactic brain biopsy and related procedures performed in this study involving participants were in accordance with the ethical standards of the Institutional Ethical Committee and with the 1964 Helsinki Declaration and its later amendments. All individual participants included in the study were counseled in the presence of their next of kin and written informed consent obtained from them. Standard pre-operative orders were followed; all received pre-operative antiepileptic (phenytoin [PHT]) and steroids. PHT has been the most commonly prescribed antiepileptic drug in study [3].

Fifteen patients underwent STB procedures at our institute to diagnose cerebral lesions. All but one patient underwent the procedure under local anesthesia (LA)/scalp block. One patient required GA as she was unco-operative.

Technique

Stereotactic protocol contrast-enhanced T1-weighted magnetic resonance (MR) images were obtained. Stereotactic frame was placed on the patients under LA and non-contrast computerized tomography (CT) images were obtained. Both images were uploaded in the Cosman, Roberts, and Wells (CRW) stereotactic system and fusion of images was performed. The x, y, and z coordinates were calculated. All but one was operated under LA, and the biopsies were performed through a burr hole using the Nashold Biopsy Needle. Two targets were taken in the lesion 2 mm apart and two biopsies taken from each target. Thus, four core biopsies were obtained.

RESULTS

Between September 2019 and July 2020, 15 patients underwent STB procedures at our institute to diagnose cerebral lesions. In our study, 11 were male and 04 were female (Fig.1) with age ranging from 13 to 64 years (mean = 42.6 years).

The STB was done for six small deep seated/peripheral small lesions of diagnostic uncertainty (Figs. 2, 3 and 4).

Three patients were referred by the neurologist with inconclusive neuroimaging (Fig. 2) who presented with seizures, one patients of recurrent high lesions on the same primary site, two recurrent lesions at a different site than the primary who were unwilling for redo/gross total resection, and three patients with multiple lesions who were referred by the department of oncology (Figs. 4 and 5).

Of the three recurrent lesions, one had a recurrent high-grade lesion of the same primary and two had a lesion at a different site from the primary which was the World Health Organization (WHO) Grade II and WHO Grade III, respectively.

Histopathological results of the STB procedures of 15 cases were as follows: Ten gliomas, three metastases, and two lymphoma (Table 1 and Fig. 6). According to the histopathological examination, 10 (66.7%) of 15 cases were diagnosed with glial tumors in this series. Five of the glial tumors were low grade (Fig. 7).

The distribution of the lesions was lobar lesions seven, thalamus/basal ganglia lesions five, and multifocal lesions three (Table 2).

We had 100% histopathological confirmation in all cases. The average hospital stay was 3 days. One patient had per-operative seizure managed with intravenous lorazepam, his post-operative CT scan showed pneumocephalus and a minor parenchymal hematoma. He was managed conservatively and made a complete recovery. No significant neurological deficits were seen in any other patient.

All underwent post-operative CT scan, to check the targeting and as part of standard protocol at our institute for all cranial surgeries.

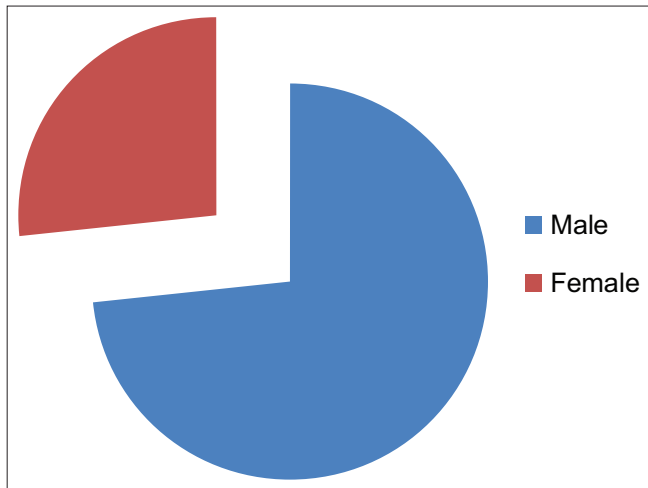


Fig. 1: Graphical representation of the distribution of 15 patients based on gender

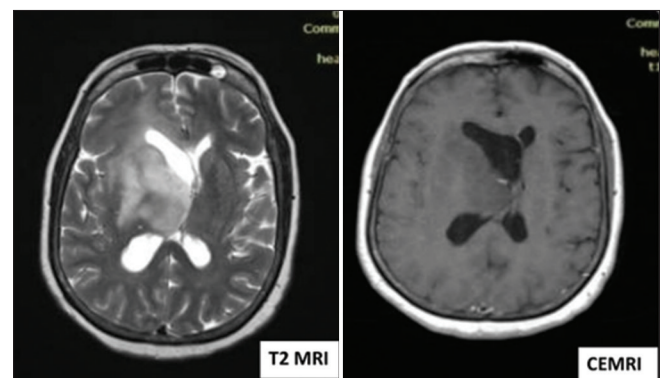


Fig. 4: RT Thalamic non enhancing lesion

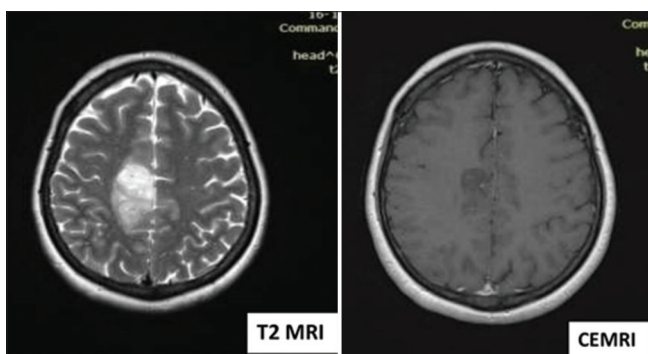


Fig. 2: RT frontal deep seated mildly enhancing lesion

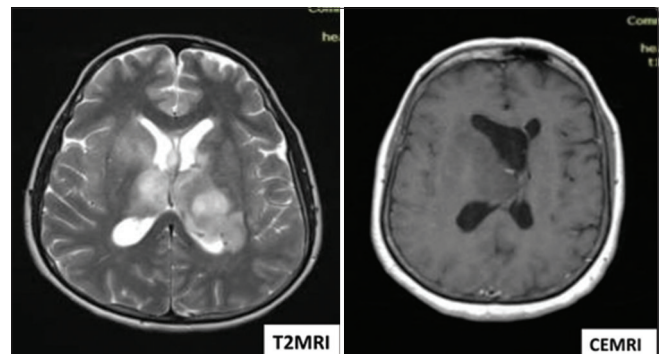


Fig. 5: B/L Thalamic non enhancing lesion

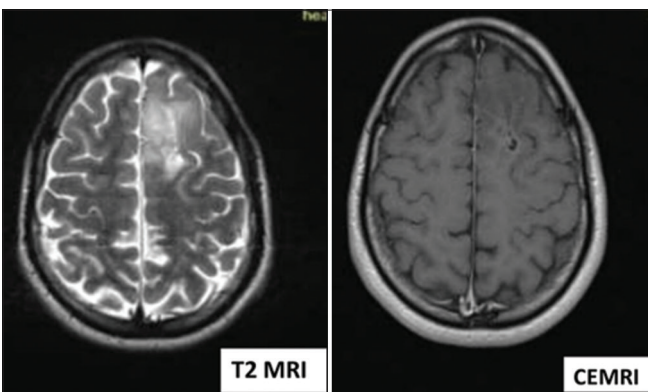


Fig. 3: LT frontal non enhancing lesion

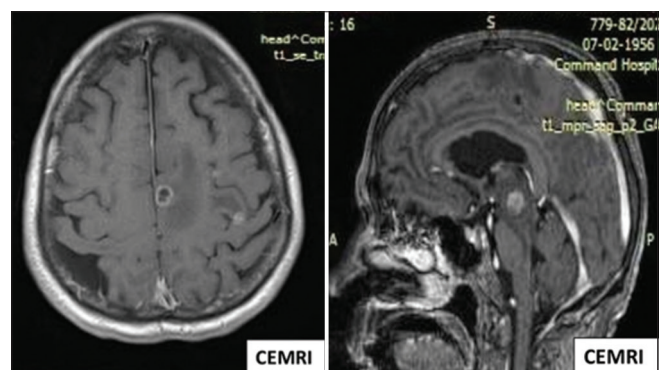


Fig. 6: Multiple intracranial contrast enhancing lesion

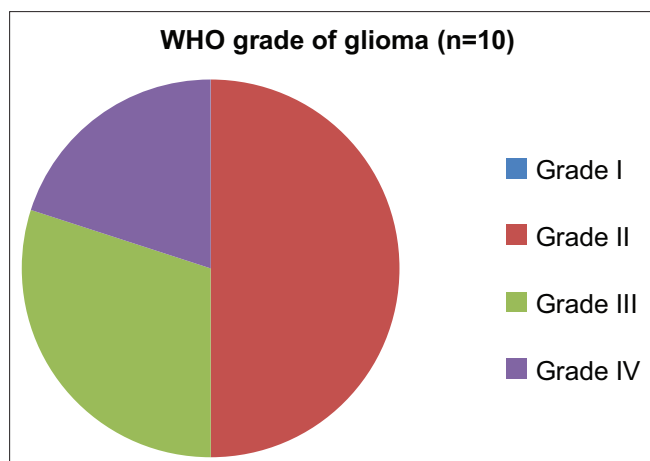


Fig. 7: Graphical representation of 10 glioma patients based on the histopathological grades of tumor

Table 1: Histopathology of stereotactic biopsies (n=15)

Type of lesion	Number of patients	Percentage
Glial tumor	10	66.7
Metastasis Adenocarcinoma	03	20.0
Lymphoma	02	13.3
Total	15	100

Table 2: The distribution of the lesions in brain (n=15)

Site	Number of patients	Percentage
Thalamic lesions/basal ganglia	05	33.3
Multifocal lesion	03	20.0
Lobar lesions	07	46.7
Total	15	100

DISCUSSION

Gross-total excision is the surgical approach preferred for all intra parenchymal tumors and survival is largely dependent on the extent of tumor resection [4,5]. However, in patients with multiple lesions, inconclusive neuroimaging, recurrent lesions, STB gives a safe and a sure way of getting a tissue diagnosis, This will help in prognosticating/planning a further course of action in a more logical and a definitive way. Small deep seated/peripheral lesions with inconclusive neuroimaging especially in young patients are particularly benefited by this procedure. The success of obtaining positive STB samples in the our series was 100%, whereas in the previous studies using the CRW/Leksell system, it was reported to be over 90% [4,6]. We did not have any significant complication except for one patient who had an intra-operative seizure, CT showed a minor parenchymal bleed. All patients were observed in the intensive care unit for 24 h and were discharged after 3 days, none had any wound issues. Complication rates are known to be 2-5% [6-12]. There were no vessel injury, mortality, or technical failure in our study. Hemorrhagic complication or vessel injury during procedure have been reported as 2.1% [13], 3% [14], 4.35% [15], of which 1% are symptomatic requiring additional treatment.[15]. In their study, Yamada *et al* found the mean rate of minor bleeding at 9.9% in their STB series [11]. Following STB, no gross neurological deficits were found in our study; however, this is a small study and this is an initial attempt in analyzing the role and efficacy of STB at a busy tertiary care center.

CONCLUSION

The success of obtaining positive STB samples in the current series was 100%. The complication rate in this series was 6.7%. The post-

operative stay was reduced and there were no significant neurological deficits. The accuracy of the STB sampling rate and the complication rate was similar to those reported in the relevant literature.

STB is a highly safe method in diagnosing lesions, in which surgical excision/open biopsy present significant risks of morbidity and mortality. STB has a learning curve, especially in the handling of the software and fusion of images, but it is a very handy diagnostic and therapeutic tool in a busy tertiary care center to apply to selected patients who otherwise would have undergone either observation or palliative treatment or would have had a surgery and a long hospital stay and probably a disabling neurological deficit.

ACKNOWLEDGMENT

The authors would like to thank the Department of Anesthesiology and critical care, Department of Radiodiagnosis and Imaging, and Department of Pathology, Command Hospital, Lucknow and all the team members who supported while preparing this article.

AUTHORS' CONTRIBUTIONS

All the cases presented in the current study were operated by Ashok Kumar and AS Carvalho. Ashok Kumar, AS Carvalho, Surender, and TJ Rappai made a substantial contribution in conception, acquisition of data, interpretation of data, in drafting the article and revising it for ensuring critical academic content and agreed to be held accountable for all aspects of the work.

CONFLICTS OF INTEREST

The authors declare that there are no conflicts of interest related to this study.

AUTHORS' FUNDING

The author(s) received no specific funding for this work.

REFERENCES

- Leksell L. A stereotaxic apparatus for intracerebral surgery. *Acta Chir Scand* 1949;99:229-333.
- Spiegel EA, Wycis HT, Marks M, Lee AJ. Stereotaxic apparatus for operations on the human brain. *Science* 1947;106:349-50.
- Vettikkadan AR, Jith A, Krishnaveni K, Kumar RS. Study of utilization pattern and drug interactions of antiepileptic drugs in a private hospital. *Asian J Pharm Clin Res* 2014;7:164-6.
- Lacroix M, Abi-Said D, Fournier DR, Gokaslan ZL, Shi W, DeMonte F, *et al*. A multivariate analysis of 416 patients with glioblastoma multiforme: Prognosis, extent of resection, and survival. *J Neurosurg* 2001;95:190-8.
- Wood JR, Green SB, Shapiro WR. The prognostic importance of tumor size in malignant gliomas: A computed tomographic scan study by the Brain Tumor Cooperative Group. *J Clin Oncol* 1988;6:338-43.
- Bouvier G, Couillard P, Leger SL, Lesage J, Rotent F, Beique RA, *et al*. Stereotactic biopsy of cerebral space-occupying lesions. *Appl Neurophysiol* 1983;46:227-30.
- Abernathey CD, Camacho A, Kelly PJ. Stereotaxic suboccipital transcerebellar biopsy of pontine mass lesions. *J Neurosurg* 1989;70:195-200.
- Apuzzo ML, Chandrasoma PT, Cohen D, Zee CS, Zelman V. Computed imaging stereotaxy: Experience and perspective related to 500 procedures applied to brain masses. *Neurosurgery* 1987;20:930-7.
- Apuzzo ML, Sabshin JK. Computed tomographic guidance stereotaxis in the management of intracranial mass lesions. *Neurosurgery* 1983;12:277-85.
- Thomas DG, Anderson RE, Du Boulay GH. CT-guided stereotactic neurosurgery: Experience in 24 cases with a new stereotactic system. *J Neurol Neurosurg Psychiatry* 1984;47:9-16.
- Yamada K, Goto S, Kochi M, Ushio Y. Stereotactic biopsy for multifocal, diffuse, and deep-seated brain tumors using leksell's system. *J Clin Neurosci* 2004;11:263-7.
- Yamasaki T, Moritake K, Takaya M, Kagawa T, Nagai H, Akiyama Y, *et al*. Intraoperative use of doppler ultrasound and endoscopic

- monitoring in the stereotactic biopsy of malignant brain tumors. Technical note. *J Neurosurg* 1994;80:570-4.
13. Bander ED, Jones SH, Pisapia D, Magge R, Fine H, Schwartz TH, *et al.* Tubular brain tumor biopsy improves diagnostic yield for subcortical lesions. *J Neurooncol* 2019;141:121-9.
 14. Dammers R, Schouten JW, Haitsma IK, Vincent AJ, Kros JM, Dirven CM. Towards improving the safety and diagnostic yield of stereotactic biopsy in a single centre. *Acta Neurochir (Wien)* 2010;152:1915-21.
 15. Frati A, Pichierra A, Bastianello S, Raco A, Santoro A, Esposito V, *et al.* Frameless stereotactic cerebral biopsy: Our experience in 296 cases. *Stereotact Funct Neurosurg* 2011;89:234-45.