

**PRIMARY BONE GRAFTING AND K-WIRE FIXATION: A PREFERABLE OPTION TO TREAT ACUTE UNSTABLE SCAPHOID FRACTURE**THAKUR SK<sup>1\*</sup>, CHOUDHARY SK<sup>1</sup>, JOSEPH J B MAL<sup>2</sup>, HIREMATH RN<sup>3</sup><sup>1</sup>Orthopaedic Surgeon, Jalandhar, Punjab, India. <sup>2</sup>Assistant Professor, Department of Orthopaedics, Punjab Institute of Medical Sciences, Jalandhar, Punjab, India. <sup>3</sup>Public Health Specialist, Bangalore, Karnataka, India. Email: drsunil1506@gmail.com

Received: 28 May 2021, Revised and Accepted: 02 August 2021

**ABSTRACT**

**Objective:** The objective of this study is to analyze the radiological, clinical, and functional outcomes of patients with acute unstable scaphoid fracture treated with primary bone grafting and K (Kirschner)-wire fixation.

**Methods:** A prospective study was carried out at one of the multispecialty hospitals in Northern India. A total of 21 patients of all age groups and of both sexes with acute unstable scaphoid fracture (Herbert type B) were included who had been treated with open reduction, contiguous bone grafting, and fixation with K-wire and were followed up for a minimum of 24 weeks. A written informed consent was obtained from each subject before the conduct of the study. Fractures were assessed clinically and radiologically with wrist posteroanterior (PA), lateral, and PA with ulnar deviation view and classified according to the Herbert classification. Preoperatively, all patients had been immobilized in below-elbow slab. Clinical parameters such as tenderness, grip strength, and Range of Movement at wrist was assessed. The functional outcome was evaluated using the Modified Mayo wrist score. Bone union was assessed using serial plain radiographs.

**Results:** The average patient age was 26.9 years. The time from injury to treatment averaged 11 days. Surgery was done under Bier's Block using volar approach. Bone graft was harvested from the distal radius. The mean operating time was 24 minutes. Union was achieved in all (100%) at 12 weeks. There was no evidence of Avascular necrosis or arthrosis at latest follow-up. As per Modified Mayo wrist score, there were 15 excellent, three good, and three fair results at the final follow-up. Individuals resumed their routine work at 12 weeks, and all were comfortable with heavy works sports activity by 24 weeks.

**Conclusion:** Primary bone grafting has a definite role in the management of acute unstable scaphoid fracture by which a quicker and higher rate of union is achieved with minimal complications. Open reduction allows thorough assessment of fracture for better anatomic reduction. Although the type of fixation device hardly contributes for quicker and higher union, but then the use of K-wire for fixation is the only viable option for smaller bony fragments and is more forgiving in terms of its positioning. It has an added advantage in terms of the requirement of minimal inventory and thus is a cost-effective modality. This procedure also confirms that the patients could get back to their work earlier, hence decreasing the economic burden.

**Keywords:** Scaphoid fracture, Primary bone grafting, K wire fixation.

© 2021 The Authors. Published by Innovare Academic Sciences Pvt Ltd. This is an open access article under the CC BY license (<http://creativecommons.org/licenses/by/4.0/>) DOI: <http://dx.doi.org/10.22159/ajpcr.2021v14i9.42217>. Journal homepage: <https://innovareacademics.in/journals/index.php/ajpcr>

**INTRODUCTION**

Scaphoid fracture, not only its diagnosis but also its treatment, has been a subject of controversy from the remote past in medical writings. Scaphoid fractures usually result from a forceful extension of the wrist and predominantly occur in young, active males and it accounts for 2% to 3% of all fractures, approximately 10% of all hand fractures, and between 60% and 80% of all carpal fractures [1].

The recent studies have agreed upon the bluntness of this little fracture which can be vividly reflected as the diagnosis and the treatment are multilingual. Besides substantial morbidities like delayed union, nonunion, avascular necrosis (AVN), and degenerative arthritis, the time off from work and loss of earnings constitute other drawbacks [2]. The common consensus among surgeons is to incline more toward surgical recourse as shown in the recent studies that patients with surgically fixed fractures have a faster rate of healing and earlier return to work [3].

The comminution, translation, and location in the proximal pole make scaphoid fractures unstable and are associated with longer time to union [4]. The precarious, largely retrograde blood supply, instability of fracture, and synovial bathing potentiate its nonunion [5]. As nonunion rates for such fractures are reported to be as high as 50% and its treatment is very challenging, operative intervention is universally

recommended for unstable scaphoid fractures [6]. Furthermore, despite the advent of newly developed fixation techniques like PSF/ Arthroscopic fixation, the nonunion rates for scaphoid fracture remain as high as 10% after surgical treatment [3]. Therefore, it is wise to retrospect the biological option that might augment fracture healing.

Much has been written regarding the use of bone grafting in the management of scaphoid nonunion, however, comparatively very little is known about the need of bone grafting and its outcome in case of acute unstable scaphoid fractures [7]. One of the studies has concluded that open reduction and K-wire fixation with bone grafting results in better anatomic reduction, decreases the chance of non-union and AVN, shortens period of hospital stay, and early mobilization [8].

The hypothesis of this study is that the contiguous bone grafting in the management of unstable scaphoid fractures will not only enhance bone healing and shorten the union time but will also decrease the rate of delayed union, nonunion, and subsequent arthritis. The use of K-wire as a fixation device requires minimal inventory so it will be a cost-effective procedure. This simple and easy technique will shorten the surgical duration and will reduce the complications associated with surgery and anesthesia. Furthermore, in case of failure of fracture to unite or onset of AVN, the subsequent operative interventions will be easier if K-wire is used. The purpose of our study is to assess the clinical, radiological,

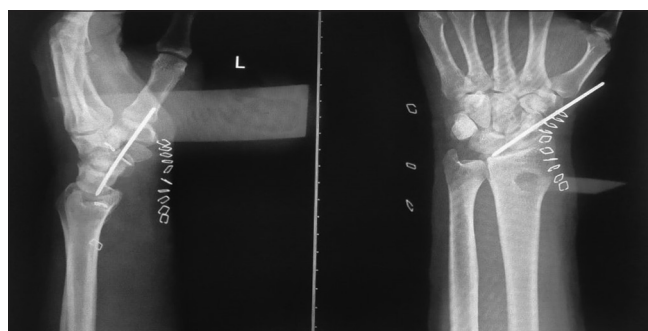
and functional outcome of acute unstable scaphoid fractures treated with primary bone grafting and fixation with K-wire.

## METHODS

A prospective study was carried out at one of the multispecialty hospitals in Northern India. A total of 21 patients of all age groups and of both sexes with acute unstable scaphoid fracture (Herbert type B) were included who had been treated with open reduction, contiguous bone grafting, and fixation with K-wire and were followed up for a minimum of 24 weeks. Patients with Herbert type A, C, or type D scaphoid fracture were excluded from the study. Patients of Herbert type B associated with other fractures on the index limb, neurovascular injury, or those who were unwilling to participate in postoperative rehabilitation or follow-up, were also excluded from the study. A written informed consent was obtained from each subject before the conduct of the study. Fractures were assessed clinically and radiologically with wrist posteroanterior (PA), lateral, and PA with ulnar deviation view and classified according to the Herbert classification. Preoperatively, all patients had been immobilized in below-elbow slab.

The same surgical team performed the surgery by standard volar approach under Bier's block. A hockey-stick incision was made over the distal flexor carpi radialis tendon and angled radially and distally over the thenar eminence at the distal wrist flexion crease. Angling the incision in this direction avoids injury to the palmar sensory branch of the median nerve. Scaphoid was palpated to direct the incision through the volar capsule and directly down onto the volar scaphoid tubercle. Starting distally and cutting proximally, we only released the tissue necessary to expose the fracture. Wrist extension across a towel bump extends the scaphoid offering improved access to the volar scaphoid cortex. Hematoma and soft tissue were gently debrided from the fracture site. Cortico-cancellous bone graft harvested from distal radius, grafted at fracture site, and fixed with 1.5mm K-wire (Fig. 1). A below elbow slab was then applied. At 2 weeks, suture was removed, and a scaphoid cast was molded. At 6 weeks, the cast was taken off and K-wire was removed. X-ray was taken to look for any loss of reduction, graft displacement/subsidence, and assess progress of union. A removable thumb spica splint then applied and home range of motion exercises started. Clinical, functional, and radiographic assessments were performed at 12 and 24 weeks. Resisted or weight-bearing exercise was allowed after fracture union was established.

The patients were assessed clinically by an independent physiotherapist for skin condition and pain at operative site, tenderness at the anatomical snuffbox, Range of Movement (ROM) at the wrist joint, and grip strength. Range of motion and grip strength were assessed by comparing to the normal side. Functional assessment was carried out using Modified Mayo wrist score [9]. Bone union was assessed clinically as the absence of tenderness at the anatomical snuffbox and radiologically by an independent Radiologist as the disappearance of the fracture line with cross-trabeculation across the original fracture on all standard views.



**Fig. 1: Post-operative radiograph showing Fracture Scaphoid managed with ORIF with primary bone grafting and fixed with K wire**

## RESULTS

Twenty-one patients with Herbert type B (Fig. 2) were selected for this study (Table 1), with age ranging from 22 to 41 years and a mean age of 29.6 years. All patients were male. Twelve patients had fracture in the dominant hand, eight had fracture in the non-dominant hand and one patient had fracture in both hands. The mean time from injury to surgery was 11 days (03 days–19 days). The most common causes of injuries were sports injuries in 16 patients, road traffic accidents in 4 patients, and blunt trauma in 1 patient.

The mean operating time was 24 min (range 19–32 minutes). There were no intraoperative complications of surgery or anesthesia. None of the patients required analgesia after 72 h post-surgery. The outcome measurements of pain, tenderness, range of motion, grip strength, and Modified Mayo wrist score were measured at minimum follow-up of 24 weeks (Table 2).

### Clinical outcome

None of the patients had rest pain at first review and all were satisfied at 24 weeks. Seventeen patients regained near-normal ROM and four patients had terminal limitation of movement (One patient had terminal limitation of wrist extension and three patients had terminal limitation of radial deviation) at 12 weeks follow up and remained the same at final follow up. One patient developed painful scar. There were no cases of surgical site infection, median nerve injury or reflex sympathetic dystrophy. Mean grip strength was >0.8 for 15 patients and 0.8 for 6 patients at 12 weeks and comparable to the contralateral hand in 17 patients and >0.8 in 4 patients at 24 weeks.

### Functional outcome

As per Modified Mayo wrist score system, the functional results were good for 17 patients, fair for 4 patients at 12 weeks, became excellent for 15 patients and good for 3 patients and fair for 3 patients at 24 weeks.

### Radiological outcome

At 6 weeks follow up, most of the patients had tenderness in anatomical snuff box. Radiograph suggested consolidating fracture (Fig. 3). None of the patients had loss of reduction, graft displacement/subsidence. Fracture union was achieved in all by the time of the visit at 12 weeks (Fig. 4). There has been no evidence of nonunion or AVN at the latest follow-up. Individuals resumed their routine work 12 weeks post-surgery and by 24 weeks all were comfortable with heavy works/sport activities.

## DISCUSSION

Scaphoid fracture has a bad reputation and with a number of reasons. It is difficult to be diagnosed, it can heal slowly or not heal at all, the healing can be difficult to determine and its non-union can lead to wrist

**Table 1: Age and surgical parameters of study participants**

| Basic parameters    | Frequency | Percentage |
|---------------------|-----------|------------|
| Age group           |           |            |
| 20–25 years         | 3         | 14.28      |
| 26–30 years         | 10        | 47.62      |
| 31–35 years         | 7         | 33.34      |
| 36–40 years         | 1         | 4.76       |
| Side of fracture    |           |            |
| Left side           | 8         | 38.09      |
| Right Side          | 12        | 57.15      |
| Bilateral           | 1         | 4.76       |
| Duration of surgery |           |            |
| <20 min             | 7         | 33.34      |
| 21–25 min           | 6         | 28.57      |
| 26–30 min           | 5         | 23.81      |
| Above 30 min        | 3         | 14.28      |
| Total               | 21        | 100        |

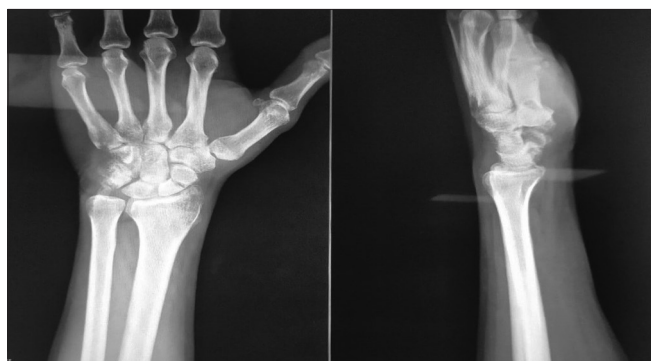

Fig. 2: Pre-operative radiograph of Fracture Scaphoid Herbert type B

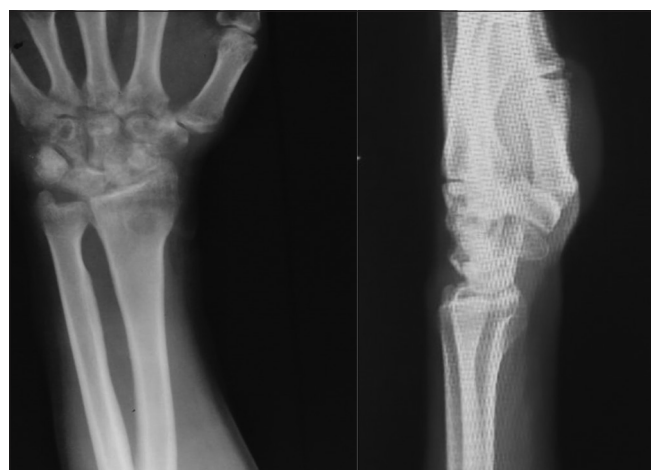

Fig. 3: Radiograph at 6 weeks post-operative after K wire removal showing unition fracture

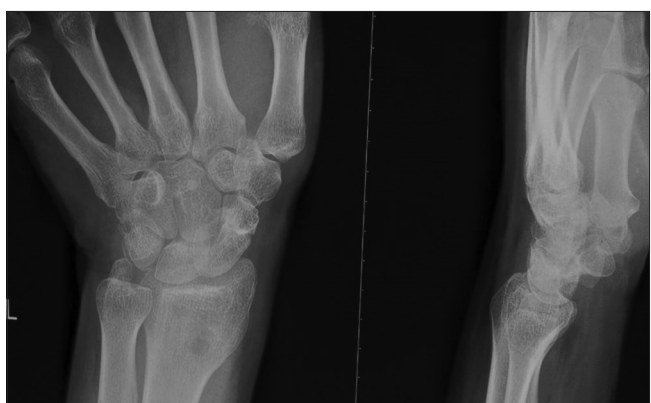

Fig. 4: Radiograph at 12 weeks post-operative showing bony union

arthritis. Previous studies have stressed much upon the necessities of overtreatment of missed scaphoid fractures, proactive fixation of nondisplaced fractures, early but anatomic reduction and stable fixation of unstable fractures, but very little is discussed about the role and results of bone grafting in such situations. Keeping in mind the higher incidence of scaphoid fracture and its complications compounded with its impact on social economy in terms of time off from work and lost productivity, it is needed to explore some adjuvant modality to fasten the bone healing and thereby decreasing the economic burden. On extensive search of literature, we found that the operation method used has not been described at length till now.

Table 2: Details of Clinico-radiological evaluation at 12 weeks and 24 weeks

| Clinico-radiological parameters | 12 weeks  |            | 24 weeks  |            |
|---------------------------------|-----------|------------|-----------|------------|
|                                 | Frequency | Percentage | Frequency | Percentage |
| Tenderness                      |           |            |           |            |
| Present                         | 1         | 4.76       | 0         | 0          |
| Absent                          | 20        | 95.24      | 21        | 100        |
| Range of movement               |           |            |           |            |
| <80%                            | 2         | 9.52       | 0         | 0          |
| 80-90%                          | 2         | 9.52       | 4         | 19.04      |
| 100%                            | 17        | 80.96      | 17        | 80.96      |
| Grip                            |           |            |           |            |
| <80%                            | 6         | 28.57      | 0         | 0          |
| >80%                            | 15        | 71.43      | 21        | 100        |
| Modified moyo score             |           |            |           |            |
| Fair                            | 4         | 19.04      | 3         | 14.28      |
| Good                            | 17        | 80.96      | 3         | 14.28      |
| Excellent                       | 0         | 0          | 15        | 71.44      |
| Radiology                       |           |            |           |            |
| United                          | 21        | 100        | 21        | 100        |
| Non-Union                       | 0         | 0          | 0         | 0          |
| Total                           | 21        | 100        | 21        | 100        |

Internal fixation is indicated for displaced (displacement of the fractured fragments by more than 1 mm in any view) and unstable scaphoid fractures because they have a high risk of delayed union, nonunion, or AVN. Internal fixation shortens the union time and thus early return to work as shown in prospective randomized trial conducted by Bond et al (fracture union approximately 1 month earlier and returned to work 7 weeks earlier than the patients who underwent cast immobilization) [3]. In our study, we found fracture union by 12 weeks and individuals returned to routine work thereafter.

Operative fixation can be obtained by closed or open reduction and fixation by Kirschner wires or compression screws. The technique of percutaneous cannulated screw fixation of nondisplaced or minimally displaced scaphoid fractures has demonstrated promising results in hands of highly experienced surgeons. This technique limits the risk of devascularising fracture fragments and protects the ligaments and volar capsule. However, for percutaneous fixation to be feasible, the fracture must not be displaced or reducible by closed means. Reported union rates seem to be comparable to those with the open technique but complication rates are up to 30% [3]. In our study, the unstable fractures were reduced anatomically by open technique and it took less time. We observed that the technique was so simple and easy that any standard orthopedic surgeon could perform it. The union rate was 100% with minimal complications.

While there is no dearth of literature about bone grafting in the management of nonunion, there is a paucity of literatures regarding the outcomes of additional Bone Grafting of acute unstable fractures. Surgeons in the past have given much importance of stable and anatomic fixation but have exercised very little of bone grafting. Kim *et al.*, in their study in the management of unstable scaphoid nonunion concluded that cancellous bone graft harvested from distal radius were associated with shorter time to union and there was no difference in overall percentage of union, as compared with corticocancellous bone graft harvested from iliac crest [10]. We harvested corticocancellous graft from distal radius which was in the same surgical field, for which no separate anesthesia was required and the donor site was protected in the same scaphoid cast. We achieved better anatomic alignment of fracture and an early union in all patients. None of the patients developed nonunion or AVN.

As far as the fixation device is concerned, the Herbert screw is a rigid fixation device which gives better compression at fracture site and implanted deep into the osteochondral junction, however, screw size and its position should be appropriate as mispositioning can result in

nonunion and its removal is very difficult [3]. Jiang *et al.*, concluded in his study that the union rates and the functional outcomes in terms of Modified Mayo scores, post-op pain and grip strength are indifferent in Herbert screw and K Wire fixation, however, range of motion is even larger in K-wire fixation [11]. The K-wire fixation requires less radiation exposure, easy to operate thus less blood supply was affected during surgery and it is the only possible implant to fix smaller bony fragments [3]. We in our study have observed that K-wire fixation was easy to perform, had better hold for bone graft, required minimal inventory, was cost effective, and its removal was very easy.

The limitations of our study were, that we couldn't directly compare our results because we did not have a control group and since CT scans are far more accurate in assessing the scaphoid union, we had limitation to use only plain radiographs to assess the scaphoid union.

#### CONCLUSION

Primary bone grafting has a definite role in the management of acute unstable scaphoid fracture. The quicker (by 12 weeks) and higher rate (100%) of union with minimal complications was possible just because of biological fixation. Although we encountered painful scar in one (4%) patient and terminal limitation of wrist extension/radial deviation in total of 4 (19%) patients, functionally it did not bother much to them. Open reduction allows thorough assessment of fracture for better anatomic reduction. Although the type of fixation device hardly contributes for quicker and higher union, but then the use of K-wire for fixation is the only viable option for smaller bony fragments and is more forgiving in terms of its positioning. It has an added advantage in terms of requirement of minimal inventory and thus is a cost-effective modality. This procedure also confirms that the patients could get back to their work earlier, hence decreasing economic burden.

#### ACKNOWLEDGMENTS

I acknowledge and thank to all my co-authors, and study participants.

#### AUTHORS CONTRIBUTION

All authors have contributed to preparation of manuscript.

#### CONFLICT OF INTEREST

Nil.

#### AUTHORS FUNDING

Nil.

#### REFERENCES

1. Gaebler C, McQueen MM. Carpus fractures and dislocations. In: Bucholz RW, Court-Brown CM, Heckman JD, Tornetta P, editors. Rockwood and Green's Fractures in Adults. 8<sup>th</sup> ed. Philadelphia, PA: Lippincott Williams and Wilkins; 2015. p. 1008-31.
2. Clementson M, Björkman A, Thomsen NO. Acute scaphoid fractures: Guidelines for diagnosis and treatment. *EFORT Open Rev* 2020;5:96-103.
3. Kawamura K, Chung KC. Treatment of scaphoid fractures and nonunions. *J Hand Surg Am* 2008;33:988-97.
4. Suh N, Grewal R. Controversies and best practices for acute scaphoid fracture management. *J Hand Surg Eur Vol* 2018;43:4-12.
5. Sameh A, Fadl E, Salama K. Percutaneous fixation of acute scaphoid fractures. *Egypt Orthop J* 2013;48:385-38.
6. Rhemrev SJ, Ootes D, Beerens FJ, Meylaerts SA, Schipper IB. Current methods of diagnosis and treatment of scaphoid fractures. *Int J Emerg Med* 2011;4:4.
7. Brogan DM, Moran SL, Shin AY. Outcomes of open reduction and internal fixation of acute proximal pole scaphoid fractures. *Hand* 2015;10:227-32.
8. Khan MA, Akbar BP, Narender RJ, Chinnala SK. Open reduction and fixation of scaphoid fracture with bone grafting to avoid nonunion. *Int J Rec Sci Res* 2017;8:16153-5.
9. Palmer AK. Triangular fibrocartilage complex lesions: A classification. *J Hand Surg Am* 1989;14:594-606.
10. Cheung JP, Tang CY, Fung BK. Current management of acute scaphoid fractures: A review. *Hong Kong Med J* 2014;20:52-8.
11. Jiang Z, Cui J, Gong X, Lu L. Internal fixation with K wire is as efficient as rigid screw fixation in scaphoid fracture: Long term functional outcome. *Acta Orthop Belg* 2018;84:99-104