

ROLE OF ACCESS OSTEOTOMY IN HEAD AND NECK LESIONS – A REVIEW
BHARATHI K^{1*}, MANOJ CHANDRASEKAR², KAPIL DEV KUMAR S³, BALA JAGANNATH GUPTA B⁴

¹Department of Oral and Maxillofacial Surgery, RD Dental Care, Chennai, Tamil Nadu, India. ²Department of Oral and Maxillofacial Surgery, Vinayaka Mission's Sankarachariyar Dental College and Hospital, Salem, Tamil Nadu, India. ³Department of Oral and Maxillofacial Surgery, Southern Railway Headquarters Hospital, Chennai, Tamil Nadu, India. ⁴Department of Oral and Maxillofacial Surgery, Ivory Dental Care, Chennai, Tamil Nadu, India. Email: kirubharathi@gmail.com

Received: 05 October 2021, Revised and Accepted: 12 November 2021

ABSTRACT

The surgical resection of the head and neck lesions summarizes the principles, classifications, applications, complications, and post-operative care of osteotomy with the standard protocols performed safely. It often poses a great surgical challenge due to the anatomical complexity, difficulty in accessibility, and proximity of vital structures. A multidisciplinary approach is often required in these situations for their better exposure to provide surgical access. Access osteotomy is the choice and type for these head and neck lesions, which are most often based on the anatomic extent of the lesion, vascularity of the lesion, and involvement of neurovascular structures in and around it. The literature search using Medline from the year 1986 to 2019 were performed and textbooks were also collected by hand search from the same period. The role of aggressive surgical resection has not been established for malignant head and neck lesions with the technical feasibility and its efficacy for specific tumor types must be defined by the future studies. Thus, we would like to conclude that access osteotomy allows the surgeon a better view and an access of the surgical field to resect the tumor completely with safer margins, preserving the vital structures, pre-operative functions, and reducing post-operative complications.

Keywords: Access osteotomy, Skull base, Head and neck lesions.

© 2022 The Authors. Published by Innovare Academic Sciences Pvt Ltd. This is an open access article under the CC BY license (<http://creativecommons.org/licenses/by/4.0/>) DOI: <http://dx.doi.org/10.22159/ajpcr.2022v15i1.43312>. Journal homepage: <https://innovareacademics.in/journals/index.php/ajpcr>

INTRODUCTION

The optimum access to the site of the head and neck lesion is imperative to allow three-dimensional assessment and resection of the lesion. Various methods have been described, in which access osteotomy has become the gold standard method for head and neck lesions in difficult regions. Access osteotomy was first introduced by Roux in 1836 to improve surgical access and in 1984; Attia *et al.* described the translabial access with mandibular osteotomy anterior to mental foramen, thus preserving the ipsilateral lip sensation [1]. Therefore, it is indicated in areas, where visualization and access are a challenge to remove a lesion in a straight-line access provided the lower incidence of post-operative complications.

METHODS**Classifications**

Access osteotomy in head and neck lesions can be classified as transfacial, transpetrosal, and transcervical surgical approach. There is variety of transfacial approach exposing the skull base through anterior [2], lateral, and medial/midline levels. Transfacial approach exposing the skull base through anterior and lateral [3] has three techniques – frontonasoorbital, frontoorbitozygomatic (FOZ), and nasoorbitomaxillary approach. A modified approach so called maxillary swing is commonly used technique for skull base [4] with lateral involvement of tumors. Transfacial approach exposing the skull base through midline has six levels: Level I – transfrontal, level II – transfrontonasal, level III – transfrontonasoorbital, level IV – transnasomaxillary, level V – transmaxillary, and level VI – transpalatal [5]. Another modular craniofacial operative technique is the approach of skull base based on neurovascular anatomy and esthetic lines for ease of communication and comparison. Thus, it is further divided into:

- a. Minifacial translocation – central
- b. Minifacial translocation – lateral
- c. Standard facial translocation

- d. Extended facial translocation – medial
- e. Extended facial translocation – medial and inferior
- f. Extended facial translocation – posterior
- g. Bilateral facial translocation [6] and transfacial lateral rotation technique described by Hernandez Altemir which gives good access to the retro maxillary area resecting the part of the maxilla [7].

Skull base approach through anterior and lateral*Frontonasoorbital osteotomy*

It is indicated for *en bloc* tumor removal, optic nerve decompression, exposure of the medial aspect of the cavernous sinus, and realignment of the anterior cranial base dura. The patient is positioned in the supine position with the head fixated in neutral. A bicoronal flap is elevated in the subperiosteal plane. The soft tissue is dissected down to the anterior tip of the nasal bone which allows dissection of the intranasal soft tissues through the piriform aperture. Following osteotomy and removal of the frontonasoorbital bone segments, safe resection of tumors located in the angle between the nasal cavity and the medial orbital wall can be performed (Fig. 1). The skull base is reconstructed with repositioning of frontonasoorbital bone segments and fixing of microplates [8].

FOZ osteotomy

It is indicated in complex skull base tumors and vascular pathologies located in the posterior orbit or at the central skull base, interpeduncular fossa, cavernous sinus, and upper clivus [9]. The patient is placed in supine position with elevation of the trunk (25° angulation) and ipsilateral shoulder. A frontal skin flap is elevated and starts within 1 cm anterior to the tragus at the level of the zygomatic arch. Perform two burr holes: One at McArthur's point and the second at the bottom of the temporal squama. Complete frontotemporal craniotomy, including the superior and lateral orbital rim medial to the supraorbital notch and down to the malar eminence (Fig. 2). The dura is closed in a watertight fashion using dura substitutes, to guarantee brain relaxation and to prevent post-operative epidural collection. The FOZ bone flap is replaced and fixed in position with miniplates. If the osteotomy defect is

large, then this can be reconstructed using craniofacial miniplates fixed to the FOZ bone flap. The skin incision is closed in a multilayer fashion leaving a small subgaleal closed drainage system [10].

Nasoorbitomaxillary osteotomy

It is indicated for closing an open nasal vault, mobilization of entire nasal side wall, and straightening the deviated nasal dorsum. A modified Weber-Ferguson incision is placed. The lip splitting and lateral nasal component of the incision are placed opposite the side to which the nose is to be transposed. Osteotomy cuts (Fig. 3) are made so that the piriform aperture margins are included as a rigid base for the transposed nose, which also widens the area of exposure for the transnasal exploration. The lateral nasal osteotomy cuts are made at the right angles to the bone surface. The entire segment is mobilized, pedicled on the cheek, and hinged on the zygomatic bone [11]. The nasoorbitomaxillary bone segments are repositioned and fixed with miniplates.

Maxillary swing

As a surgical technique for exposure of the central skull base, infratemporal fossa, pterygoid base, and nasopharynx [12] Weber-Ferguson incision without gingivolabial component is placed [13]. After deepening the facial incision, the lacrimal sac should be skeletonized and sectioned at its lower end. Infraorbital nerve should be sectioned as it comes out of infraorbital foramen. Periosteum of the inferior orbital wall should be elevated. Osteotomies should be performed on the frontal process of maxilla and at the maxilla-zygomatic suture (Fig. 4). The maxilla-ethmoidal junction should be separated using a straight osteotome. A straight osteotome should be placed between the arms of a V shaped notch located on the

anterior nasal spine and hammered to separate the maxilla down the middle. Now, the whole maxilla with its attached cheek tissue can be swung like a door laterally exposing the whole of nasopharynx. Mass in the nasopharynx can now be removed under direct vision. Maxilla can be repositioned after surgery using miniplate and screws.

Midline skull base approach

Transfrontal osteotomy

It is used to access tumors of the anterior cranial fossa and those that extend into the superior orbital region, typically houses the frontal sinuses to create a flat or tangential view. The patient is positioned in the supine position with the head fixated in neutral with Mayfield clamp. Temporary tarsorrhaphy sutures are placed (5-0 silk) in the eyelids to protect the corneas. A bicoronal scalp incision is used. The bone flap crosses the superior sagittal sinus in two places and must be carefully dissected from the underlying dura to protect the sinus. In older patients with adherent dura, the bone flap can be divided parasagittal to access better the midline and visualize the sinus as it is dissected from the inner table of the calvaria (Fig. 5). The exposure is a wide subfrontal one that leaves the nasal bones in place and gives access to the anterior cranial fossa and cribriform plate but no access into the nasopharynx. After the lesion has been resected, the skull base is reconstructed trying to achieve a watertight separation with local flaps and cranial autografts [14].

Transfrontonasal osteotomy

It is used to expose lesions in the anterior cranial fossa, nasopharynx, clivus, and tumors that extend into the superior, medial, and posterior

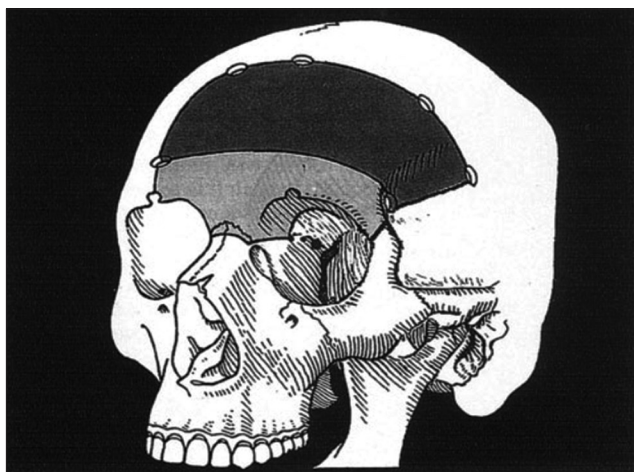


Fig. 1: Frontonasorbital osteotomy

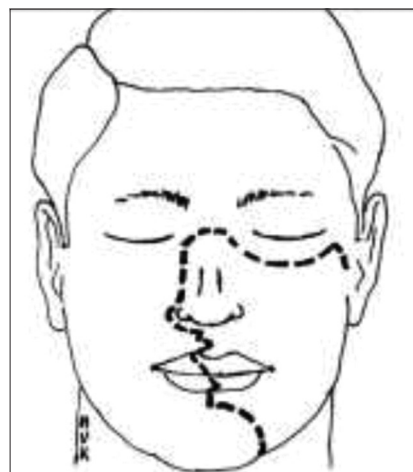


Fig. 3: Nasoorbitomaxillary osteotomy



Fig. 2: Fronto-orbito-zygomatic osteotomy

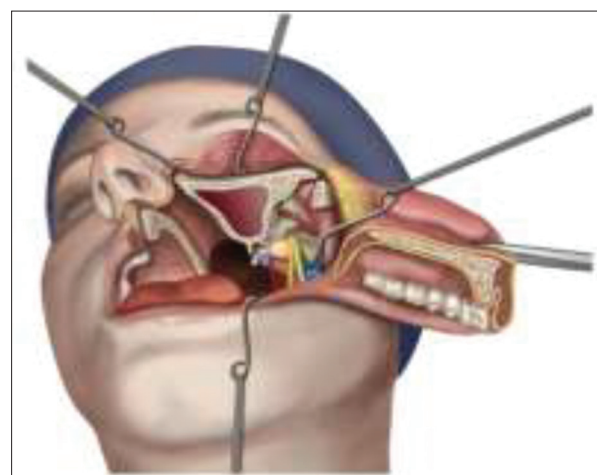


Fig. 4: Maxillary swing

aspects of the orbit. A bicoronal incision is placed far posteriorly to ensure adequate local flaps to reconstruct the skull base. A bifrontal craniotomy and dural dissection are performed. The supraorbital bar with the nasal-orbital complex is osteotomized. An osteotomy across the frontal crest anterior to the crista galli releases the supraorbitonasal bar. Small reconstruction plates are screwed into the bar and bent across the osteotomies and preregistered with screw holes to establish a cosmetic realignment [14]. After the tumor has been resected, the orbitonasal fragment is returned to its anatomic position and rigidly fixed with small plates. The skull base is reconstructed as needed. The upper lateral nasal cartilages are reattached to the nasal bones, and the medial canthal ligaments are repaired by transnasal wiring (Fig. 6).

Transfrontonasoorbital osteotomy

Large anterior cranial fossa lesions, nasopharyngeal lesions, and clival lesions with anterior extension can be accessed. Level III approach is preferred in most cases because of the improved horizontal exposure that is gained. This osteotomy crosses the lateral orbit above the level of the superior margin of the zygomatic arch, extending to the inferior orbital fissure in the region of the inferolateral orbital floor. An additional cut across the posterior lateral orbit is needed that extends from the inferior orbital fissure through the pterion, where it intersects with the lateral frontal osteotomy. The level III frontonasoorbital bar includes the lateral orbital wall from the level of the infraorbital fissure. The globes can then be retracted laterally with ease to widen the horizontal exposure. The most of the superior orbital roof also can be included in the fragment to facilitate the lateral retraction of the globes (Fig. 7). The cuts in the nasal bones are identical to those described with the level II approach.

Transnasomaxillary osteotomy

Wide exposure of the entire central skull base region can be achieved with a Le Fort II osteotomy. This approach can be used for large nasopharyngeal and clival lesions, particularly those that extend in all four directions. A modified Weber-Ferguson incision (Fig. 8) is extended across the radix and along the sub ciliary margin on the lower lid of opposite side. A bilateral buccal sulcus incision is also made. Temporary tarsorrhaphy sutures are placed in the eyelids to protect the corneas.

The periosteum of the maxillary bone is stripped in preparation for a Le Fort II osteotomy. Reconstruction plates are preregistered across the zygomatic buttress, inferior orbital rim, and radix. A plate across the anterior nasal floor stabilizes the maxilla after the palatal split. After tumor resection, reassembly is accomplished with the previously prepared plates and an occlusal interdental splint is fabricated from pre-operative dental models. The splint is left in place for 10–14 days after surgery to add stability to the fixation.

Transmaxillary osteotomy

Small clival lesions with superior, posterior, and inferior extensions and small-to-moderate nasopharyngeal lesions can be accessed through Le Fort I osteotomy with or without a palatal split (Fig. 9). The level V approach has a better cosmetic result because all of the exposure is obtained by degloving the face through the mouth. An intraoral approach is used through an upper buccal sulcus incision. Periosteum is stripped from the maxilla posteriorly to the pterygomaxillary suture, superiorly to the inferior orbital rims, and along the piriform aperture. The anterior maxilla is prepared for a Le Fort I osteotomy. In children, the osteotomy is positioned high, at the level just below the inferior orbital foramen, to avoid the tooth buds. In adults, the osteotomy is positioned above the nasal floor parallel to the occlusive plane. Plates are positioned across the zygomatic buttress and piriform aperture, and screw holes are preregistered. Small tumors may be exposed without requiring a palatal split. If more exposure is needed, the palate can be split in the midline to the back of the soft palate. After tumor resection, reassembly is performed with prepared interdental splints and preregistered fixation plates.

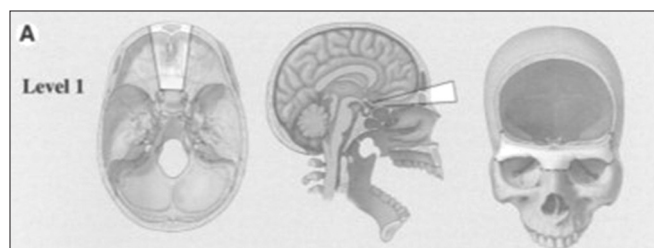


Fig. 5: Transfrontal osteotomy - level I

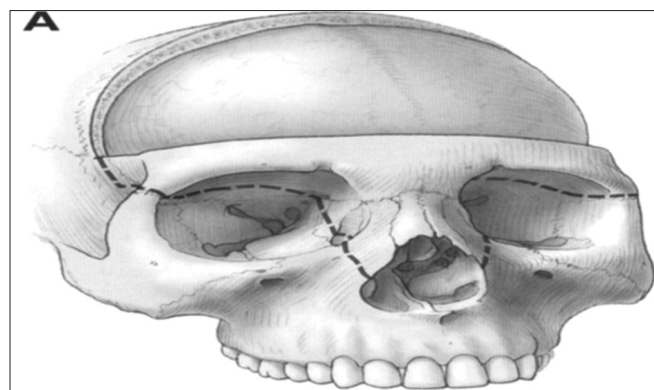


Fig. 6: Transfrontonasal osteotomy - level II

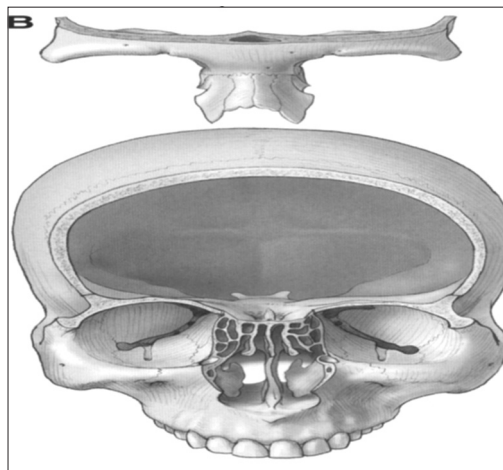


Fig. 7: Transfrontonasoorbital osteotomy - level III

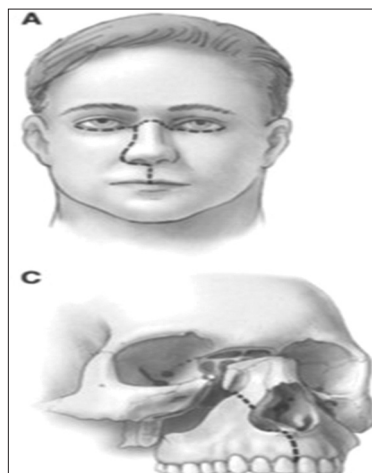


Fig. 8: Transnasomaxillary osteotomy - level IV

Transpalatal osteotomy

The transpalatal approach exposes the lower clival and upper cervical region for resection of small tumors by removing the hard palate and splitting the soft palate. Consequently, the level VI approach is the least invasive, requiring minimal facial disassembly and no facial incision. The palate is approached through the nasal floor and oral mucosa (Fig. 10). An upper buccal sulcus incision is made for the exposure of nasal floor and midline incision is made through the palatal mucosa and soft palate to one side of the uvula. Mucoperiosteal flaps are elevated from the palatal surface to the alveolar margin around the greater palatine foramen to the maxillary tuberosity. The septum is separated from the nasal groove along the nasal floor with guarded osteotomies. Cuts are also made in the lateral nasal wall into the antra with osteotomies. After tumor resection, preregistered microplates on the palatal bone fragment are used for rigid fixation. Screws are placed carefully to avoid the tooth roots. The soft tissues of the soft palate, palatal mucosa, and upper buccal sulcus are closed with absorbable sutures [14].

Modular craniofacial approach

Minifacial translocation - central

It is designed to reach the medial orbit, sphenoid sinus, ethmoid sinus, and inferior clivus for the removal of the tumor. The skin incision is made along the lateral aspect of the nose and the inferior aspect of the eyebrow with triangular design at the level of the medial canthal ligament. Osteotomies create a rectangular pattern with a lateral extent just medial to the inferior orbital nerve. The entire unit is displaced laterally for surgical exposure. Closure is accomplished with replacement of composite unit such as skin, bone, and mucosa. Rigid fixation of the bone is accomplished with microplating (Fig. 11).

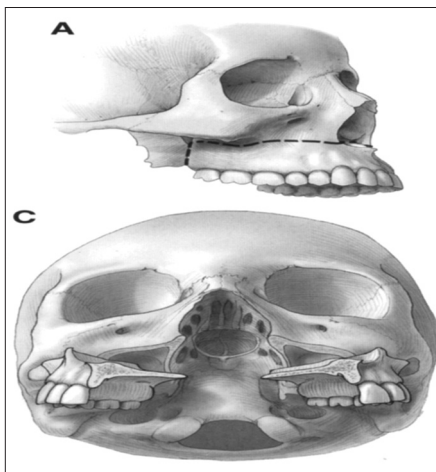


Fig. 9: Transmaxillary osteotomy - level V

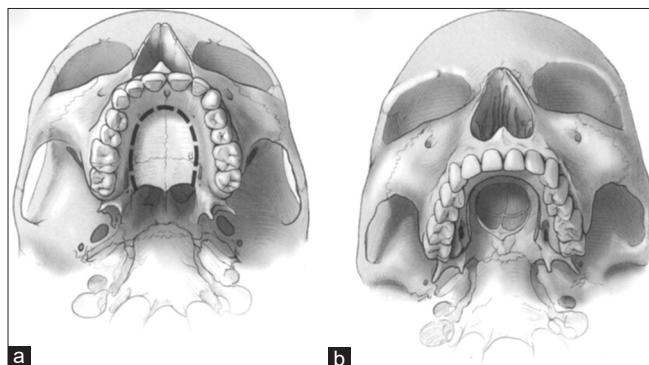


Fig. 10: (a and b) Transpalatal osteotomy - level VI

Minifacial translocation - lateral

It is indicated in the region of infratemporal fossa to access the tumor removal. The incisions run from the inner canthus horizontally in the inferior fornix of the eyelid through the lateral canthus to the preauricular area. Here, it joins vertical temporal and preauricular incision. The frontal branches of the facial nerve are temporarily disconnected. The temporalis muscle is reflected inferiorly after displacement of the zygomatic arch. The head of the mandible may be either displaced or resected (Fig. 12).

Standard facial translocation

It achieves surgical access to the tumor in anterolateral skull base region (Fig. 13). The nasal incision may extend inferiorly to include an upper lip split. Superior incision continues from the nose to the inferior fornix of the lower eyelid and again through the lateral canthus horizontally to the preauricular area. In some cases of anterior tumors, it is possible to conclude the horizontal incision about 1.5 cm beyond the lateral orbital rim after identifying and preserving the anterior frontal branch of the facial nerve. When the entire extent of the horizontal temple incision is needed, the frontal branches of the facial nerve are identified with a nerve stimulator, placed in silicone tubings, and transected. During the reconstruction, these transected tubings are reconnected, and the continuity of the facial nerve branches is re-established. Rigid fixation is achieved with miniplates and microplates.

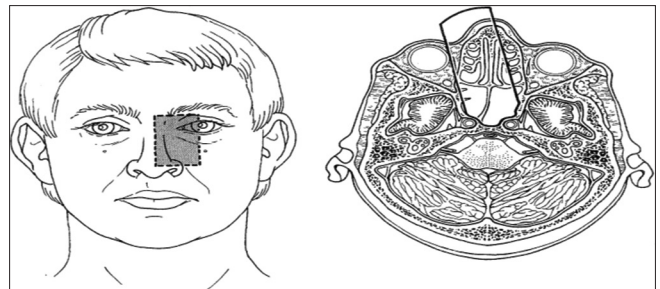


Fig. 11: Minifacial translocation - central

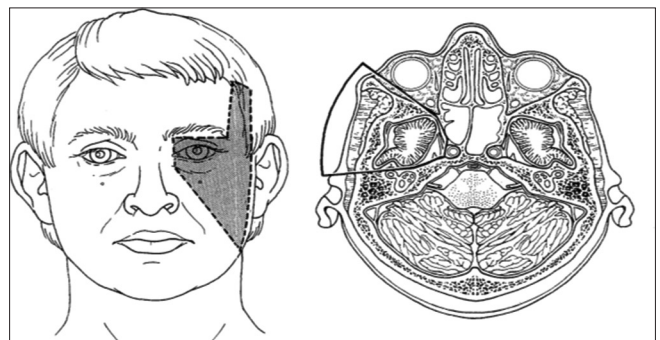


Fig. 12: Minifacial translocation - lateral

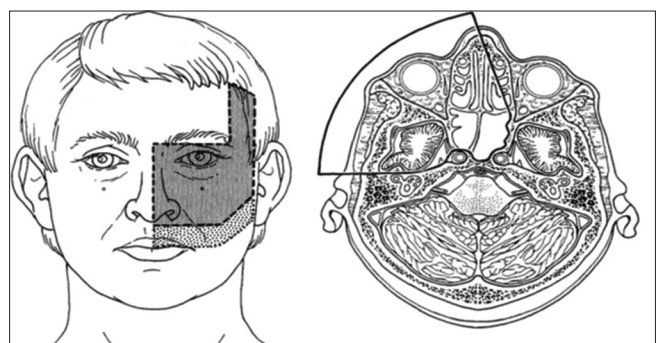


Fig. 13: Standard facial translocation

Extended facial translocation – medial

It incorporates the removal of tumor with the nose and the medial one half of the opposite face (up to the infraorbital nerve). The skin incisions are similar to the standard technique except the paranasal incision is made on the contralateral side. The surgical exposure includes the ipsilateral infratemporal fossa and central and paracentral skull base bilaterally. The wide communication with the infratemporal fossa allows the placement of the temporalis muscle flap for vascularized reconstruction of the skull base defect. Bony fixation of craniofacial osteotomies is done with miniplates and a lag screw for the palate. The occlusal plane is re-established with the help of an orthognathic split. In addition, a palatal splint is attached to the maxillary dentition for additional stability and protection of the palatal incision (Fig. 14).

Extended facial translocation – medial and inferior

It includes tumor access with the inferior extension of extended facial medial translocation through the mandibular split (Fig. 15). The lower lip incision is performed in a zigzag fashion to conform the tension lines of the skin with an extension horizontally into the upper heck. Mandibular osteotomy is performed just medial to the mental foramen in a step fashion, which then permits more stable reconstructive and re-approximation of the bone. This extended translocation procedure adds a significant inferior and upper cervical surgical access.

Extended facial translocation – posterior

It incorporates the ear, temporal bone, and posterior fossa into its surgical access of the tumor. The horizontal temple incision of the standard translocation is extended posteriorly just above the external ear and curve inferiorly over the occipital bone to the neck. This provides access to the anterior and posterior aspects of the temporal bone with control of the key neurovascular structures (Fig. 16).

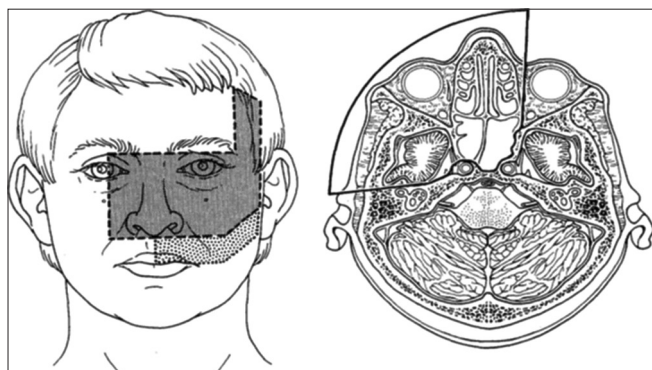


Fig. 14: Extended facial translocation - medial

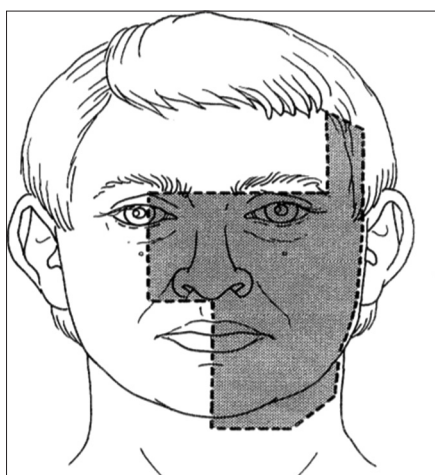


Fig. 15: Extended facial translocation – medial and inferior

After surgical removal, all the structures are re-established and re-approximated.

Bilateral facial translocation

It combines complete right and left basic translocation units with or without palatal split for access of lesions. The exposure incorporates both infratemporal fossae, central, and the entire paracentral skull base. Both distal cervical internal carotid arteries are in view as full clivus. The palatal split permits a reach to the level of C2–C3. If further inferior extension is needed, a mandibular split can be added so that a vertical reach of C3–C4 is accomplished [6]. A single temporalis muscle flap is sufficient for the coverage of the surgical defect at the skull base (Fig. 17).

Complications

The complications can be categorized as neurovascular morbidity, wound complications, and cosmetic defects. Intraoperative navigation with proprioceptive arms, optically tracked probes, or the virtual probes of integrated microscopes is a technology that can enhance the safety of the procedure [15].

Leakage of cerebrospinal fluid (CSF) is the most common of the post-operative complications and is avoided only by meticulous closures in multiple layers of various tissues, regional, and remote. The simplest way to avoid CSF leakage is to leave the dura intact whenever possible. Cribriform plate preservation is one method of maintaining an intact dural barrier. The best means of CSF containment are a complete dural repair, which requires a dural patch, a rim of intact dura around the defect to suture the patch, and room to maneuver the needle holder and sutures. Although material for dural patching is readily available (e.g., bovine pericardium, human dura, fascia Lata, and temporalis fascia), edges to suture and room to suture may not be, in which case soft-tissue flaps or grafts are required. If bone has been resected for the exposure or if the lesion has eroded parts of the fragment, cranial autografts may help reconstruct the bony architecture. All patients receive antibiotic prophylaxis before, during, and 3 days after surgery with intravenous cefuroxime or ceftriaxone. When the risk of CSF leakage is considered high, prophylactic post-operative lumbar spinal drains are placed for a minimum of 3 days, with CSF outputs titrated to 10 mL/h. When leaks do not respond to these conservative measures, re-exploration

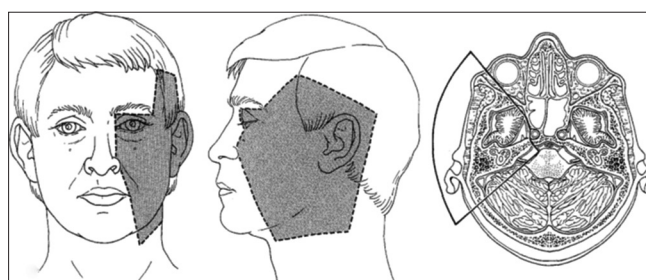


Fig. 16: Extended facial translocation – posterior

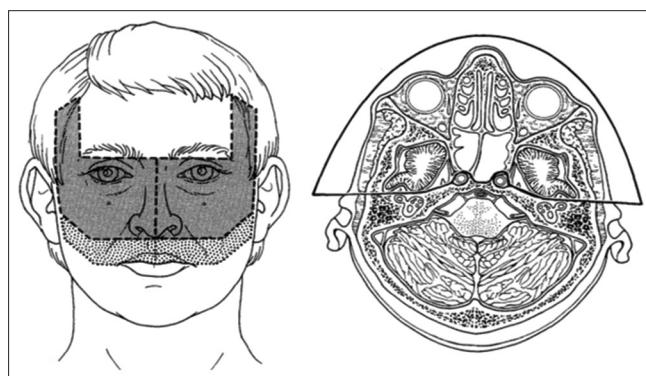


Fig. 17: Bilateral facial translocation

is required. Wound infections that do not respond to antibiotics also require re-exploration.

The final category of complications relates to cosmesis, which is often the patient's greatest concern. Perhaps, the most important technique to improve cosmesis after transfacial surgery is the preregistration of fixation plates before the osteotomies are made. Lines are drawn on the facial bones with a sterilized pencil, which enables plates to be contoured and screw holes to be set before osteotomy cuts are made. With the transmaxillary approaches, malocclusions can be troublesome problems that could require orthodontic treatment or secondary surgical correction. Patients are prepared before surgery with dental impressions for the fabrication of moulds and interdental splints. These splints are placed intraoperatively and left in place for 10–14 days which allow restoration of normal occlusion without the need for mandibular arch bars.

Post-operative care

- Neuromonitoring – intensive care for first few days of surgery
- Airway for patients who have experienced disruption of the nasolacrimal drainage system
- Extensive humidification of the air is necessary to reduce dryness, crusting, and bleeding in case of surgery involved in nasal and paranasal sinuses
- Pulmonary care for prevention of pneumonia and routine prophylaxis for deep vein thrombosis are used while the patient is still confined to bed and early ambulation is not feasible. Once the patient is able to sit up, gradual progressive ambulation is encouraged, with the goal of having the patient fully ambulatory by the 5th–7th post-operative day
- When the surgical intervention involves the masticator space or temporomandibular joint, the development of trismus is a risk. Initially, trismus develops because of a spasm of the muscles of mastication resulting from post-operative pain and discomfort. Mechanical devices for prevention and/or improvement of trismus are available and should be used when indicated.

DISCUSSION

The present underlying principle of skull base approaches is to minimize brain retraction and maximize skull base visualization. This concept facilitates three-dimensional tumor resection, tumor margin verification, and functional reconstruction with appropriate esthetic concerns. The advantages of these surgical approaches are:

1. Presenting optimal lines of “separation” of facial units for a surgical approach, permitting the least traumatic displacement
2. The primary blood supply to the “facial units” is through the external carotid system, which also has a lateral-to-medial direction of flow, thus ensuring viability of displaced surgical units
3. The midface contains multiple “hollow” anatomic spaces facilitate the relative ease of surgical access to the central skull base
4. Displacement of facial units for an approach to the cranial base offers much greater tolerance to post-operative surgical swelling, as opposed to similar displacement of the content of the neurocranium [6].

It also has certain disadvantages such as the following:

1. Contamination of the surgical wound with oropharyngeal bacterial flora
2. The need for facial incisions with subsequent scar development
3. Emotional considerations for the patient related to “surgical facial

disassembly”

4. The potential need for post-operative endotracheal intubation and temporary tracheostomy management.

CONCLUSION

Many craniofacial techniques have been in use to improve access to the skull base, infratemporal and parapharyngeal region. Improved access to the pathology should be achieved with minimal brain retraction. The procedure should facilitate protection of the brain and adjacent neurovascular structure. Patient specific osteotomy approach needs to be carried out based on the site, size, type of tumor, adjacent anatomical structure, and anticipated complication. Therefore, an improved visualization at the skull base is complemented by functional and esthetic reconstruction.

CONFLICT OF INTEREST AND AUTHORS FUNDING

The authors report no conflict of interest related to this study and no external funding apart from the support of all the authors was available for this study.

REFERENCES

1. Singh M, Bhattacharya A. Access osteotomy for tumors of the oropharyngeal region a review. *Univ J Dent Sci* 2016;1:75-9.
2. Sree Ramaneni SK, Kattimani VS. Orbito-rhino-antro access osteotomy for anterior skull base lesions. *J Clin Diagn Res* 2014;8:19-21.
3. Beals SP, Joganic EF, Spetzler RF. Classification of transfacial approaches in treatment of tumors of the anterior skull base and clivus. *Plast Surg Forum* 1993;16:211-3.
4. Janecka IP, Sen C, Sekhar LN, Arriaga M. Facial translocation: A new approach to the cranial base. *Otolaryngol Head Neck Surg* 1990;103:413-9.
5. Lawton MT, Hamilton MG, Beals SP. Radical resection of anterior skull base and cavernous sinus lesions. *Clin Neurosurg* 1995;42:43-70.
6. Janecka IP. Classification of facial translocation approach to the skull base. *Otolaryngology Head Neck Surg* 1995;112:579-85.
7. Altamir FH. Transfacial access to the retro maxillary area. *J Maxillofac Surg* 1986;14:165-70.
8. Zoeller JE, Mischkowski RA, Behr R, Ernestus RI, Speder B. The fronto-orbital osteotomy as plastic-reconstructive approach to the anterior and middle skull base. *J Craniomaxillofac Surg* 2001;29:159-64.
9. Kaanan IN. Fronto-orbito zygomatico approach. In: *Neurovascular Surgery Surgical Approaches for Neurovascular Disease*. 1st ed. Tangerang, Indonesia. Springer; 2019. p. 17-22.
10. Zabramski JM, Kiris T, Sankhla SK, Cabiol J, Spetzler RF. Orbitozygomatic craniotomy: Technical note. *J Neurosurg* 1998;89:336-41.
11. Paul C Sallns. The trans naso-orbitomaxillary approach to the anterior and middle skull base. *Int J Oral Maxillofac Surg* 1998;27:53-7.
12. Wei WI, Ho CM, Yuen PW, Fung CF, Sham JS, Lam KH. Maxillary approach for resection of tumors in and around the nasopharynx. *Arch Otolaryngol Head Neck Surg* 1995;121:638-42.
13. Singh CA, Hota A, Gupta MP, Yadav V, Jat B. Suprastructure maxillary swing for JNA: A novel approach to avoid complication. *Otorhinolaryngol Clin* 2016;8:26-8.
14. Lawton MT, Beals SP, Joganic EE, Han PE, Spetzler RE. The transfacial approaches to midline skull base lesions: A classification scheme. *Oper Tech Neurosurg* 1999;2:201-17.
15. Lawton MT, Golfinos JG, Geldmacher TR. The state of the art of frameless neuronavigation with frameless stereotaxy in intracranial neurosurgery. *Oper Tech Neurosurg* 1998;1:27-38.