

SPECTRUM OF CT FINDINGS IN CLINICALLY SUSPECTED CASES OF MUCORMYCOSIS – A STUDY AT TERTIARY HEALTH-CARE CENTER (RAJINDRA HOSPITAL PATIALA) DURING SECOND WAVE OF COVID PANDEMIC

SIMMI BHATNAGAR¹, AMITA KUMARI^{1*}, ISHITA GUPTA¹, VISHAV YADAV², MANPREET³

¹Department of Radiodiagnosis, Government Medical College and Rajindra Hospital, Patiala, Punjab, India. ²Department of ENT, Government Medical College and Rajindra Hospital, Patiala, Punjab, India. ³MBBS, Gian Sagar Medical College, Banur, Rajpura, Punjab, India. Email: raj_neuro_raj@yahoo.in

Received: 19 December 2021, Revised and Accepted: 05 March 2022

ABSTRACT

Objective: Rhinocerebral mucormycosis is an acute, fulminant, and often lethal opportunistic infection typically affecting diabetic or immunocompromised patients. Early diagnosis is vital in these infections because delay in initiation of the treatment can be life-threatening. Computed tomography (CT) with axial and coronal sections is a highly accurate and non-invasive modality to accurately image sinonasal mycosis. The aim of the study was to describe the imaging findings in suspected cases of mucormycosis on CT.

Methods: This study was conducted in Radiodiagnosis Department of Rajindra Hospital, Patiala. The data of 22 patients who were referred for CT with a clinical suspicion of mucormycosis were collected and all these patients were followed up to know about the prognosis of the disease.

Results: In our study, there were 54.60% females and 45.40% males. Maximum number of patients (45.45%) belonged to 40–49 year age group. Diabetes mellitus was found to be the most commonly (90.90%) found comorbidity followed by hypertension (36.36%). In our study, involvement of unilateral nasal cavity was observed in 36.36% cases. Among the paranasal sinuses, maxillary and ethmoid sinuses were the most commonly involved in 95.45% and 77.27% cases.

Conclusion: Prompt diagnosis and treatment of rhino-orbital mucormycosis are the sine qua non as antifungal drugs and surgical debridement can successfully control the infection and thus reduce the high mortality and morbidity associated with mucormycosis.

Keywords: COVID status, Sinonasal mycosis, Rhinocerebral mucormycosis, Comorbidity, Cavernous sinus thrombosis, Computed tomography.

© 2022 The Authors. Published by Innovare Academic Sciences Pvt Ltd. This is an open access article under the CC BY license (<http://creativecommons.org/licenses/by/4.0/>) DOI: <http://dx.doi.org/10.22159/ajpcr.2022v15i5.43928>. Journal homepage: <https://innovareacademics.in/journals/index.php/ajpcr>

INTRODUCTION

Rhinocerebral mucormycosis is an acute, fulminant, and often lethal opportunistic infection typically affecting diabetic or immunocompromised patients. It is caused by one of the members of the mucoraceal family, including *Absidia*, *Mucor*, and *Rhizopus* [1]. Clinically, presenting symptoms are non-specific including headache, low-grade fever, facial swelling, and orbital or paranasal sinus syndrome. After infecting nose and paranasal sinuses (PNS), the fungi cause a necrotizing vasculitis that extends rapidly into deep face, orbits, cranial cavity, and brain through skull base foramina. It is difficult to diagnose early, as patients often present with non-specific symptoms. By the time signs of orbital apex involvement develop, it is often too late to save the patient's vision or even the patient's eye or life [2]. Early diagnosis is vital in these infections because delay in initiation of the treatment can be life-threatening. Computed tomography (CT) with axial and coronal sections is a highly accurate and non-invasive modality to accurately image sinonasal mycosis [3].

Aim

The aim of the study was to describe the imaging findings in suspected cases of mucormycosis on CT.

MATERIALS AND METHODS

Study design

This was an observational and cross-sectional study.

Sample size

A total of 22 patients who were referred for imaging to Department of Radiodiagnosis with clinical suspicion of mucormycosis were included in the study.

Ethical approval

Institutional Ethical Committee, Government Medical College, Patiala W.R.T. Letter number EC/NEW/INST/2020/997.

Study period

The duration of the study was from May to August 2021.

Inclusion criteria

All the patients who were positive for fungal hyphae on KOH mount were included in the study. Out of these, 17 were consistent with mucormycosis (demonstration of broad and aseptate ribbon like fungal hyphae) on KOH mount/histopathological examination. Record for tissue characteristics of five patients was not available.

Exclusion criteria

Pregnant females and children were excluded from the study.

Data collection

Data of all the patients referred for CT to Department of Radiodiagnosis who were clinically suspected for mucormycosis and had KOH mount positive for fungal hyphae were included in the study. Complete record of the history of COVID infection and associated comorbidities if any was collected. Non-contrast CT and/or Contrast-enhanced CT of PNS were performed on GE REVOLUTION 128 slice CT scanner with a slice thickness of 5mm. Additional sections for orbits and brain were taken depending on the findings. In cases of CECT, intravenous contrast was injected after taking relevant history of any allergic reaction, assessing the renal functions and taking informed consent from the patient. The sinuses showing opacification on CT were recorded in each case. On post-contrast CT, the type of contrast enhancement and involvement of any extra sinus structures including orbits, face, infratemporal fossa, and cavernous

sinus was noted. Presence of bone involvement along with vascular complications was noted. The patients were followed up to know about the prognosis of the disease.

Data analysis

The data were described in terms of range, frequencies (number of cases), and relative frequencies (percentages) as appropriate.

RESULTS

Gender

In our study, there were 54.60% females and 45.40% males (Table 1).

Age

Maximum number of patients (45.45%) belonged to 40–49 year age group and minimum number of patients (9.09%) belonged to 30–39 year age group (Table 2).

COVID status

At the time of radiological examination, 17 (77.27%) patients were either COVID positive or COVID recovered, whereas 5 (22.73%) patients were COVID negative by laboratory investigations (Table 3).

Comorbidity

Diabetes mellitus was found to be the most commonly (90.90%) found comorbidity followed by hypertension (36.36%) (Table 4).

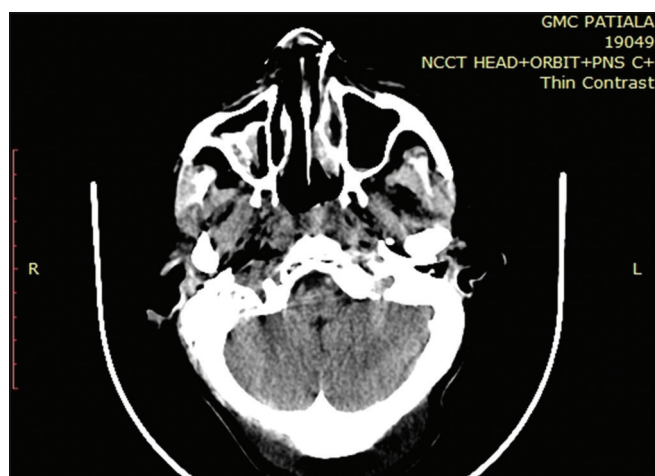

Fig. 1: Non-contrast computed tomography paranasal sinuses demonstrates soft-tissue density material with hyperdense contents within partly opacifying right maxillary sinus

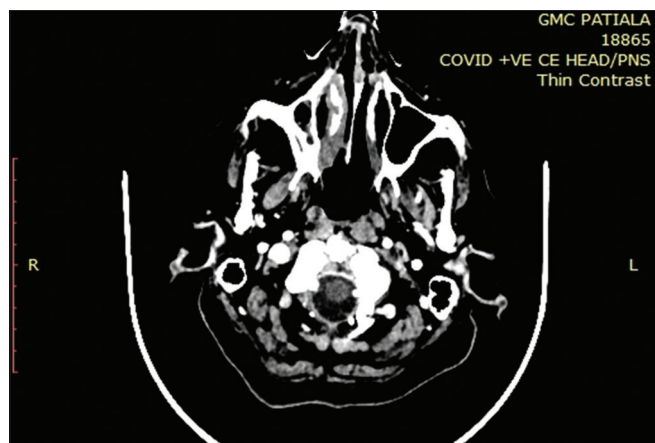


Fig. 2: Contrast-enhanced computed tomography paranasal sinuses demonstrates soft-tissue density material partially opacifying right nasal cavity and right maxillary sinus

Nasal cavity and PNS

In our study, involvement of unilateral nasal cavity was observed in 36.36% cases (Figs. 1 and 2). No case of bilateral disease was seen. Among the PNS, maxillary and ethmoid sinuses were the most commonly involved in 95.45% and 77.27% cases (Table 5).

Orbit

In orbital involvement, soft-tissue thickening involving preseptal region was seen in 6 (27.27%) patients, out of which preantral extension was noted in 2 (9.09%) patients (Fig. 3). Associated proptosis was also noted in 1 (4.54%) case (Figs. 4 and 5). Out of the involved extraocular muscles, unilateral medial rectus was most commonly involved in 9 (40.90%) patients (Table 6).

Deep soft-tissue infiltration

Fungal sinusitis was seen to involve predominantly posterior periantral region in half of the cases. In our study, pterygopalatine fossa and infratemporal fossa involvement was seen in 6 (27.27%) and 4 (18.18%) cases (Table 7).

Intracranial involvement

In our study, rarefaction of greater wing of the left sphenoid bone was observed in 1 (4.54%) case without any associated intracranial involvement. Erosion of anterior skull base (cribriform plate) was observed in 1 (4.54%) case with peripherally enhancing intracerebral abscess involving bilateral frontal lobes. The left cavernous sinus was found prominent in the same case (Fig. 6). Thinning and erosion of floor of sphenoid sinus were found in

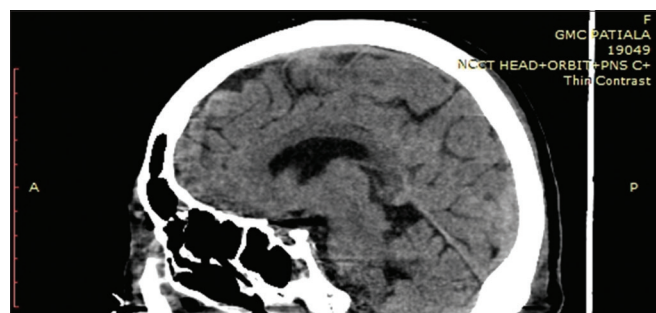


Fig. 3: Non-contrast computed tomography showing soft-tissue thickening and fat stranding in the left preseptal space extending inferiorly till the anterior periantral region. Also, soft-tissue density material is seen partly opacifying sphenoid sinus

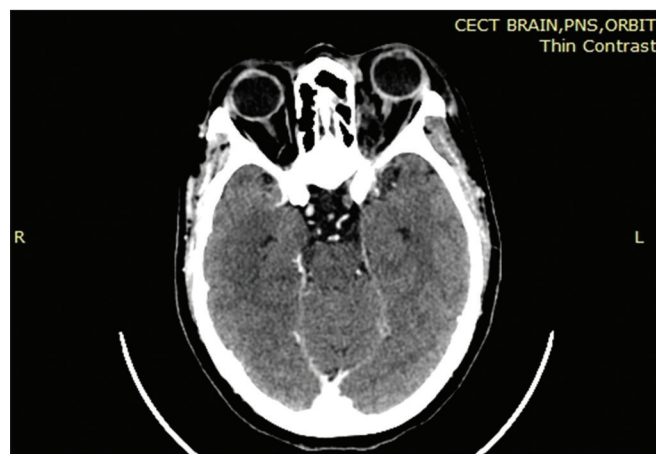


Fig. 4: Contrast-enhanced computed tomography showing hypodense filling defect in cavernous segment of the left internal carotid artery suggesting thrombus. Fat stranding is also noted in medial orbital fat on the left side. The left medial rectus appears bulky with soft-tissue thickening

1 (4.54%) case without any intracranial extension. Non-enhancing hypodense area involving gray and white matter was noted in the right medial basifrontal region in one of the patients with probable diagnosis of early cerebritis. Nasal swab of this patient was positive for Mucor like hyphae and the patient was found to have died on follow-up (Table 8).

Outcome

On follow-up of all the patients, four patients were found to have died before any surgery could be performed. However, two patients survived after initiation of antifungal treatment. On the basis of imaging, 16 patients were operated (majority of them being operated at ENT department of our institution and few at PGI Chandigarh after being referred). About 75.00% (12 patients) of the operated patients survived whereas 25.00% (4 patients) died (Table 9).

Table 1: Distribution of cases as per gender

Gender	n (%)
Males	10 (45.40)
Females	12 (54.60)
Total	22 (100.00)

Table 2: Distribution of cases as per age

Age group (years)	n (%)
30-39	2 (9.09)
40-49	10 (45.45)
50-59	7 (31.81)
≥60	3 (13.63)
Total	22 (100.00)

Table 3: Distribution of cases as per COVID status

COVID status	n (%)
Positive (COVID/Post-COVID)	17 (77.27)
Negative	5 (22.73)
Total	22 (100.00)

Table 4: Distribution of cases as per comorbidity

Comorbidity	n (%)
Diabetes mellitus	20 (90.90)
Hypertension	8 (36.36)
HCV	2 (9.09)
HIV	1 (4.54)
Pulmonary Koch's	1 (4.54)
Hypothyroidism	1 (4.54)
Anemia	1 (4.54)
None	2 (9.09)

HCV: Hepatitis C virus

Table 5: Distribution of cases according to the involvement of nasal cavity and paranasal sinuses

Site	Unilateral, n (%)	Bilateral, n (%)	Total, n (%)
Nasal cavity			
Soft tissue	8 (36.36)	0	8 (36.36)
Bony	5 (27.70)	0	5 (27.70)
Frontal sinus	8 (36.36)	8 (36.36)	16 (72.72)
Maxillary sinus			
Soft tissue	14 (63.60)	7 (31.80)	21 (95.45)
Bony	7 (31.80)	0	7 (31.80)
Ethmoid sinus	8 (36.36)	9 (40.90)	17 (77.27)
Sphenoid sinus	4 (18.18)	12 (54.54)	16 (72.72)

DISCUSSION

In our study, maximum number of patients (45.45%) belonged to 40-49 year age group and minimum number of patients (9.09%) belonged to 30-39 year age group. Similarly, in a study on COVID-19-associated rhino-orbital-cerebral Mucormycosis conducted by Dubey *et al.* in 2021, mean age of subjects was 53±10.28 years [4].

Diabetes mellitus was found to be the most commonly (90.90%) found comorbidity followed by hypertension (36.36%). Similarly, Prakash *et al.* in 2021 reported uncontrolled diabetes mellitus to be the most common underlying disease associated with mucormycosis in India [5]. A recent multicenter study from India reported that 77% of rhino-ocular-cerebral mucormycosis cases were in the diabetic population [6]. In a study conducted by El-Kholy *et al.* in 2019 on invasive fungal sinusitis in post-COVID-19 patients, the most common associated disease was found to be diabetes mellitus (27.8%) and hypertension (16.67%) [7].

In our study, involvement of unilateral nasal cavity was observed in 36.36% cases. Among the PNS, maxillary and ethmoid sinuses were the most commonly involved in 95.45% and 77.27% cases. In a study by El-Kholy *et al.* in 2021, the most commonly involved sinonasal site was found to be lateral nasal wall (86.1%) with ethmoid (72.2%) and sphenoid (55.6%) sinuses being the most commonly affected sinuses [7]. Similarly, in the study by Dubey *et al.*, imaging of sinuses revealed nasal cavity (55 subjects, 100%), maxillary sinus (52, 94.5%) and ethmoidal sinus (52, 94.5%) involvement as most common [4].

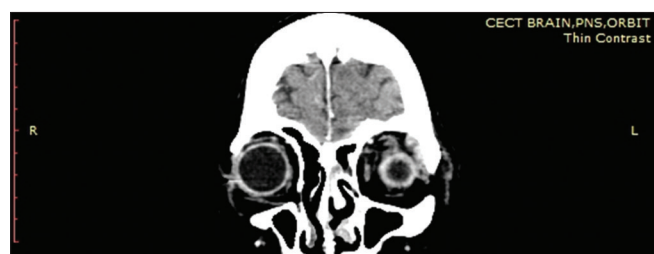

Fig. 5: Contrast-enhanced computed tomography showing bulky left Superior and medial recti with adjacent soft-tissue thickening

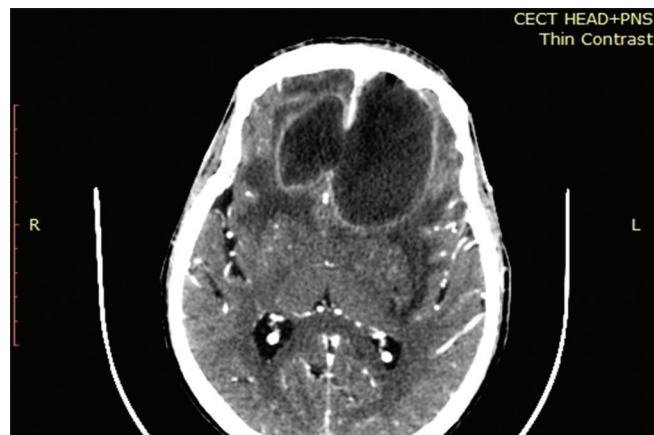

Fig. 6: On contrast-enhanced computed tomography brain, there is seen a large well defined, bilobed, peripherally enhancing hypodense lesion (MAV ~5-14 HU) ms ~6.4 cm (T)×6.4 cm (AP) × 4.5 cm (CC) with air foci within in bilateral frontal region showing extension across the midline. There is seen extensive surrounding perilesional edema in bilateral frontal lobes and bilateral ganglio-capsular region. Positive mass effect is seen in the form of effacement of overlying sulcal spaces, compression of bilateral frontal horns and body of bilateral lateral ventricles

Table 6: Distribution of cases based on involvement of different orbital contents

Site	Unilateral, n (%)	Bilateral, n (%)
Nasolacrimal duct	5 (22.72)	0
Soft tissue/fat stranding		
Medial/inferior orbital fat/	7 (31.81)	0
Extra/intraconal soft tissue	8 (36.36)	1 (4.54)
Preseptal soft tissue	6 (27.27)	0
Orbital apex	5 (22.72)	0
Optic nerve		
Bony canal	3 (13.63)	0
Soft tissue thickening	2 (9.09)	0
Superior orbital fissure	3 (13.63)	0
Bony orbital erosion	8 (36.36)	0
Extraocular muscles		
Superior rectus	2 (9.09)	0
Inferior rectus	4 (18.18)	0
Medial rectus	9 (40.90)	0
Lateral rectus	2 (9.09)	0
Superior oblique	4 (18.18)	0

Table 7: Distribution of cases based on soft-tissue infiltration in periantral region/pterygopalatine fossa/infratemporal fossa

Site	n (%)
Anterior periantral fat	9 (40.90)
Posterior periantral fat	11 (50.00)
Pterygopalatine fossa	6 (27.27)
Infratemporal fossa	4 (18.18)

Table 8: Distribution of cases based on cranial and intracranial involvement

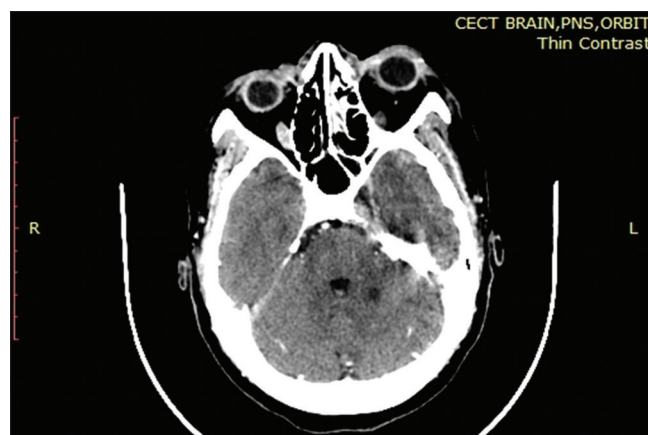Site	n (%)
Cranial (skull base erosion)	3 (13.63)
Parenchymal	2 (9.09)
Vascular	
Intracranial ICA	1 (4.54)
Cavernous sinus	3 (13.63)

ICA: Internal carotid artery

Table 9: Distribution of cases on the basis of outcome

Operative status	Survived, n (%)	Not survived, n (%)
Operated	12 (75.00)	2 (33.33)
Not operated	4 (25.00)	4 (66.67)
Total	16	6

Among orbital involvement, orbital wall invasion was seen in 8 (36.36%) patients. Among the extraocular muscles, the most commonly involved was medial rectus in 9 (40.90%) cases. Our results were in concordance with study conducted by Dubey *et al.*, in which orbit showed 33 subjects (60%) with orbital wall invasion (breach in lamina papyracea/medial wall of orbit) and 29 subjects (52.73%) had extraocular muscles involvement either in combination or in isolation. Among extraocular muscles, involvement of medial rectus was most commonly observed in 27 subjects (49.09%) followed by inferior rectus involvement in 26 cases (47.27%). Orbital soft-tissue involvement was observed in 30 subjects (54.55%). Orbital apex was invaded by mucormycosis in 23 (41.81%) cases and 10% had bilateral involvement. Medial rectus and inferior rectus involvement with other extraocular muscles was most commonly found. The possible route map of Mucor spreads, being self-explanatory as Mucor finds its way into retro-orbital space through breach of lamina papyracea to involve medial rectus first which lies in close proximity of medial wall of orbit [4].

**Fig. 7: Contrast-enhanced computed tomography demonstrating enlarged left cavernous sinus with filling defect**

In our study, pterygopalatine fossa and infratemporal fossa involvement was seen in 6 (27.27%) and 4 (18.18%) cases. In the study conducted by intensity, changes were obvious in pterygopalatine fossa and infratemporal fossa unilaterally in 39 subjects (70.91%) and bilaterally in 18% [4].

Mazzai *et al.* stated that the anterior cranial fossa is a typical localization of rhinocerebral mucormycosis intracranial complications. Invasion of anterior cranial fossa by bony erosion or perineural spread through the cribriform plate can cause adjacent cerebritis before the development of a cerebral abscess [8]. Cavernous sinus involvement was seen in 3 (13.63%) cases in our study (Figs. 4 and 7). Similar results were seen in study by Dubey *et al.*, in which cavernous sinus involvement was reported in 15 subjects (27.27%) and was bilateral in 8% [4].

CONCLUSION

Imaging plays a key role in the early identification of rhino-orbital mucormycosis and delineating the extent of infection. Prompt diagnosis and treatment of rhino-orbital mucormycosis are the sine qua non as antifungal drugs and surgical debridement can successfully control the infection and thus reduce the high mortality and morbidity associated with mucormycosis. Thus, early diagnosis and prompt operative intervention could be done and hence improving the prognosis.

LIMITATIONS OF THE STUDY

The only limitation of the study was a small sample size. A larger population cohort is desirable to achieve more accurate results.

AUTHOR CONTRIBUTION

All authors contributed equally to the conduct of study and preparation of manuscript.

CONFLICT OF INTEREST

None.

FUNDING

None.

REFERENCES

- Herrera DA, Dublin AB, Ormsby EL, Aminpour S, Howell LP. Imaging findings of rhinocerebral mucormycosis. *Skull Base* 2009;19:117-25. doi: 10.1055/s-0028-1096209.
- Kauh CY, Nelson CC. Diagnosis and management of orbital mucormycosis. *Ophthalmic Pearls (Oculoplastics)*. *Am acad ophthalmol: EyeNet*. 2014;37-9.
- Alam A, Chander BN, Sabhikhi GS, Bhatia M. Sinonasal mucormycosis:

- Diagnosis using computed tomography. Med J Armed Forces India 2003;59:243-5. doi: 10.1016/S0377-1237(03)80018-7, PMID 27407526
4. Dubey S, Mukherjee D, Sarkar P, Mukhopadhyay P, Barman D, Bandopadhyay M, *et al.* COVID-19 associated rhino-orbital-cerebral mucormycosis: An observational study from Eastern India, with special emphasis on neurological spectrum. Diabetes Metab Syndr 2021;15:102267. doi: 10.1016/j.dsx.2021.102267
 5. Prakash H, Chakrabarti A. Epidemiology of mucormycosis in India. Microorganisms 2021;9:523. doi: 10.3390/microorganisms9030523, PMID 33806386
 6. Patel A, Kaur H, Xess I, Michael JS, Savio J, Rudramurthy S, *et al.* A multi-centre observational study on the epidemiology, risk factors, management and outcomes of mucormycosis in India. Clin Microbiol Infect 2020;26:944.e9-15. doi: 10.1016/j.cmi.2019.11.021
 7. El-Kholy NA, El-Fattah AM, Khafagy YW. Invasive fungal sinusitis in post COVID-19 patients: A new clinical entity. Laryngoscope 2021;131:2652-8. doi: 10.1002/lary.29632, PMID 34009676
 8. Mazzai L, Anglani M, Giraud C, Martucci M, Cester G, Causin F. Imaging features of rhinocerebralmucormycosis: From onset to vascular complications. Acta Radiol 2021;63:232-44..