

A COMPARATIVE STUDY OF LATERALIZED TRANSVERSE INCISION APPENDECTOMY VERSUS LAPAROSCOPIC APPENDECTOMY

ABHISHEK MAHNA*

Assistant Professor, Department of General Surgery, Adesh Medical College and Hospital, Shahbad, Haryana, India. Email: abhimahna87@gmail.com

Received: 26 February 2022, Revised and Accepted: 29 March 2022

ABSTRACT

Objectives: The objective of this study were to compare the effectiveness of lateral transverse cosmetic incision (LTCI) versus laparoscopic appendectomy in terms of operative and post-operative parameters.

Methods: One hundred and forty patients who were admitted after the diagnosis of appendicitis were divided into two groups of 70 each. Patients in Group A were treated by lateralized transverse incision appendectomy, while Group B patients underwent laparoscopic appendectomy.

Results: In the present study, male: female ratio was found to be 2:1 with majority of the patients belonging to age group of 21–50 years (75.72%). Post-operative hospital stay in Group A patients was 2 ± 0.68 days in comparison to 2 ± 0.75 days in laparoscopy group which was comparable. Duration of surgery in minutes in Group A was 46 ± 18.65 while in Group B, it was 91 ± 17.75 with a significant $P \leq 0.0001$. The cost of surgery was Rs.3200±450 in LTCI, while it was Rs.4200±600 in laparoscopic group with $P < 0.0001$ which was found to be highly significant.

Conclusion: Lateral transverse incision appendectomy was found to be as effective as laparoscopic appendectomy. The method is a preferred procedure, particularly in those set ups where the advanced equipments and specially trained doctors and technicians are not available. In the present study, lateral transverse technique was found to be safe, cosmetically much better, and without mortality and negligible morbidity. Furthermore, less hospital stay, less need for analgesics, less need for skilled personnel, early return to the routine, less surgery duration, and less expensive as compared to laparoscopic surgery make the conventional method equally preferable.

Keywords: Appendectomy, Lateral transverse incision, Laparoscopic appendectomy, McBurney's point.

© 2022 The Authors. Published by Innovare Academic Sciences Pvt Ltd. This is an open access article under the CC BY license (<http://creativecommons.org/licenses/by/4.0/>) DOI: <http://dx.doi.org/10.22159/ajpcr.2022v15i5.44534>. Journal homepage: <https://innovareacademics.in/journals/index.php/ajpcr>

INTRODUCTION

Acute appendicitis is the most common acute surgical conditions encountered in abdominal region and mostly affects young adults. A complete examination of the abdominal region is necessary for diagnosing the condition and accordingly planning the ideal treatment [1]. The diagnosis of acute appendicitis is predominantly a clinical one as many patients present with a classic history. The cause of acute appendicitis is unknown, but many factors such as luminal obstruction, dietary habits, and familial factors have been noted as its etiological factors [1,2]. Approximately 7% of the population suffers from appendicitis at some point in their life [3]. Acute appendicitis may be seen in any age group, but most commonly affects second and third decades of life [4]. Prompt diagnosis and surgical treatment helps in reducing the risk of perforation and preventing further complications [5]. The mortality rate in cases of non-perforated appendicitis is <1%, but it may be seen as high as 5% if there is a delay in diagnosis. Pre-operative diagnosis of acute appendicitis presents as challenge in young women, children and elderly despite the availability of various diagnostic modalities [6]. Delay in diagnosis leads to complication, leading to higher chances of morbidity. In today's world, minimal scarring is preferred by the young patients who are in the profession of dancing, modeling, and those and sports. A part from cosmetic reasons, small transverse incision is less painful, enables early mobility, and has lesser morbidity than the standard incision. Even though laparoscopic appendectomy procedure has similar advantages, it is not feasible to adopt this technique at all health centers due to limitation in availability of experts, set ups in facility, and cost of procedure. This cosmetic incision offers better results postoperatively and avoids requirement of expertise, infrastructure for laparoscopy, thus reducing cost [6]. Hence, this study was conducted to compare the effectiveness of lateral transverse cosmetic incision (LTCI) versus laparoscopic appendectomy in 140 patients

diagnosed with appendicitis in Department of General Surgery in a Medical College from 2019 to 2020.

Various techniques have been used and modified over decades to provide the best results. These include elective method which uses various incisions such as gridiron incision, lanz's transverse incision, paramedian incision, Rutherford morrison's incision, and battles'spara rectal incision. In case of lateral transverse incision appendectomy, a small transverse incision of about 2.5–3 cm is given in the right lower abdomen just on lateral border of rectus muscle which is retracted medially and extended to Mc Burney's point. Minimal scar formation is the hallmark of this technique [7-10]. Laparoscopy is mainly a diagnostic tool, particularly in females. The technique, however, requires a number of equipments as well as skilled and trained members thus making it costlier [11].

Aims and objectives of the study

The study was conducted to compare the effectiveness of LTCI in comparison to laparoscopic appendectomy.

METHODS

Between the period of 2019 and 2020, 140 patients who were diagnosed with appendicitis in the Department of General Surgery were included in the study. An informed consent was taken from the patients after explaining the procedures and the purpose of the study. The patients were divided into two groups of 70 each. The patients in Group A were treated by appendectomy through lateral transverse incision, while the patients belonging to Group B underwent Appendectomy by laparoscopic procedure. The primary parameters for this study were as follows:

1. Age group
2. Sex prevalence

Table 1: Age distribution

Age	Number	Percentage
11-20	14	10.00
21-30	41	29.29
31-40	40	28.57
41-50	25	17.8
51-60	16	11.43
61-70	2	1.43

3. Duration of the surgery
4. Cost of the surgery
5. Post-operative hospital stay

Inclusion criteria

All patients attending the surgical OPD or admitted in surgery ward with established diagnosis of appendicitis after subjecting them to all the necessary investigations.

Exclusion criteria

Patients excluded from the study were those who had complicated appendicitis, secondary systemic illnesses, and those who had obesity.

RESULTS

The above parameters were evaluated for both the groups and following results were found:

Age distribution

In the present study, the age of patients ranged from 14 to 62 years. About 75.72% of the patients were in the age group of 21-50 years and about 10-12% below and above it, as shown below (Table 1).

Sex distribution

About two-third of the patients were male in the present study resulting in male: female ratio of 2:1.

Duration of surgery

The average duration of surgery was significantly longer for laparoscopic appendectomy as compared to the lateral incision group (91 min vs. 46 min, $P < 0.0001$) (Graph 1).

Post-operative stay

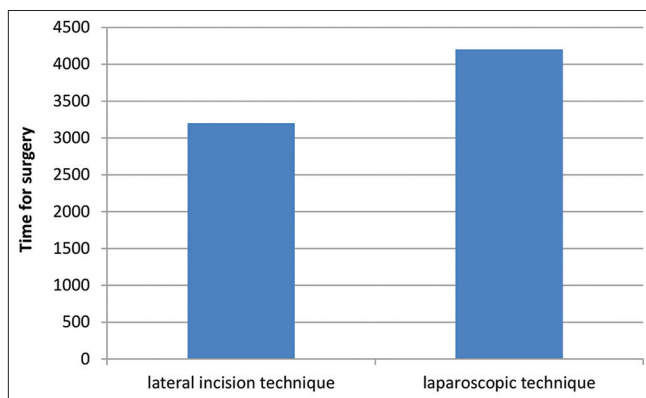
Post-operative stay was almost same in both groups, of about 3 days (Graph 2).

Cost of surgery

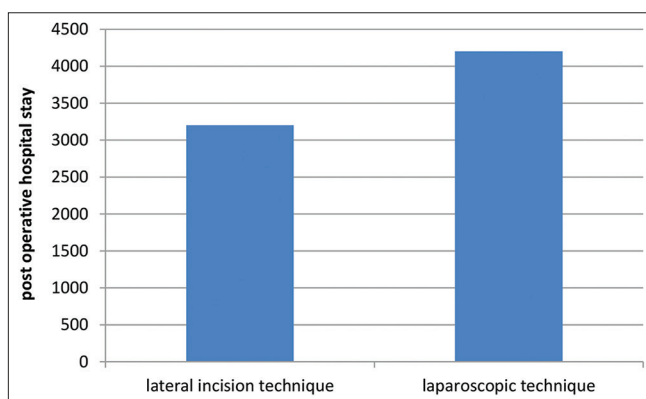
Laparoscopic appendectomy was significantly costlier than LTCI appendectomy (Rs.4200 vs. Rs.3200), when cost was calculated using same medicines for both the groups. The difference was mainly due to the higher cost of general anesthesia required for laparoscopic appendectomy and the higher operative charges for laparoscopic appendectomy (Graph 3).

DISCUSSION

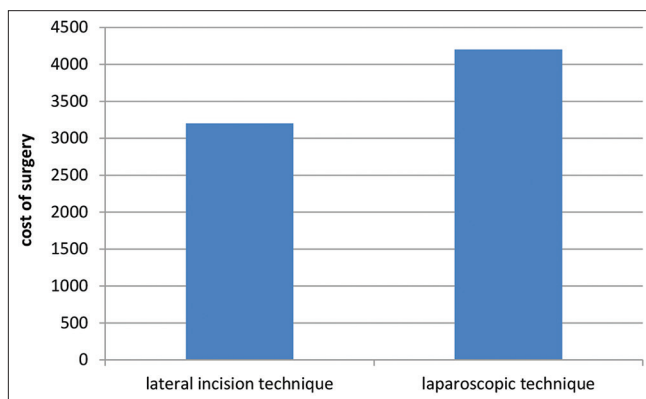
In this study, majority of patients were male (male: female ratio was 2:1) with 67.86 of patients being males and 32.14 being females. This was comparable to the study done by Malik *et al* [10]. In our study, 75% patients were in the age group 21-50 years, which are comparable to the observation made by Das and Roy in their study. Laparoscopic appendectomy consumed longer duration compared to LTCI in our study. The average time duration of laparoscopic versus LTCI being 91 min versus 46 min, respectively, with P value of which is highly significant. This is comparable with study done by Shasin *et al*. Post-operative stay is comparable in patients undergoing LTCI and laparoscopic procedure, that is, 3 ± 0.75 and 3 ± 0.68 days. Cost of surgery is significantly reduced in LTCI compared to laparoscopic procedure with values being $Rs.3200 \pm 450$ versus $Rs.4200 \pm 600$, respectively, which is comparable to study done by Shashin *et al*. [4,6,7,9].



Graph 1: Comparison of duration of surgery



Graph 2: Comparison of post-operative stay



Graph 3: Comparison of cost of surgery

CONCLUSION

Appendicitis in any age group requires surgical intervention at the earliest after establishing the proper diagnosis. However, in the health care centers where laparoscopic set up and skilled workforce is unavailable, this conventional lateral transverse incision appendectomy is equally effective as laparoscopic appendectomy. In the present study, lateral transverse incision technique is quiet safe and esthetically acceptable and has no mortality and negligible morbidity [12,13]. Furthermore, this technique has shown to decrease the hospital stay of the patient, less requirement of analgesics postoperatively, minimal requirement of specially trained personnel, early return to the normal life, less duration of surgery, and cheaper in comparison to laparoscopic surgery.

AUTHORS FUNDING

None as the study was carried out on patients admitted through diagnosis in OPD in medical college.

CONFLICTS OF INTEREST

None.

REFERENCES

1. Berry J, Malt RA. Appendicitis near its centenary. *Ann Surg* 1984;200:567-75. doi: 10.1097 / 00000658-198411000-00002, PMID 6385879
2. Lru CD, Mcfadden DW. Acute abdomen and appendix. In: *Surgery: Scientific Principles and Practice*. 2nd ed. Philadelphia: Lippincott – Raven; 1997. p. 126.
3. Addis DG, Shaffer N, Fowler BS, Tauxe RV. The epidemiology of appendicitis and appendectomy in the United States. *Am J Epidemiol* 1990;132:910-25.
4. Das S. *A Concise Textbook of Surgery*. 5th ed. Kolkata: SD Publications; 2009. p. 1023.
5. Wilnox RT, Traver LW. Have the evaluation and treatment of acute appendicitis changed with new technology? *Surg Clin North Am* 1997;77:1355-70.
6. Shasin SK, Dhar S. Mini-appendectomy (An experience of 100 cases). *JK Pract* 2005;12:11-3.
7. Ramirez JM, Dews J. Practical Score to a decision making in doubtful cases of acute appendicitis. *BJS* 1994;23:680-3.
8. Rintoul RF. Operation on the appendix. In: Farquharson M, Moron B, editors. *Text Book of Operative General Surgery*. 8th ed. London: Churchill Livingstone; 1995. p. 452-4.
9. Jelarko C, Davis L. A transverse lower abdominal appendectomy incision with minimal derangements. *Surg Gynecol Obstet* 1973;136:451-3.
10. Malik AH, Wani RA, Saima BD and Wani MY. Small lateral access—an alternative approach to appendicitis in paediatric patients: A randomised controlled trial. *International Journal of Surgery* 2007;5:234-8.
11. Scott-Conner CE. Laparoscopic gastrointestinal surgery. *Med Clin North Am* 2002;86:1401-22. doi: 10.1016/s0025-7125(02)00081-0, PMID 12510458
12. Skandalakis JE, Gray SU, Reckett SR. The colon and rectum. In: Grays W, Skandalakis JE, editors. *Embryology for Surgeons*. Baltimore: Williams and Wilkins; 1994. p. 242-81.
13. Cooperman M. Complications of appendectomy. *Surg Clin North Am* 1983;63:1233-47. doi: 10.1016/s0039-6109(16)43185-3, PMID 6359499