

A STUDY ON RETINOPATHY OF PREMATURETY BY REVIEW OF RISK FACTORS THROUGH SCREENING IN TERTIARY EYE CARE HOSPITAL

GURIVINDAPALLI PREMALATHA, CHIRUMAMILLA RAMYA, GUTTI SATYAVATHI, REDDI SANTHOSHA NIKHILA*

Department of Ophthalmology, Government Regional eye hospital, Visakhapatnam, Andhra Pradesh, India. Email: reddinikhila@gmail.com

Received: 27 May 2022, Revised and Accepted: 1 July 2022

ABSTRACT

Objectives: Retinopathy of prematurity (ROP) is a vasoproliferative disease that affects premature infants. The purpose of the study is to identify various maternal and fetal risk factors for ROP and to categorize the premature babies according to severity of disease and associated risk factors.

Methods: This is a cross sectional study conducted on 100 infants from May 2021 to August 2021. Examination was done by a single ophthalmologist specialized to screen the babies. It was done 4 weeks after the birth and Detailed history included the birthweight, gestational age, the postnatal problems, obstetric history were obtained. Pupillary dilatation was done with a mixture of 2.5% phenylephrine and 1% tropicamide. 0.5% proparacaine is used for topical anesthesia. An infantile lid speculum was used to separate the lids. Fundus was examined with binocular indirect ophthalmoscope and +20D condensing lens.

Results: Prematurity and low birth weight are the most common and important risk factors. Most of the babies had symmetrical disease (88%) and zone 3 is most commonly involved (67%). Apart from prematurity and low birthweight, respiratory distress syndrome with oxygen supplementation was common association (56%). Various maternal risk factors were found to be common associations like pre eclampsia (33%) and gestational diabetes (22%).

Conclusion: ROP is associated with several maternal and fetal risk factors. Early detection by screening of the premature babies can prevent blinding complication. Inadvertent and generous oxygen administration must be stopped due to its high association with ROP. All the premature babies must be screened 4 weeks after gestation for the earliest detection of the disease with an ophthalmologist specialized in that field with regular followups and prompt intervention as soon as the disease is identified.

Keywords: Retinopathy of prematurity, Risk factors, Prematurity.

© 2022 The Authors. Published by Innovare Academic Sciences Pvt Ltd. This is an open access article under the CC BY license (<http://creativecommons.org/licenses/by/4.0/>) DOI: <http://dx.doi.org/10.22159/ajpcr.2022v15i10.45355>. Journal homepage: <https://innovareacademics.in/journals/index.php/ajpcr>

INTRODUCTION

Retinopathy of prematurity (ROP) is a vasoproliferative disease that affects premature infants. ROP is on a rise in India as a result of the improved neonatal care and better neonatal survival rate [1]. Identifying and screening of at-risk premature infants performed by an experienced ophthalmologist remains the most important strategy in the management of ROP. It is characterized by initial hyperoxic state with cessation of growth of existing retinal vessels followed by pathological hypoxia induced outgrowth of new vessels [2]. Low birth weight (≤ 1500 g), prematurity (≤ 32 weeks) are the most important risk factors [3]. Several maternal and fetal risk factors can lead to ROP [4].

Maternal risk factors

Multiple gestation, premature rupture of membranes, preeclampsia, eclampsia, gestational diabetes, placenta previa, antenatal infections and antenatal steroid injections [5].

Fetal risk factors

Prematurity, low birth weight, oxygen supplementation, blood transfusion, sepsis, necrotizing enterocolitis, Hypoxic ischemic encephalopathy, respiratory distress syndrome (RDS), hyperbilirubinemia, intraventricular hemorrhage [6].

Aim of the study

To identify several maternal and fetal risk factors associated with ROP by screening in a tertiary eye care hospital.

Objectives

1. To identify various maternal and fetal risk factors for ROP

2. To categorize the premature babies according to severity of disease and associated risk factors.

METHODS

A cross sectional study of 100 infants who were screened according to Indian guidelines (gestational age ≤ 34 weeks, birth weight ≤ 2000 grams) done between May 2021 and August 2021.

Examination was done by a single ophthalmologist specialized to screen the babies.

It was done 4 weeks after the birth and Detailed history included the birthweight, gestational age, the postnatal problems, obstetric history were obtained.

Pupillary dilatation was done with a mixture of 2.5% phenylephrine and 1% tropicamide. 0.5% proparacaine is used for topical anesthesia.

An infantile lid speculum was used to separate the lids. Fundus was examined with binocular indirect ophthalmoscope and +20D condensing lens.

Inclusion criteria

All the babies with gestational age less than or equal to 34 weeks and birth weight ≤ 2000 grams.

Exclusion criteria

All the babies with gestational age more than 34 weeks and birth weight more than 2000 grams.

RESULTS

Out of 100 babies, males were 59% and females were 41%. Out of 100, 36 babies with ROP and 64 without ROP. Out of 36, 32 (88%) were with symmetrical disease and 4 (12%) were with asymmetrical disease (Fig. 1). Out of 36, 4 (11%) babies had Zone 1 ROP, 8 (22%) had Zone 2 ROP, 24 (67%) had Zone 3 ROP (Table 1) (Fig. 2). From Table 2, it shows 10 (28%) are in stage 1, 18 (50%) are in stage 2, 6 (17%) in

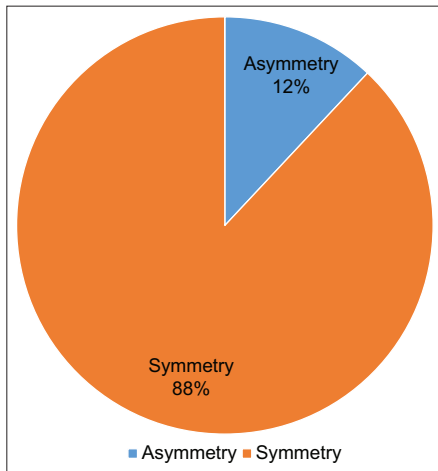


Fig. 1: Symmetry

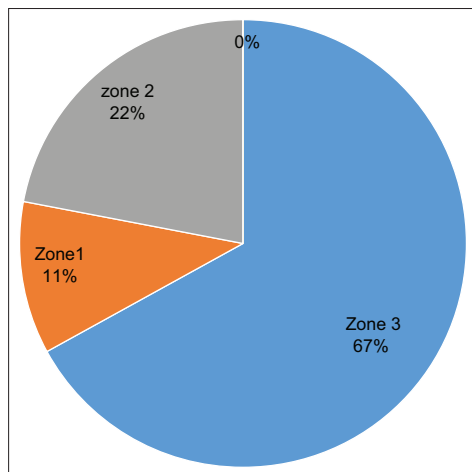


Fig. 2: Zones of ROP

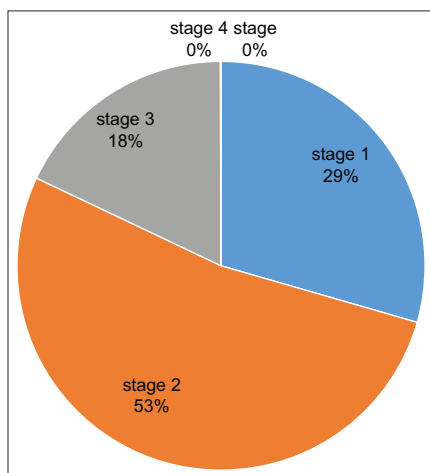


Fig. 3: Stages of ROP

stage 3, 2 (0.06%) in stage 4, and stage 5, 0 (Fig. 3). Table 3 shows out of 100 babies, 10 (10%) had history of blood transfusion and 50 (50%) had history of oxygen administration. RDS is found to be common association among fetal risk factors (Table 4). Among the maternal risk factors, preeclampsia is most common association (Table 5). Babies with plus disease were 12 (33%) and without plus disease 24 (66.6%) (Fig. 4).

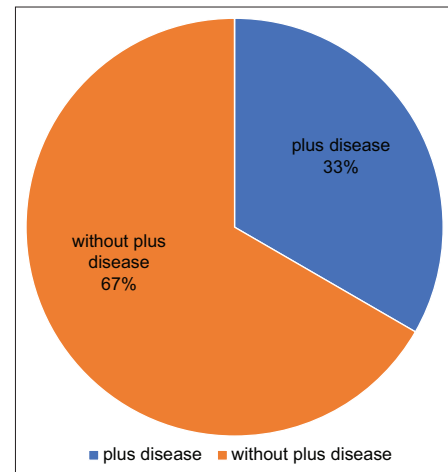


Fig. 4: Plus disease

Table 1: Zones OF ROP

Zones OF ROP	Zone 1	Zone 2	Zone 3
Number and %	4 (11%)	8 (22%)	24 (67%)

ROP: Retinopathy of prematurity

Table 2: Stages of ROP

Stage of ROP	1	2	3	4	5
Number and %	10 (28%)	18 (50%)	6 (17%)	2 (0.06%)	0

ROP: Retinopathy of prematurity

Table 3: History

History	Blood transfusion	Oxygen administration
Total babies (100)	10 (10%)	50 (50%)

Table 4: Fetal risk factors

Fetal risk factors	Number and %
HIE	8 (22%)
NEC	6 (17%)
Anemia	8 (22%)
Sepsis	10 (28%)
Hyperbilirubinemia	6 (17%)
RDS	20 (56%)

RDS: Respiratory distress syndrome, HIE: Hypoxic ischemic encephalopathy, NEC: Necrotizing enterocolitis

Table 5: Maternal risk factors

Maternal risk factors	Number and %
Multiple gestation	6 (17%)
Premature rupture of membranes	8 (22%)
Pre eclampsia	11 (33%)
Eclampsia	6 (17%)
Gestational diabetes	8 (22%)
Antenatal infections	4 (11%)

DISCUSSION

With improving scientific advances and technological understanding the incidence of ROP is rapidly rising. The constant urge to make premature babies survive with oxygen administration and blood transfusions has led to increase ROP cases. Prematurity and low birth weight are the most common and important risk factors. Of the total 100 babies screened 36 babies (36%) have ROP and in study by L. Gopal *et al* incidence was found to be 38% and it was 44% in a study by Eduardo Goncalves *et al*. Most of the babies had symmetrical disease (88%) and zone 3 is most commonly involved (67%). Apart from prematurity and low birth weight, RDS with oxygen supplementation was common association (56%). Various maternal risk factors were found to be common associations like pre-eclampsia (33%) and gestational diabetes (22%).

CONCLUSION

ROP is associated with several maternal and fetal risk factors. Early detection by screening of the premature babies can prevent blinding complications. As the Zone 1 is rarely involved this disease carries a favourable outcome. Inadvertent and generous oxygen administration must be stopped due to its high association with ROP. All the premature babies must be screened 4 weeks after gestation for the earliest detection of the disease with an ophthalmologist specialized in that field with regular follow ups and prompt intervention as soon as the disease is identified.

AUTHORS CONTRIBUTION

Gurivindapalli Premalatha, Assistant professor in department of Ophthalmology and full time Retina specialist in Government Regional Eye Hospital, Visakhapatnam, diagnosed the cases of ROP and analyzed the reports of the patients.

Chirumamilla Ramya, Postgraduate in department of Ophthalmology, Government Regional Eye Hospital, Visakhapatnam, analyzed them, thereby framing the final outcome of the study, along with the other authors.

Gutti Satyavathi, Associate professor in department of Ophthalmology, Government Regional Eye Hospital, Visakhapatnam, aided in diagnosing the cases along with the other authors.

Reddi Santhosha Nikhila, Postgraduate in department of Ophthalmology, Government Regional Eye Hospital, Visakhapatnam, aided in collecting the cases along with the other authors.

CONFLICTS OF INTEREST

The authors declared no conflicts of interest.

AUTHORS FUNDING

The study was not supported by any grants and funds.

REFERENCES

1. Heath P. Pathology of the retinopathy of prematurity: retrolental fibroplasia. *Am J Ophthalmol.* 1951;34(9):1249-59. doi: 10.1016/0002-9394(51)91859-4, PMID 14877946.
2. Fierson WM. American Academy of Pediatrics Section on Ophthalmology. Screening examination of premature infants for retinopathy of prematurity. *Pediatr.* 2018 Dec 1;142(6):e20183061.
3. Kumar P, Sankar MJ, Deorari A, Azad R, Chandra P, Agarwal R, *et al*. Risk factors for severe retinopathy of prematurity in preterm low birth weight neonates. *Ind J Pedi.* 2011 Jul 1;78(7):812-6.
4. Le C, Basani LB, Zurakowski D, Ayyala RS, Agraharam SG. Retinopathy of prematurity: incidence, prevalence, risk factors, and outcomes at a tertiary care center in Telangana. *J Clin Ophthalmol Res.* 2016 Sep 1;4(3):119.
5. Chaudhari S, Patwardhan V, Vaidya U, Kadam S, Kamat A. Retinopathy of prematurity in a tertiary care center—incidence, risk factors and outcome. *Indian Pediatr.* 2009 Mar 1;46(3):219-24. PMID 19179740.
6. Vinekar A, Dogra MR, Sangtam T, Narang A, Gupta A. Retinopathy of prematurity in Asian Indian babies weighing greater than 1250 grams at birth: ten year data from a tertiary care center in a developing country. *Ind J Ophthalmol.* 2007 Sep. 2007;55(5):331-6. doi: 10.4103/0301-4738.33817, PMID 17699940.