

## AN ASSESSMENT OF PLEUROPULMONARY POST-TUBERCULOSIS PATIENTS IN A TEACHING HOSPITAL IN EAST INDIA

SANTU KUMAR SAMANTA, APARUP DHUA\*, MUKUL CHAKRABORTY, PRANAB MANDAL

Department of Chest Medicine, Midnapore Medical College, Paschim Medinipur, West Bengal, India. Email: docaparup@gmail.com

Received: 25 June 2022, Revised and Accepted: 02 July 2022

### ABSTRACT

**Objectives:** Quality of life of a patient may be impaired seriously in the aftermath of pleuropulmonary tuberculosis (TB) even after being cured or taking adequate treatment. Proper evaluation of post-TB sequelae is of extreme clinical importance. The study objective was to assess demographic, clinical, radiological, and spirometric pattern of pleuropulmonary post-TB patients in a teaching hospital.

**Methods:** An observational cross-sectional study was carried out in a teaching hospital in India over a period of 14 months. A total of 300 patients of more than 12 years of age from both genders were included in the study. Detailed history, clinical, radiological, microbiological, and spirometric evaluation were being carried out.

**Results:** It was a male predominant study with male: female ratio of 2.29:1 and mean age of patient was  $52.97 \pm 0.51$  (mean  $\pm$  standard error of mean) years. History of pleural and pulmonary TB was present in 11% and 89% of cases, respectively. Cough was present in all patients. Shortness of breath (86.33%) and hemoptysis (58.33%) were among other common presenting symptoms. In majority of cases, pulmonary involvement was unilateral (57%). Pleural fibrosis/thickening was seen in 11% of cases, lung parenchymal fibrosis 38.67%, bronchiectasis in 12.67%, and aspergilloma found in 7% of cases. Bacteriological positivity was detected in 14.33% of cases. Spirometric evaluation revealed restrictive pattern (50.20%) in most of the cases followed by obstructive pattern in 38.13% of cases.

**Conclusion:** Respiratory symptoms, radiological, and spirometric abnormalities can present among pleuropulmonary post-TB patients as a sequelae. It may be considered as an important cause of chronic lung disease, particularly in high TB burden countries.

**Keywords:** Post-tuberculosis sequelae, Post-tuberculosis lung disease, Post-tuberculosis airway disease.

© 2022 The Authors. Published by Innovare Academic Sciences Pvt Ltd. This is an open access article under the CC BY license (<http://creativecommons.org/licenses/by/4.0/>) DOI: <http://dx.doi.org/10.22159/ajpcr.2022v15i7.45626>. Journal homepage: <https://innovareacademics.in/journals/index.php/ajpcr>

### INTRODUCTION

Although pulmonary tuberculosis (TB) decreased remarkably by antitubercular chemotherapy, a lot of patients associated with single or numerous sequelae remain in need for medical treatment for many symptoms even after years later. Despite microbiological cure, TB may be associated with frequent lung damages. Post-TB sequelae are present in up to 60–90% of patients who experience exercise limitations and have a hampered quality of life [1,2]. This post-acute phase was recently defined as post-TB lung disease [1,2].

The disease burden caused by TB (in particular, because of the contribution of post-TB lung disease) seems to be substantially greater than what is reported in current TB burden estimates [3]. In a narrow sense, the sequelae are a pathological status that is caused by many pathoanatomical changes in the healing process of pulmonary TB and need clinical treatment for many symptoms. In a broad sense, the sequelae also represent a pathological status with many symptoms after treatment that is caused by injuries in various organs with TB. There may be evidence of chronic respiratory abnormality with or without symptoms, attributable at least in part to previous TB [1]. A variety of sequelae and complications can occur in the pulmonary and extrapulmonary portions of the thorax in treated or untreated patients. According to Kim *et al.*, these can be categorized as follows: (a) Parenchymal lesions, which include tuberculoma, thin-walled cavity, cicatrization, end-stage lung destruction, aspergilloma, and bronchogenic carcinoma; (b) airway lesions, which include bronchiectasis, tracheobronchial stenosis, and broncholithiasis; (c) vascular lesions, which include pulmonary or bronchial arteritis and thrombosis, bronchial artery dilatation, and Rasmussen aneurysm; (d) mediastinal lesions, which include lymph node calcification and extra-nodal extension, esophagomediastinal or esophagobronchial

fistula, constrictive pericarditis, and fibrosing mediastinitis; (e) pleural lesions, which include chronic empyema, fibrothorax, bronchopleural fistula, and pneumothorax; and (f) chest wall lesions, which include rib TB, tuberculous spondylitis, and malignancy associated with chronic empyema. These varieties of manifestations can mimic other disease entities. Therefore, recognition of the manifestations of the thoracic sequelae and complications of TB are clinically important to facilitate diagnosis [4].

In day-to-day clinical practice, we commonly encounter many cases of post-TB sequelae. Very few studies have systematically examined pulmonary outcomes in patients to understand the pathophysiologic basis and long-term socioeconomic consequences of this injury. Proper understanding of profile of post-TB lung disease is of extreme clinical importance, particularly in the developing countries where health-care services and research activities are less adequate. Hence, there is always a need for newer study in this topic in countries like India where the prevalence of TB is very high.

This study was carried out with the objective of the assessment of clinical profile, radiological sequelae, and pulmonary function impairment among patients who had previously suffered from pleural or pulmonary TB.

### MATERIALS AND METHODS

This observational and cross-sectional study was conducted in the chest medicine department of Midnapore Medical College and Hospital in Paschim Medinipur district of West Bengal, India, from September 2019 to October 2020. This institution serves as the only teaching hospital in that district and patients attending to this hospital are mostly of rural background. Among patients attended

to the outpatient department of chest medicine, this study enrolled consecutive 300 patients from both genders of more than 12 years age having a history of pleural or pulmonary or both TB – either declared cure or treatment completed as per National TB Elimination Programme (Formerly Revised National TB Control Programme) in India. Patient having a history of any drug-resistant TB, history of incomplete anti-TB treatment, and history of preexisting respiratory diseases, such as, chronic obstructive pulmonary diseases (COPD), interstitial lung disease, and bronchiectasis before diagnosis of TB, clinically detected simple viral influenzae or respiratory tract infection in post-TB patients which seem not to be due to previous TB infection, human immunodeficiency virus (HIV)-positive patient, pregnant and lactating women, and also those unwilling to give consent were excluded from this study. Study proposal placed before Institutional Ethics Committee for approval and permission obtained.

After taking consent, detailed history including demographic data of patient, clinical presentation, and general and systemic examination was done. Routine hematological, biochemical, serological, sputum smear microscopy for the detection of AFB, and chest radiography were conducted on each case. Sputum for cartridge-based nucleic acid amplification test (CBNAAT), ultrasonography of thorax, computed tomography (CT) scan of thorax, image-guided fine-needle aspiration cytology (FNAC)/trucut biopsy, and pleural fluid analysis were done in appropriately indicated cases. All bacteriologically negative for TB patients was underwent spirometric evaluation. Patients having dyspnea were additionally evaluated by electrocardiography in all cases and echocardiography was reserved for only selective cases.

All data were collected in a pre-designed structural pro forma then entered into a Microsoft Excel spread sheet, 2007 version and analyzed by Statistical Package for the Social Sciences software version 20.

## RESULTS

Our study included 300 patients having a history of pleural or pulmonary TB of which 209 patients (69.67%) were male and 91 patients (30.33%) were female. Male: female ratio was 2.29:1. The mean age of all patient presented with post-TB sequelae was  $52.97 \pm 0.51$  (mean  $\pm$  standard error of mean [SEM]) years. Youngest patient was 35 years of age and oldest of 77 years. A total of 127 (42.33%) were either current or former smoker and all of them were male.

A history of pleural TB was present only in 11% of cases (n = 33) and pulmonary TB in 89% of cases (n = 267). As per history and available old treatment record of the patients, we grouped them according to oldness of their TB disease. It was up to 5 years in 14.23% (n = 38) of cases, 6–10 years in 17.6% (n = 47) of cases, 11–15 years in 32.58% (n = 87) of cases, and more than 15 years in 31.99% (n = 95) of cases. We got all pleural post-TB patients (100%, n = 33) between 11 years and 15 years after their initial illness.

Among presenting symptoms, cough was present in all (100%) patients. Expectoration was complained by 34.33% (n = 103) and in 65.67% (n = 197) of cases had only dry cough. Apart from cough, most of patients (n = 259, 86.33%) had complaint of shortness of breath (Fig. 1). When severity was assessed, 7.67% (n = 23) presented with Modified Medical Research Council (mMRC) [5] Grade I, 61.67% (n = 185) with mMRC Grade II, and 17% (n = 51) with mMRC Grade III. Hemoptysis was presenting symptom in 58.33% (n = 175) of cases. Chest pain was the least presenting complaint reported by 17.33% (n = 52) patients. Fever was present among 56 (18.67%) patients. Most of the patients had overlap of symptoms.

There were several chest deformities seen among post-TB cases. Scoliosis was found in 11% (n = 33) of cases followed by barrel shaped chest in 10.7% (n = 32). Pleural fibrosis/thickening was seen in 11% (n = 33) of patients out of which the right side (63.64%, n = 21) was involved more than the left side (36.36%, n = 12). Pleural calcification was found only in two cases. Hilar calcification was found in 7.6%

(n = 23) of patients out of which bilateral involvement was present in 1.3% (n = 4) of cases and unilateral 6.3% (n = 19) of cases.

Out of total 116 (38.67%) lung parenchymal fibrosis cases, bilateral upper zone fibrosis was found in 22% (n = 66) and the right upper zone fibrosis in 10.67% (n = 32) and left upper zone fibrosis 6% (n = 18) of cases, respectively. Bilateral cavitory lesion was found in 6.33% (n = 19) of cases, right upper zonal cavity was seen in 7.67% (n = 23), and left upper zonal cavity was seen in 7.33% (n = 22) of cases. Radiological feature of cavitory lesion with intracavitory body suggestive of aspergilloma was found in 7% of cases (n = 21). Bronchiectasis was detected in 12.67% (n = 38) of cases. Bullous lung disease was observed in 6.67% (n = 20) whereas emphysematous changes were seen 3.67% (n = 11) of cases. Pulmonary nodule seen in 5.67% (n = 17) of cases during imaging study. Few (n = 5, 1.67%) of them showed evidence of malignancy on FNAC/trucut biopsy sampling. Echocardiographic evidence of pulmonary hypertension was found in 6 (2%) cases. Two patients (0.67%) had pleural effusion overlapped with other features (Figs. 3 and 4).

Bacteriological positivity was found in 14.33% (n = 43) of cases. Four of them (9.3%) were reported as rifampicin resistant during CBNAAT testing.

In most of post-TB sequelae cases, involvement was unilateral (n = 171, 57%). Bilateral involvement was observed in 43% (n = 129) of cases (Table 1).

Out of total 300 patients, 257 cases were allowed to perform spirometry test as 43 cases of bacteriologically confirmed pulmonary TB were excluded from this procedure. All patients were able to perform the spirometric maneuver as per standard requirement. Most patients had restrictive pattern (n = 129, 50.20%) and obstructive pattern was observed in 38.13% (n = 98) of patients of which moderate obstruction ( $FEV1 \leq 80\%$ ) was seen in 28.79% (n = 74) and severe ( $FEV1 \leq 50\%$ ) in 9.34% (n = 24) of cases. Normal spirometric pattern was recorded in 11.67% (n = 30) of cases (Fig. 2). When spirometric abnormality was analyzed according to oldness of pleuropulmonary TB illness (Table 2), it was observed that most of the patients having abnormality including restrictive and obstructive category separately also gave a history of their TB illness episode more than 10 years ago; on the other side, most of patient having normal spirometric pattern gave a history of their TB illness within the past 10 years.

## DISCUSSION

In a developing country like India, TB is still an important public health problem. Until the coronavirus (COVID-19) pandemic, TB was the leading cause of death from a single infectious agent. The disease typically affects the lungs [6]. In accordance with the virulence of the organism and the defenses of the host, TB can occur in the lungs and in extrapulmonary organs. Early diagnosis and treatment is of extreme importance not only for ensuring cure but also to prevent the complications that may arise and persist even after being cured. A proper understanding of pathogenesis of TB is important to realize why the damages may remain even after adequate treatment of the disease. Pulmonary TB is caused by *Mycobacterium tuberculosis* when droplet nuclei laden with bacilli are inhaled. In the alveoli, macrophage ingests the bacilli and if they are unable to completely eradicate the bacilli then intracellular multiplication occurs and bacilli further spread toward the regional lymph node [7]. In an immunocompetent host, development of specific immunity is usually sufficient to limit the multiplication of bacilli, the host remains asymptomatic, and the lesions heal with resorption of caseous necrosis, fibrosis, and calcification [8]. Hence, a variety of sequelae and complications can occur in the pulmonary and extrapulmonary portions of the thorax in treated or untreated patients. Patients with post-TB sequelae have significant symptoms, radiological abnormalities, spirometry derangements, and impaired quality of life.

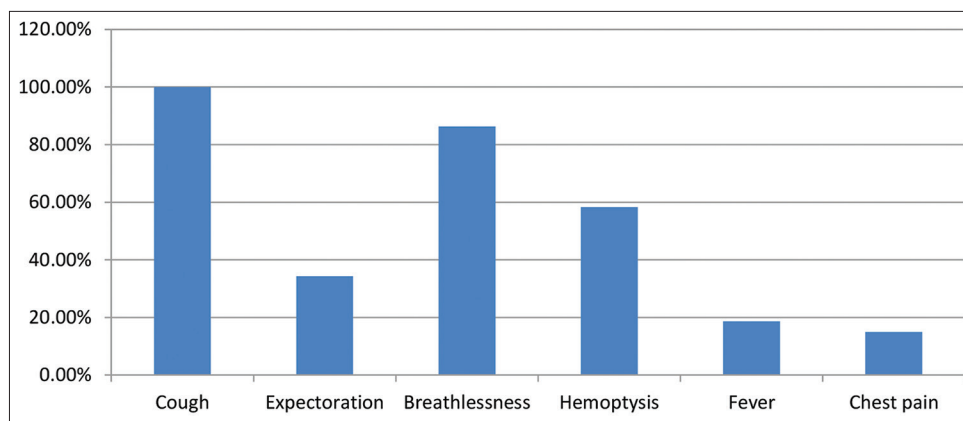


Fig. 1: Bar diagram showing symptomatology of post-TB sequelae

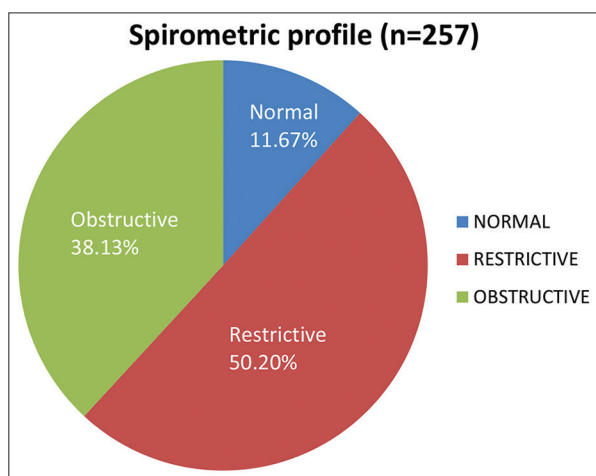


Fig. 2: Pie diagram showing spirometric profile of pleuropulmonary post-TB patients

Table 1: Spectrum of pleuropulmonary post-TB sequelae. (n=300)

Post-TB sequelae	No. of patients	Percentage
Lung parenchymal fibrosis	116	38.67
Pleural fibrosis	33	11
Chest deformity	77	25.67
Obstructive airway disease	98	32.67
Emphysema	11	3.67
Bullous lung disease	20	6.67
Cavitation	64	21.33
Bronchiectasis	38	12.67
Aspergilloma	21	7
Hilar calcification	23	7.6
Pulmonary nodule	17	5.67
Lung malignancy	5	1.67
Relapse of TB	43	14.33
Rifampicin-resistant TB	4	1.33
Pulmonary hypertension	6	2

TB: Tuberculosis

Table 2: Spirometric profile according to oldness of pleuroparenchymal TB disease

Spirometric profile	Oldness of pleuroparenchymal TB disease				Total
	≤5 years	6-10 years	11-15 years	≥16 years	
Restrictive	5	8	61	55	129
Obstructive					
Moderate	2	10	32	30	74
Severe	3	2	13	6	24
Normal	12	7	8	3	30
Total	22	27	114	94	257

TB: Tuberculosis

We studied 300 patients having a history of pleural or pulmonary TB. It was a male predominant study with male: female ratio of 2.29:1. Menon *et al.* and Naik *et al.* in their study found more number of male patients compared to females [9,10]. In Indian community, males usually move around more for education and employment purpose and many of them are compelled to stay in congregate setting and exposed to malnutrition which may render them to be a victim of TB. Mean age of all patients presented with post-TB sequelae was 52.97 ± 0.51 years (mean±SEM). In a study conducted by Naik *et al.*, mean age was 46.3 years with age range between 19 and 80 years [10]. Different study found history of smoking among post-TB patients ranged between 45.3 and 77% [10,11]. We found 42.33% of patients having either the current or past history of smoking. We got a lower percentage of smoker probably due to exclusion of preexisting COPD before TB illness in our study sample.

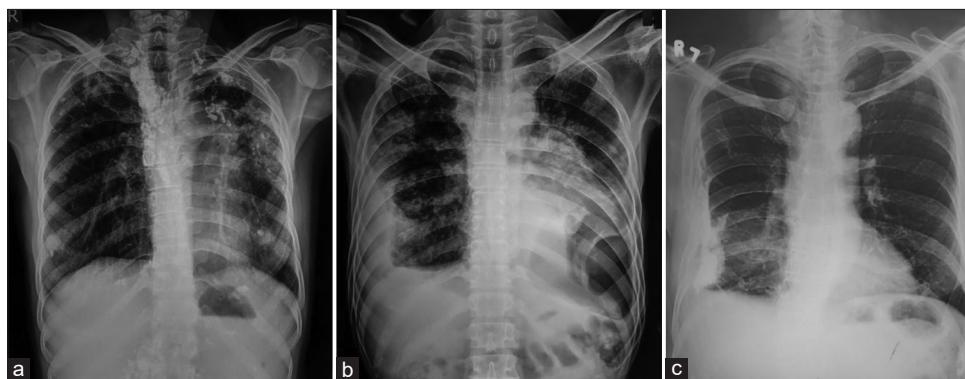
Musafiri *et al.* in their study on 202 patients showed that chronic cough (196 / 202), abundant expectorations (106 / 202), and hemoptysis (123 / 202) were the main symptoms [12]. Similar result was found in our study which revealed that cough in 100% of cases; expectoration of sputum was reported in 34.33% and dry cough in 65.67% of cases. Shortness of breath was complained by 86.33% of patients. Hemoptysis was the presenting symptom in 58.33% of cases. Ayari *et al.* in their study showed that the clinical symptoms were dominated by a chronic sputum (74%), dyspnea (68%), and hemoptysis (34%). They also found that mean time to the onset of respiratory symptoms related to pulmonary sequelae was 15.6 ± 8 years [11]. As per history and available old treatment record of the patients, we found that 32.58% of cases had TB illness 11-15 years ago and 31.99% had it more than 15 years ago before presenting before us.

Bacteriological positivity during sputum smear examination was recorded in 14.33% of cases in our study whereas Revendran *et al.* in their study showed pulmonary TB relapse in 26.3% of cases [13].

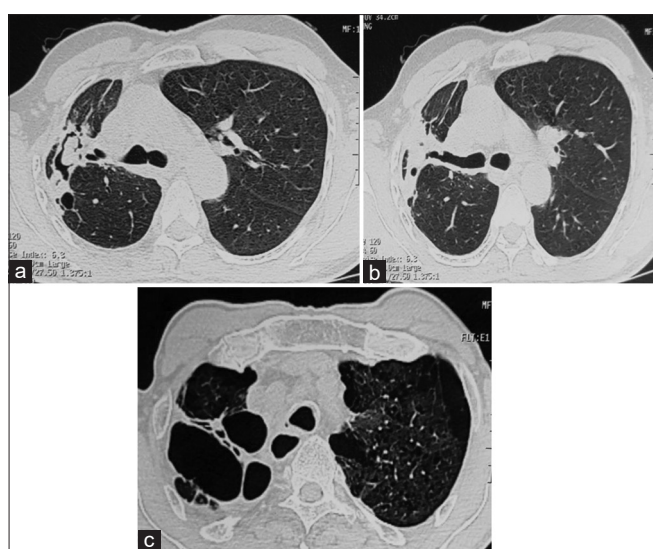
It has been observed by the previous study that despite adequate chemotherapy and adequate clinical response in new cases of TB, a large proportion of patient is left with residual radiological lesion [9]. A delay in the time period from the onset of symptoms to treatment initiation might contribute to a greater spread and progression of lung lesions, leading to more residual damage [14].

In our study, most of post-TB sequelae cases, pulmonary involvement was unilateral (57%). Bilateral involvement was observed only in 43%





**Fig. 3:** Chest X-ray of three patients of our study. (a) Lung parenchymal fibrosis with calcification along with mediastinal lymph node calcification in the right side, more fibrosis in the left side pulled lower mediastinum towards the same side. (b) The right-sided encysted pleural effusion and left-sided pleural thickening, cavitary lesion in the left lower zone with mediastinal shifting toward the left side along with bilateral patchy opacity. Sputum smear examination by Ziehl-Neelsen staining was positive for acid-fast bacilli of this patient. (c) Right sided pleural thickening with calcification



**Fig. 4:** High-resolution computed tomography scan of thorax of three patients of our study. (a) The right upper lobe fibrosis with cavitation along with intracavitary body suggestive of aspergilloma. (b) Traction bronchiectasis along with fibrosis of the right upper lobe. (c) Extensive fibrocavitary lesion of the right upper lobe along with shifting of mediastinum toward the right side and left upper lobe emphysema

of cases. On the other hand, 55.2% had unilateral changes in a study conducted by Naik *et al.* in their study [10].

According to Ayari *et al.* in their retrospective study on management of pulmonary TB sequelae found: A destroyed lung (46%), bronchiectasis (31%), aspergilloma (14%), emphysema (12.3%), pulmonary fibrosis (7.7%), residual cavity (6.2%), and lung cancer (1.5%) on thoracic imaging [11]. In comparison, our study observed pleural fibrosis/thickening in 11% of cases, lung parenchymal fibrosis in 38.67%, aspergilloma in 7% of cases, bronchiectasis in 12.67%, emphysematous changes in 3.67%, bilateral cavities in 6.33%, left upper lobe cavity in 7.33%, right upper lobe cavity in 7.67%, and bullous lung disease in 6.67% of cases. Revendran *et al.* analyzed the CT features of pulmonary tubercular sequelae and found fibrosis and bronchiectasis as two most common abnormalities, found 63.2% and 61.8% of cases, respectively, followed by collapse (22.4%), cavity (19.7%), emphysema (14.5%), and aspergilloma (6.6%) [13]. In our study, lung parenchymal fibrosis was seen in 38.67%, pleural fibrosis/thickening was seen in 11%, bronchiectasis in 12.67%, and

aspergilloma in 7% of total patients. The presence of aspergilloma was found in 5.4% of cases in a study conducted by Musafiri *et al.* [12]. Kwon *et al.* in their study done from 2004 to 2006 observed that at the end of antitubercular medication for pleural effusion, the incidence of residual pleural opacity was 68.3% on CT but pleural residual lesions found in 23.6% of the total cases in a study done by Menon *et al.* in 2015 [9,15]. Pulmonary nodule that results in lung cancer on FNAC/trucut biopsy sampling seen in 1.67% of total cases in our study whereas Ayari *et al.* reported lung cancer among 1.5% of patients in their study [11].

Revendran *et al.* in their study on post-TB complication showed that persistent symptoms were present in 68.4% of cases. Obstructive airway disease was found in 32.9% [13]. During spirometry, we found obstructive pattern in 38.13% of cases, restrictive pattern in 50.20% of cases among 257 cases. Pasipanodya *et al.* conducted a study in the United States showed that 59% of patients treated for TB subsequently had abnormal pulmonary function. In that study, more than half of the patients treated for PTB evolved to significantly impair pulmonary function. They observed that the prevalence of individual subtypes of impairment for obstructive, restrictive, and mixed was 15%, 31%, and 13% [16]. Soni *et al.* in their study found mixed pattern as most common lung function defect followed by obstructive pattern [17]. In spirometric assessment of symptomatic post-TB cases, obstructive pattern was documented in 42% of cases as a predominant type but among asymptomatic post-TB cases, obstructive pattern was documented in 32%, mixed pattern in 14%, and normal spirometry in 46% of cases in a study done by Patil *et al.* [18]. Few Indian studies done by Verma *et al.*, Rajasekaran *et al.*, Krishna *et al.*, and Salvi and Barness, respectively, observed the obstructive airway disease as common phenomena in previously treated TB cases which were documented within 1–10 years of follow-up [19–21]. In our study, most of the spirometric abnormalities including restrictive and obstructive category individually gave a history of their TB illness episode more than 10 years ago. Post-TB pulmonary impairment has emerged as a distinct clinical entity, which is almost indistinguishable from other forms. The exact pathogenesis of the development of this disorder is unclear. It requires insight, understanding and evaluation of its evolution, clinical course, and management [23].

There were few limitations in our study. It was a single-center cross-sectional study and there was lack of follow-up data for these patients. The presence of confounding factor due to smoking and comorbid illness like ischemic heart disease cannot be ruled out. Possibility of selection bias may be there as mainly mild-to-moderate symptomatic patients attended to the outpatient department were included in our study and possibly majority of severe-to-very severe cases missed out as they might have attended to the emergency department.

**CONCLUSION**

Treatment of TB is not the end of the management cascade because of the wide spectrum of post-TB lung disease associated with it. Periodical follow-up even after being cured or treatment completion may be helpful for early detection and appropriate management of any pleuropulmonary post-TB lung disease.

**ACKNOWLEDGMENT**

We are grateful to the Principal, Medical Superintendent cum Vice Principal of Midnapore Medical College & Hospital for allowing us to carry out this study. We are thankful to all the staff of department of Chest Medicine for helping us to conduct the study. Finally we are thankful to all the participants of this study.

**SOURCE OF SUPPORT**

In the form of grants equipment, drugs, or all of these: Nil.

**CONFLICTS OF INTEREST**

There are no conflicts of interest.

**AUTHORS' CONTRIBUTIONS**

Santu Kumar Samanta: Conceptualization, data collection, formal analysis, and manuscript writing. Aparup Dhua: Conceptualization, data curation, investigation, manuscript writing, reviewing, and editing. Mukul Chakraborty: Investigation, validation, manuscript reviewing, and editing. Pranab Mandal: Supervision, investigation, validation, and manuscript reviewing.

**REFERENCES**

- Allwood BW, van der Zalm MM, Amaral AF, Byrne A, Datta S, Egere U, *et al.* Post-tuberculosis lung health: Perspectives from the first international symposium. *Int J Tuberc Lung Dis* 2020;24:820-8.
- Migliori GB, Marx FM, Ambrosino N, Zampogna E, Schaaf HS, van der Zalm MM, *et al.* Clinical standards for the assessment, management and rehabilitation of post-TB lung disease. *Int J Tuberc Lung Dis* 2021;25:797-813.
- Menzies NA, Quaipe M, Allwood BW, Byrne AL, Coussens AK, Harries AD, *et al.* The lifetime burden of disease due to incident tuberculosis: A global re-appraisal including post-tuberculosis sequelae. *Lancet Glob Health* 2021;9:e1679-87.
- Kim HY, Song KS, Goo JM, Lee JS, Lee KS, Lim TH. Thoracic sequelae and complications of tuberculosis. *Radiographics* 2001;21:839-60.
- Fletcher CM. Standardized questionnaires on respiratory symptoms. *BMJ* 1960;2:1662.
- World Health Organisation. Global Tuberculosis report 2021. Geneva: World Health Organisation; 2021. p. 1. Available from: <https://www.who.int/publications/i/item/9789240037021-eng.pdf> [Last accessed on 2022 June 23].
- Leung AN. Pulmonary tuberculosis: The essentials. *Radiology* 1999;210:307-22.
- Bass JR, Farer LS, Hopewell PC, Jacobs RF, Snider DE Jr. Diagnostic standards and classification of tuberculosis. *Am Rev Respir Dis* 1990;142:725-35.
- Menon B, Nima G, Dogra V, Jha S. Evaluation of the radiological sequelae after treatment completion in new cases of pulmonary, pleural, and mediastinal tuberculosis. *Lung India* 2015;32:241-5.
- Naik NR, Patil CB, Indushekar V. Pulmonary sequelae in tuberculosis: Analysis of clinical and radiological pattern in 172 patients. *J Evid Based Med Healthc* 2019;6:287-91. DOI: 10.18410/jebmh/2019 / 59
- Ayari A, Smadhi H, Mejri I, Kamoun H, Greb D, Akrouf I, Hassen H, *et al.* Management of pulmonary tuberculosis sequelae. *Eur Respir J* 2015;46:PA2762. DOI: 10.1183 / 13993003.congress
- Mutafiri S, Dusabejamba V, Munganyinka BC, Manzi O, Kalisa L, Rutayisire PC. The aftermath of pulmonary tuberculosis: Predictors of severe pulmonary sequelae and quality of life of patients visiting a tertiary level of care in Rwanda, East Africa. *Aust J Pulm Respir Med* 2015;2:1027.
- Revendran J, Patil K, Nair G, Uppe A, Nanda V, Sawant S, *et al.* Long term sequelae of pulmonary tuberculosis and the factors predicting its development: A clinicoradiological study. *Eur Respir J* 2018;52:PA2746. DOI: 10.1183 / 13993003
- Long R, Maycher B, Dhar A, Manfreda J, Hershfield E, Anthonisen N. Pulmonary tuberculosis treated with directly observed therapy: Serial changes in lung structure and function. *Chest* 1998;113:933-43.
- Kwon JS, Cha SI, Jeon KN, Kim YJ, Kim EJ, Kim CH, *et al.* Factors influencing residual pleural opacity in tuberculous pleural effusion. *J Korean Med Sci* 2008;23:616-20.
- Pasipanodya JG, Miller TL, Vecino M, Munguia G, Garmon R, Bae S, *et al.* Pulmonary impairment after tuberculosis. *Chest* 2007;131:1817-24.
- Soni L, Borana H, Purohit G, Choudhary CR, Garg I, Agarwal S, Sharma LK, *et al.* Impact of pulmonary tuberculosis sequelae on functional status. *Eur Respir J* 2016;48:PA2103. DOI: 10.1183 / 13993003.congress-2016.PA2103
- Patil S, Patil R, Jadhav A. Pulmonary functions' assessment in post-tuberculosis cases by spirometry: Obstructive pattern is predominant and needs cautious evaluation in all treated cases irrespective of symptoms. *Int J Mycobacteriol* 2018;7:128-33.
- Verma SK, Narayan KV, Kumar S. A study on prevalence of obstructive airway disease among post pulmonary tuberculosis patients. *Pulmonary* 2009;11:4-7.
- Rajasekaran S, Savithri S, Jeyaganesh D. Post tuberculosis bronchial asthma. *Indian J Tuberc* 2001;48:139-42.
- Krishna K, Bond S, Artvinli M, Reid KD, McHardy GJ, Crofton JW. Pulmonary function in treated tuberculosis; a long term followup. *Am Rev Respir Dis* 1977;115:402-4.
- Salvi SS, Barnes PJ. Chronic obstructive pulmonary disease in nonsmokers. *Lancet* 2009;374:733-43.
- Vinod P, Kanmani MK, Ketaki U, Unnati D, Joshi JM. Complication and sequelae of pulmonary tuberculosis: A tertiary care center experience. *Int J Pul Res Sci* 2022;5:555674. DOI: 10.19080/IJOPRS.2022.05.555674