

FUNCTIONAL OUTCOME OF TENNIS ELBOW (LATERAL EPICONDYLITIS) TREATED BY LOCAL INJECTION OF PLATELET RICH PLASMARAHIL JIWANI¹, SATISH MEHTA², ABHIJIT KADAM^{2*}¹Associate Professor, ²Assistant Professor, Department of Orthopaedics, Bharati Vidyapeeth (Deemed to be University) Medical College and Hospital, Sangli, Maharashtra, India. Email: abhinamya@gmail.com

Received: 1 August 2022, Revised and Accepted: 10 September 2022

ABSTRACT**Objective:** The aim of the study was to evaluate the efficacy of local injection of platelet rich plasma in management of patients with tennis elbow who failed to respond to conservative management.**Methods:** This was a prospective and cohort study in which 80 patients with lateral epicondylitis (Tennis elbow) were included on the basis of a predefined inclusion and exclusion criteria. Demographic details were noted. Patients were treated by local injection of autologous platelet rich plasma. Patients were followed up for 6 months. Relief of pain as well as functional improvement was assessed by patient-rated tennis elbow evaluation (PRTEE) score. SPSS 21.0 software was used for statistical analysis and $p < 0.05$ was taken as statistically significant.**Results:** Out of 80 studied cases, there were 36 (45%) males and 44 (55%) females with a M: F ratio of 1:1.22. The mean age of male (42.77 ± 9.95 years) as well as female (41.06 ± 9.56 years) was found to be comparable. Nineteen (23.75%) patients were involved in plumbing, 16 (20%) patients were involved in activities that required forceful use of screwdrivers such as electric work, 8 (10%) patients were involved in gardening, and 7 (8.75%) patients were involved in production or laying of bricks. Twelve (15%) patients were professional tennis player. The mean PRTEE score was 74.24 ± 9.74 at the time of presentation. There was significant reduction in PRTEE score during follow-up and at the time of last follow-up visit, PRTEE score was found to be 8.32 ± 2.56 .**Conclusion:** Local injection of autologous platelet rich plasma is effective in managing patients of lateral epicondylitis (Tennis elbow) who fail to respond to conservative management.**Keywords:** Tennis elbow, Platelet rich plasma, Patient-rated tennis elbow evaluation score, Functional outcome.© 2022 The Authors. Published by Innovare Academic Sciences Pvt Ltd. This is an open access article under the CC BY license (<http://creativecommons.org/licenses/by/4.0/>) DOI: <http://dx.doi.org/10.22159/ajpcr.2022v15i10.46408>. Journal homepage: <https://innovareacademics.in/journals/index.php/ajpcr>**INTRODUCTION**

Tennis elbow or lateral epicondylitis is a term that denotes inflammation of common extensor origin of the forearm and is usually seen following activities that require repeated contraction of the wrist extensors such as playing tennis, gardening, plumbing, lifting pots, and in musicians [1]. The term tennis elbow or lateral epicondylitis appears to be a misnomer because it is neither exclusively seen in tennis player nor there is inflammation of lateral epicondyle. Rather it can be seen in anyone involved in activities that requires repeated contractions of wrist extensors and the pathology is in common extensor origin of forearm rather than lateral epicondyle. The involvement of extensor carpi radialis brevis tendon just distal to its attachment on the lateral epicondyle is the most common pathology in majority of the cases [2].

The condition was first described by Runge F who described it as chronic degeneration process of the forearm common extensor tendon leading to symptoms such as pain over the lateral elbow that typically worsens with activity and improves with rest. Lateral epicondylitis predominantly involves dominant limb and middle-aged individuals. Men and women are equally affected. The annual incidence of lateral epicondylitis varies from 1% to 3%. The increasing incidence may partly be due to increasing facilities for imaging technique such as computerized tomography (CT) and magnetic resonance imaging (MRI) [3].

The clinical presentation is typical and consist of pain over lateral elbow that aggravates particularly following activities such as playing tennis or forceful use of screwdriver or any activity that requires contraction of wrist extensor [1]. The pain typically reduces after rest. On physical examination, there is a significant tenderness just distal to lateral

epicondyle. There is sharp pain if wrist is extended in radial deviation and pronation [4]. The diagnosis is usually clinical; however, imaging techniques such as X-ray, ultrasound examination, CT, and MRI may be used for confirmation of diagnosis. Plain X-ray is not specific for the diagnosis but may show features such as calcific foci around lateral epicondyle. On ultrasound thickening of the common extensor tendon and diffuse heterogeneity and areas of hypo echogenicity may be seen [5]. MRI is the most sensitive imaging technique for diagnosis of lateral epicondylitis and may show thickening and increased signal intensity involving common extensor origin just distal to lateral epicondyle [6].

In cases, having mild pain rest and physiotherapy may be all that is needed; however, in cases not responding to rest and physiotherapy may require administration of non-steroidal anti-inflammatory drugs [7]. The other modality of treatment may include local injection of steroids and bracing. extracorporeal shock wave therapy and wrist-extensor splints have also been reported to be effective in cases not responding to conservative measures [8]. The other treatment options which are reported to be effective include autologous blood injections and local injection of platelet rich plasma. In intractable cases, surgical interventions such as percutaneous tenotomy may be needed [9].

We undertook this study to analyze the effectiveness of local injection of platelet-rich plasma in patients diagnosed to be having lateral epicondylitis.

METHODS

This was a prospective and cohort study conducted in the Department of Orthopaedics of a tertiary care medical college. Adult patients

diagnosed to be having lateral epicondylitis on the basis of clinical features and imaging and who failed to respond to conservative approaches such as administration of non-steroidal anti-inflammatory drugs and physiotherapy for 3 months were included in this study on the basis of a predefined inclusion and exclusion criteria. Institutional ethical committee approved the study and an informed written consent was obtained from all the participants. Sample size was calculated according to the previous reference studies, as the main result in the event of at least 60 patients was calculated by Open Epi-Version 3 online software, a 10% difference could be determined between the group at 80% power and 5% significance ($\alpha=0.05$, $\beta=0.80$). We included more than minimum required number of cases for the study. The procedure of local injection of platelet-rich plasma with its advantages and probable complications was explained to patients before obtaining consent from them.

Demographic details such as age, gender, and body mass index were noted. History of any systemic illness such as diabetes, hypertension, and bronchial asthma was noted. History of illnesses which may interfere with functional assessment such as arthritis, arthralgia, or autoimmune disorders was asked for and noted. Basic investigations such as complete blood count, C-reactive protein, and erythrocyte sedimentation rate were done in all cases. X-ray and ultrasound examination of affected elbow was done in all the cases. CT and/or MRI was done only in selected cases. The patients were assessed at the time of presentation using patient-rated tennis elbow evaluation (PRTEE) score which involves assessment of pain as well as functions of the affected elbow in terms of best (score of 0) to worst (score of 100) pain and functional ability [10].

Method of local injection of platelet rich plasma

With all aseptic precautions, 10 ml of patient’s venous blood was collected in EDTA bulb. After collection, the blood was centrifuged for 15–20 min. The centrifugation process resulted in separation of blood into three layers. Out of these three separated layers, the buffy coat layer was once again transferred to centrifugation chamber and was once again centrifuged for 15 min resulting into platelet-rich plasma layer. 3–3.5 ml of this platelet rich plasma then was transferred to a 5 ml syringe. Patient was positioned in supine position and elbow was flexed to 90° and platelet-rich plasma was infiltrated near lateral epicondyle as well as common extensor tendon. After the local injection, the affected hand was placed in sling for 48 h. After 48 h, the patient was advised eccentric elbow exercises under the guidance of physiotherapist.

The patients were followed up at 2 weeks, 4 weeks, 3 months, and 6 months. At each follow-up visit, patients were assessed by PRTEE score that included assessment of severity of pain as well as functional assessment. SPSS 21.0 software was used for statistical analysis and $p<0.05$ was taken as statistically significant.

Inclusion criteria

The following criteria were included in the study:

1. Patients diagnosed to be having lateral epicondylitis (Tennis elbow)
2. Age more than 18 years
3. Failed to respond to conservative management for 3 months
4. Gave informed written consent to be part of study.

Exclusion criteria

The following criteria were excluded from the study:

1. Age <18 years
2. Those who refused consent
3. Any previous local intervention such as injection of steroids
4. Any previous surgery on affected elbow
5. Conditions likely to affect functional assessment such as arthritis or arthralgia.

RESULTS

This study was conducted to analyze functional outcome of patients with tennis elbow (Lateral Epicondylitis) treated by local injection of autologous platelet-rich plasma. A total of 80 patients were included

in this study out of which there were 36 (45 %) males and 44 (55%) females with a M: F ratio of 1:1.22 (Fig. 1).

The most common affected age group was between the age of 41–50 years (38.75%) followed by 31–40 years (25.00%) and 51–60 years (18.75%). It was found to be less common in patients below 30 years (10%) and above 60 years (7.50%) of age (Table 1).

The mean age of male (42.77±9.95 years) as well as female (41.06±9.56 years) was found to be comparable with no statistically significant difference in the age group of males and females ($p=0.4369$) (Table 2).

The analysis of studied cases on the basis of BMI showed that most of the patients with lateral epicondylitis (tennis elbow) were either obese (59.78%) or overweight (27.17%). It was less common in individuals having healthy BMI (9.78%) or underweight individuals (3.26%) (Table 3).

Patients were analyzed on the basis of probable cause of lateral epicondylitis. Majority of the patients were found to be engaged in

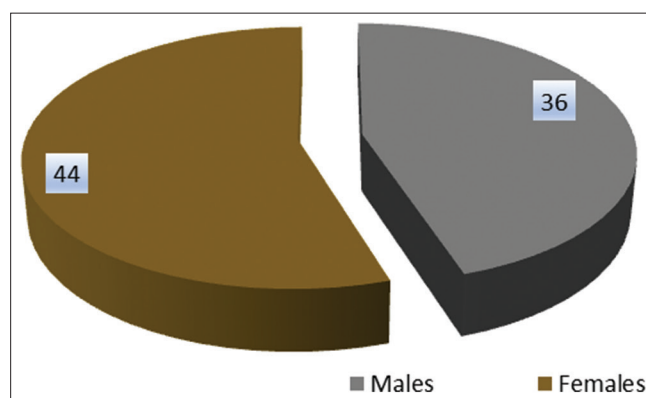


Fig. 1: Gender distribution of the studied cases

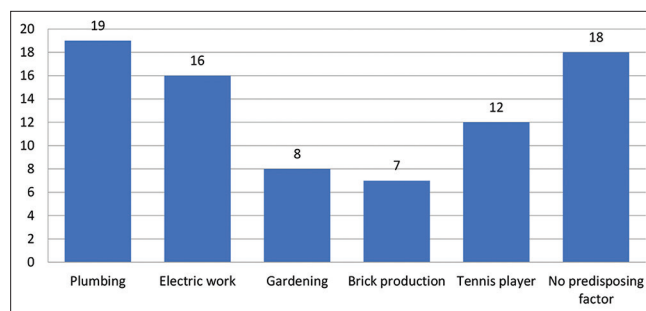


Fig. 2: Predisposing factors for lateral epicondylitis in studied cases

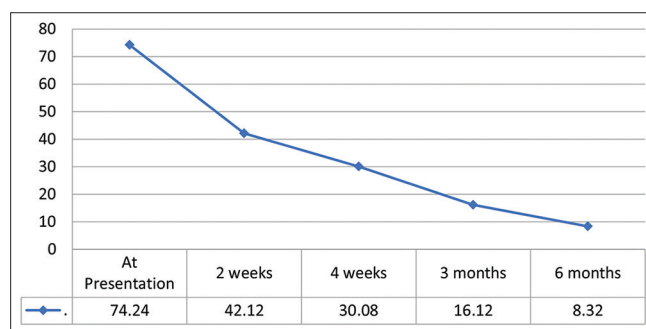


Fig. 3: Mean PRTEE scores at presentation and during follow-up visits

Table 1: Comparison of gender-wise age distribution

Age Groups	Males		Females		Total	
	No of cases	Percentage	No of cases	Percentage	No of cases	Percentage
30 years or less	2	2.50	6	7.50	8	10.00
31-40 years	9	11.25	11	13.75	20	25.00
41-50 years	15	18.75	16	20.00	31	38.75
51-60 years	6	7.50	9	11.25	15	18.75
>60 years	4	5.00	2	2.50	6	7.50
Total	36	45.00	44	55.00	80	100

Table 2: Gender-wise distribution of the age groups of the patients

Gender	Mean age	SD	Test of significance
Males	42.77	9.95	p=0.4369
Females	41.06	9.56	Not Significant

Table 3: Body mass index of studied cases

Body mass index	Number Of Patients	Percentage
Underweight (<18.5)	4	5.00
Healthy Weight (18.5-24.9)	16	20.00
Overweight (25-29.9)	43	53.75
Obese (30 or above)	17	21.25
Total	80	100.0

Table 4: Duration of pain in studied cases

Duration Of Pain	No of patients	Percentage
3-6 months	13	16.25
6-9 months	45	56.25
9 months-1 year	17	21.25
Above 1 year	5	6.25
Total	80	100.00

Table 5: PRTEE Score in studied cases at presentation and during follow-up

PRTEE Score	Mean	Std Deviation
At Presentation	74.24	9.74
2 weeks	42.12	6.82
4 weeks	30.08	4.82
3 months	16.12	3.04
6 months	8.32	2.56

activities that requires repeated contraction of the wrist extensors. Out of 80 studied cases, 19 (23.75%) patients were involved in plumbing, 16 (20%) patients were involved in activities that required forceful use of screwdrivers such as electric work, 8 (10%) patients were involved in gardening, and 7 (8.75%) patients were involved in production or laying of bricks. Twelve (15%) patients were professional tennis player. In 18 (22.50%) patients, no such predisposing factors were found. Out of 18 patients in whom no predisposing factor was found, 16 were females (Fig. 2).

The analysis of the duration of the pain in patients showed that in majority of the patients, it was between 6 and 9 months (56.25%) followed by 9-12 months (21.25%) and 3-6 months (16.25%). Only 5 (3%) patients belonged to duration of pain more than 1 year (Table 4).

The analysis of outcome in terms of pain and functional outcome was assessed using PRTEE score. Since this score includes severity of pain as well as functional assessment; hence, separate assessment of pain using visual analog scale (VAS) score was not done. The mean

PRTEE score was 74.24 ± 9.74 at the time of presentation. There was significant reduction in PRTEE score during follow-up and at the time of last follow-up visit (at 6 months), PRTEE score was found to be 8.32 ± 2.56 (Fig. 3 and Table 5).

There was a significant reduction in pain as well as improvement in functional outcome after injection of platelet-rich plasma as assessed by PRTEE scores at presentation and at 2 weeks, 4 weeks, 3 months, and 6 months postoperatively. The difference was found to be statistically highly significant ($p < 0.0001$). At the time of final follow-up, 69 (86.25%) were completely pain free while remaining patients (13.75%) have minimal pain.

Apart from local pain immediately after local injection of PRP, there were no other significant complications in any of the studied cases. Pain experienced by all the patients was tolerable and subsided with rest and application of ice without need for analgesic drugs.

DISCUSSION

This was a prospective study in which 80 patients having lateral epicondylitis and treated by local injection of platelet-rich plasma were included in the study. There were 36 (45 %) males and 44 (55%) females with a M: F ratio of 1:1.22. Cho *et al.* conducted a retrospective and cross-sectional study of patients having lateral epicondylitis [11] The study found that the age distribution of patients was 45-54 years (39.93%), 55-64 (23.12%), and 35-44 years (21.07%), and there were more female patients (53.66%) than male patients (46.34%). Similar female preponderance in patients of lateral epicondylitis was also reported by the authors such as Descatha *et al.* [12] and Vaquero-Picado *et al.* [13].

In our study, the most common affected age group was between the age of 41-50 years (38.75%) followed by 31-40 years (25.00%) and 51-60 years (18.75%). The mean age of male and female patients was found to be 42.77 ± 9.95 years and 41.06 ± 9.56 years, respectively. The mean age of male and female patients was found to be comparable with no statistically significant difference ($p = 0.4369$). Sanders *et al.* conducted a study to evaluate the natural history of lateral elbow tendinosis in a large population [14]. In this study, the authors analyzed medical records to ascertain information on patient and disease characteristics, treatment modalities, recurrence, and progression to surgery. Age- and sex-specific incidence rates of patients with lateral epicondylitis. The mean age of studied cases in this study was found to be 47 ± 11 years. The mean age of patients in our study was found similar to this study. Similar mean age of affected cases was also reported by the authors such as Dunn *et al.* [15] and Haahr and Andersen [16].

The patients were evaluation for pain relief as well as functional outcome using PRTEE score. PRTEE was 74.24 ± 9.74 at the time of presentation. There was significant reduction in PRTEE score during follow-up and at the time of last follow-up visit at 6 months, PRTEE score was found to be 8.32 ± 2.56 . There was a significant reduction in pain as well as improvement in functional outcome after injection of platelet-rich plasma at presentation and at 2 weeks, 4 weeks, 3 months, and 6 months postoperatively. Kumawat *et al.* conducted a similar study to assess the efficacy of autologous PRP injection in lateral epicondylitis

Table 6: Comparison of PRTEE score at follow up visits

Difference in PRTEE scores	p-value	95% CI	Test of significance
Pre-operative and at 2 weeks	p<0.0001	-34.7456--219.4944	Highly Significant
2 week and 4 weeks	p<0.0001	-13.8842--10.1958	Highly Significant
4 weeks and 3 months	p<0.0001	-15.2184--12.7016	Highly Significant
3 months and 6 months	p<0.0001	-8.6776--6.9224	Highly Significant
At presentation and at 12 weeks follow-up	p<0.0001	-68.1439--63.6961	Highly Significant

of elbow [17]. For this purpose, 100 patients of lateral epicondylitis were selected and treated. VAS and PRTEE scoring were used for clinical and functional assessment at pre-injection, 2nd week, 4th week, 3rd month, and 6th month. The study found that the end of 6-month follow-up, 61% of patients were completely relieved of pain. About 34% of patients had mild pain that was significantly decreased. In our study, we did not assess patients separately using VAS score because PRTEE score itself includes component of pain assessment. The authors concluded that PRP injection is effective in treating pain and have an excellent functional outcome in patients with lateral epicondylitis. The findings of this study were also similar to our study. Similar excellent outcome of patients treated by PRP injections was also reported by the authors such as Omar *et al.* [18] and Palacio *et al.* [19].

CONCLUSION

Local injection of autologous platelet-rich plasma appears to be effective in reducing pain as well as improving functional outcome in cases of tennis elbow which failed to respond to conservative management such as rest and non-steroidal anti-inflammatory drugs. In many cases injection of platelet-rich plasma may obviate need for surgical interventions in these patients.

REFERENCES

- Cutts S, Gangoo S, Modi N, Pasapula C. Tennis elbow: A clinical review article. *J Orthop* 2019;17:203-7. doi: 10.1016/j.jor.2019.08.005. PMID: 31889742; PMCID: PMC6926298
- Johns N, Shridhar V. Lateral epicondylitis: Current concepts. *Aust J Gen Pract* 2020;49:707-9. doi: 10.31128/AJGP-07-20-5519. PMID: 33123709
- Qi L, Zhang YD, Yu RB, Shi HB. Magnetic resonance imaging of patients with chronic lateral epicondylitis: Is there a relationship between magnetic resonance imaging abnormalities of the common extensor tendon and the patient's clinical symptom? *Medicine (Baltimore)* 2016;95:e2681. doi: 10.1097/MD.0000000000002681. PMID: 26844506; PMCID: PMC4748923
- Flatt AE. Tennis elbow. *Proc (Bayl Univ Med Cent)* 2008;21:400-2. doi: 10.1080/08998280.2008.11928437. PMID: 18982084; PMCID: PMC2566914
- Levin D, Nazarian LN, Miller TT, O'Kane PL, Feld RI, Parker L, *et al.* Lateral epicondylitis of the elbow: US findings. *Radiology* 2005;237:230-4. doi: 10.1148/radiol.2371040784. Epub 2005 Aug 18. PMID: 16118152
- Cha YK, Kim SJ, Park NH, Kim JY, Kim JH, Park JY. Magnetic resonance imaging of patients with lateral epicondylitis: Relationship between pain and severity of imaging features in elbow joints. *Acta Orthop Traumatol Turc* 2019;53:366-71. doi: 10.1016/j.aott.2019.04.006. Epub 2019 Apr 28. PMID: 31040053; PMCID: PMC6819801
- Ma KL, Wang HQ. Management of lateral epicondylitis: A narrative literature review. *Pain Res Manag* 2020;2020:6965381. doi: 10.1155/2020/6965381. PMID: 32454922; PMCID: PMC7222600
- Razavipour M, Azar MS, Kariminasab MH, Gaffari S, Fazli M. The short term effects of shock-wave therapy for tennis elbow: A clinical trial study. *Acta Inform Med* 2018;26:54-6. doi: 10.5455/aim.2018.26.54-56. PMID: 29719315; PMCID: PMC5869227
- Ang BF, Mohan PC, Png MA, Allen JC Jr., Howe TS, Koh JS, *et al.* Ultrasonic percutaneous tenotomy for recalcitrant lateral elbow tendinopathy: Clinical and sonographic results at 90 months. *Am J Sports Med* 2021;49:1854-60. doi: 10.1177/03635465211010158. Epub 2021 May 6. PMID: 33956537
- Marks M, Rickenbacher D, Audigé L, Glanzmann MC. Patient-rated tennis elbow evaluation (PRTEE). *Z Orthop Unfall* 2021;159:391-6. doi: 10.1055/a-1107-3313. Epub 2020 Mar 23. PMID: 32207123
- Cho Y, Yeo J, Lee YS, Kim EJ, Nam D, Park YC, *et al.* Healthcare utilization for lateral epicondylitis: A 9-year analysis of the 2010-2018 health insurance review and assessment service national patient sample data. *Healthcare* 2022;10:636. <https://doi.org/10.3390/healthcare10040636>
- Descatha A, Dale AM, Jaegers L, Herquelot T, Evanoff B. Self-reported physical exposure association with medial and lateral epicondylitis incidence in a large longitudinal study. *Occup Environ Med* 2013;70:670-3.
- Vaquero-Picado A, Barco R, Antuña SA. Lateral epicondylitis of the elbow. *EFORT Open Rev* 2017;1:391-7. doi: 10.1302/2058-5241.1.000049. PMID: 28461918; PMCID: PMC5367546
- Sanders TL Jr., Kremers HM, Bryan AJ, Ransom JE, Smith J, Morrey BF. The epidemiology and health care burden of tennis elbow: A population-based study. *Am J Sports Med* 2015;43:1066-71. doi: 10.1177/0363546514568087. Epub 2015 Feb 5. PMID: 25656546; PMCID: PMC4517446
- Dunn JH, Kim JJ, Davis L, Nirschl RP. Ten-to 14-year follow-up of the Nirschl surgical technique for lateral epicondylitis. *Am J Sports Med* 2008;36:261-6.
- Haahr JP, Andersen JH. Physical and psychosocial risk factors for lateral epicondylitis: A population based case-referent study. *Occup Environ Med* 2003;60:322-9.
- Kumawat PK, Goel R, Kumhar U, Sharma R, Parmar R, Sharma B. Management of lateral epicondylitis (tennis elbow) by local infiltration of platelet rich plasma an outcome study. *Int J Res Orthop* 2020;6:963-7.
- Omar AS, Ibrahima ME, Sayed A, Saida AM. Local injection of autologous platelet rich plasma and corticosteroid in treatment of lateral epicondylitis and plantar fasciitis: randomized clinical trial. *Egypt Rheumatol*. 2012;34:43-9.
- Palacio EP, Schiavetti RR, Kanematsu M, Ikeda TM, Mizobuchi RR, Galbiatti JA. Effects of platelet-rich plasma on lateral epicondylitis of the elbow: Prospective randomized controlled trial. *Rev Bras Ortop* 2016;51:90-5.