

MANAGEMENT OF PROXIMAL HUMERUS FRACTURE IN ADULTS WITH PHILOS PLATE FIXATION IN NEER TYPE 2 AND TYPE 3

ANKUR KAKATI*, SHIVAM GARG, RAHUL RATHI, LAXMI NARAYAN MEENA*, RAVIKANT MAHARIA

Department of Orthopaedics, Pacific Institute of Medical Sciences, Udaipur, Rajasthan, India.

E-mail: ankurkakati007@gmail.com; Drlaxminarayan097@gmail.com

Received: 12 August 2022, Revised and Accepted: 20 September 2022

ABSTRACT

Objective: One of the most frequent bone fractures is a fracture of the proximal humerus. They make up between 4% and 5% of all fracture. With less invasive soft-tissue injury and a lower risk of iatrogenic avascular necrosis, closed reduction and percutaneous fixation have become more popular in recent years as opposed to open reduction (OR) and extensive internal fixation (IF) (by plates and screws).

The aim of this study was to compare the functional results of proximal humerus locking osteosynthesis (PHILOS) fixation against OR and IF of proximal humerus fractures (2 and 3 Neer's classification).

Methodology: This study involved 40 patients, with a mean age of 53 and a range of ages from 18 to 55, with 2 and 3 part fractures according to Neer's classification. Patients were randomized to either group, with Group I type 2 fractures receiving OR and IF for 22 patients, and Group II (type 3 fractures) with 18 patients receiving PHILOS plate fixation, with function assessed using the CMS score.

Results: At 1 month, 3 months, and 6 months of follow-up, Group I's mean Visual analog scale (VAS) score decreased to 2.52, 2.10, and 1.22 and in Group II, 3.86, 2.64, and 2.41. The VAS score was reduced and function CMS score were significantly increased in Group I (80% VAS score, 65% CMS score) as compared to Group II (64% VAS score, and 58% CMS score). At 1, 3, and 6 months, there was a statistically significant difference between the two groups.

Conclusion: Both groups saw satisfactory results, with each method having benefits and drawbacks. We discovered that plate fixation provided stable fixation with few implant problems and early range-of-motion exercise to achieve acceptable functional results.

Keywords: Humerus fractures, PHILOS plating, Neer's classification.

© 2022 The Authors. Published by Innovare Academic Sciences Pvt Ltd. This is an open access article under the CC BY license (<http://creativecommons.org/licenses/by/4.0/>) DOI: <http://dx.doi.org/10.22159/ajpcr.2022v15i10.46417>. Journal homepage: <https://innovareacademics.in/journals/index.php/ajpcr>

INTRODUCTION

One of the most frequent fractures in the human body, accounting for 4–5% of all fractures, is a fracture of the proximal humerus. Due to osteoporosis and decreasing bone density, the incidence of this fracture is higher among the elderly. In contrast, it can happen in younger age groups after high-velocity trauma. The majority of proximal humeral fractures have been treated non-operatively over the past century. In about 80–85% of cases of proximal humeral fractures, non-operative treatment has positive functional results [1-3].

Poor functional outcomes and non-union or mal-union can arise from conservative treatment of displaced two- and three-part fractures. A suitable approach for fine reduction is open reduction (OR) with internal fixation (IF), although significant soft-tissue exposure during OR compromises the vasculature and increases the risk of humeral head avascular necrosis by double (AVN) [4,5].

About 13–16% of proximal humeral fractures are three- and four-part fractures. These displaced fractures can be treated with OR and fixation. For misplaced two- and three-part fractures, Neer advised OR and IF [6]. Poor technique is mostly to blame for the poor outcomes following OR and IF of three-part fractures. When the head of the humerus in a three- or four-part fracture or fracture dislocation is completely devoid of any blood supply, it can be replaced by a humeral prosthesis. However, stable reduction allowing for the early mobilization should be the aim of proximal humerus fracture fixation.

The present study compares the clinical and functional results of treating proximal humerus fractures using percutaneous proximal

humeral locking osteosynthesis (PHILOS) plating. In light of this, the research topic was chosen to see the effectiveness of closed reduction and IF with percutaneous PHILOS plates for proximal humerus fractures in the elderly. Furthermore, to compare, between 2 and 3 type fractures classified by Neer.

METHODOLOGY

This study was conducted at the Orthopedic Department, Pacific Institute of Medical Sciences, Udaipur, Rajasthan, India, from August 2021 to July 2022. It was a randomized and double-blind trial. Based on the patient's medical history and physical examination, the treatment of proximal humeral fractures were made.

All male and female patients over the age of 18 who need surgery for a displacement or comminution humerus fracture were eligible to participate in this study after giving their written consent and X-rays evidence were included in the study.

Age 18 years, pathological fractures, undisplaced fractures, and any medical condition that would preclude surgery or general anesthesia are the exclusion criteria (heart diseases, renal failure, or active chemotherapy). This prospective study compared the outcomes (radiological and functional) of percutaneous PHILOS plate fixation in adult patients with proximal humerus fractures.

The study comprised patients with proximal humeral fractures who were operated on within 2–5 days and who were between the ages of 18 and 55 and had displaced II- or III proximal humeral fractures according to the Neer classification and AO classification in patients.

Patients who have open fractures of the Gustillo types II and III and fractures in the same limb should be evaluated before skeletal maturity to accurately identify the potential, related neurovascular injury. The present study excluded patients with an acute infection, pathological fractures, non-unions, mal-unions, or delays in surgery.

Each patient underwent a shoulder trauma series that included anteroposterior (AP), axillary, and lateral scapular (Y view) radiographs, as well as a clinical examination, neurovascular examination, radiological examination, and a CT scan to assess articular involvement, degree of fracture displacement, and glenoid rim fractures. When axillary view is not possible, it was also useful.

All patients underwent the standard preoperative laboratory tests, which include a complete blood count, a random blood glucose reading, a bleeding profile, and testing for the function of the liver and kidneys.

Declaration of ethics for each pre-operative stage. Possible procedural complications during and after surgery.

Surgical strategy and data gathering

- Group I: (Plates fixation in type 2 fractures)
- Group II: (Plate fixation in type 3 fractures).

Sufferer position

The patients were positioned in a beach chair position, with a tiny sandbag beneath the shoulder and the injured shoulder resting beyond the operating table's border.

Application

An anterior approach was used to find the fracture, entailing a 12–15-cm skin incision from the coracoid process to the proximal humeral shaft (on the level of the axilla). The cephalic vein was bluntly severed between the deltoid and pectoralis muscles to expose the deltopectoral groove and the clavipectoral fascia. The route of the muscle fibers, the vein itself, and the adipose tissue around the vein can all be used to pinpoint the cephalic vein.

Microsoft Excel 2013 and GraphPad online software were used for the statistical analysis. The mean difference between the two groups was compared using an independent t-test, and the mean difference between the type1 and type 2 fractures in proximal humerus patients data was compared using a paired t-test. The effectiveness of PHILOS

plate fixation therapy of proximal fracture was compared using the t-test for variance.

RESULTS

Out of 40 patients, 22 patients were included in Group I (type 2 fractures) and 18 in Group II (type 3 fractures), and the outcomes were analyzed. The final study group included 28 male and 12 female patients. The patients in Groups I and II had respective mean ages of 53.33 and 50.00 years. Twenty-six patients' road traffic accidents (11 were in Group I and 15 in Group II) and 14 patients' Fall on floor accidents (seven were in Group I and seven in Group II) were both impacted.

The mean visual analog scale score in Group I and Group II before treatment was 6.12 and 6.86, respectively. At 1 month, 3 months, and 6 months of follow-up, Group I's mean score decreased to 2.52, 2.10, and 1.22 respectively. In Group II, the mean VAS was 3.86 at the 1 month mark, 2.64 at the 3-month mark, and 2.41 at the 6-month mark (Fig. 1). A statistically significant difference existed between the two groups at 1 month (p=0.0001), 3 months (p=0.04), and 6 months (p=0.0001). Score was decreased to 80% in Group I that is type 2 fractures and in Group II decrease in score was 64%. The Group I or type two fractured responded better than Group II (type 3 fractures).

Before treatment, the mean CMS score (Constant and Murley score) for Groups I and II were 58 and 56, respectively. At 1 month, 3 months, and 6 months after the intervention, the score reduced to 76 in Group I and 72 in Group II, respectively (Table 3). At the 1 month, 3 months and 6-month follow-up, the difference between the two groups was statistically highly significant (p=0.0001 in 1 month, p=0.005 in 3 month and p=0.004 in 6 months follow-up of patients).

Before and after treatment, both groups had comparable X-rays. The pain score was reduced and function CMS score were significantly increased in Group I (65%) as compared to Group II (58%) (Table 3).

Table 1: Demographic characters of patients

	Group I (Type 2 fractures) (N=18)		Group II (Type 3 fractures) (N=22)	
	Number	Percentage	Number	Percentage
Male	12	66.66	16	72
Female	06	33.33	06	27
Age (years)	53.33	----	50.00	----
Road traffic accidents	11	61	15	68
By Fall on Floor	07	39	07	32

Table 2: The VAS score in Group I (Type 2) and Group II (Type 3) proximal humerus fractures

VAS	Group I (Type 2 fractures) (N=22)	Group II (Type 3 fractures) (N=18)	p-value Group I and II
Pre-treatment	6.12±1.02	6.86±1.15	0.03
1 month	2.52±1.06	3.86±0.84	0.0001
3 months	2.10±0.70	2.64±0.92	0.04
6 months	1.22±0.53	2.41±0.46	0.0001
% decrease in score	80%	64%	

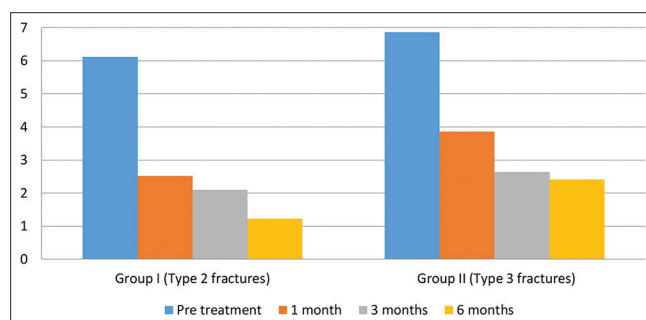


Fig. 1: The VAS score in Group I (Type 2) and Group II (Type 3) proximal humerus fractures

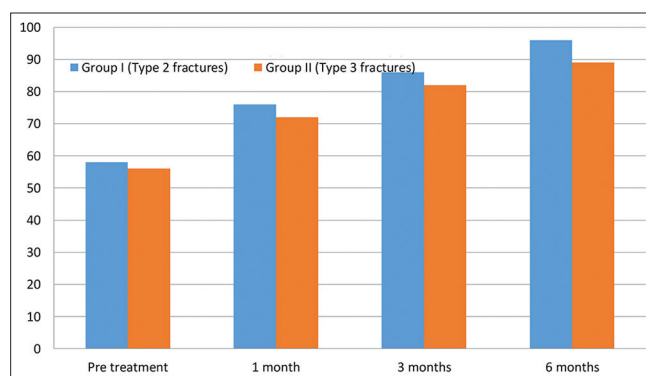


Fig. 2: The CMS Score in Group I (type 2) and Group II (type 3) treated proximal humerus fractures

Table 3: The CMS (Constant and Murley score) in Group I (Type 2) and Group II (type 3) humerus fractures treated patients

CMS score	Group I (Type 2 fractures) Mean±SD (N=22)	Group II (Type 3 fractures) Mean±SD (N=18)	p-value Group I and II
Pre-treatment	58±6.01	56±5.0	0.001
1 month	76±5.6	72±4.03	0.0001
3 months	86±4.29	82±4.31	0.0057
6 months	96±5.4	89±4.23	0.0027
% increase in score	65%	58%	

At 6 months, there was a statistically significant difference between the two groups (p=0.0027).

DISCUSSION

Men are more susceptible to high-energy trauma than women that are why they experienced more complicated fractures in our study. Proximal humerus fractures are more frequent in older ladies, according to Western literature. This study included 26 of patients who had a history of a road traffic collision, in contrast to the majority of studies in western literature that view low energy falls as a more frequent cause of proximal humerus fractures. In the investigation, the ratio of high-energy to low-energy injury was 14 patients. According to the World Health Organization, India has the greatest rate of traffic accidents worldwide due to poor traffic management, which could explain the disparity. In addition, as a tertiary care facility, our hospital saw a higher percentage of patients with high-energy polytrauma [7].

To get functional and radiological results as close to normal as feasible, our surgical treatment goal was to achieve anatomical reduction and initiate early mobility. Non-operative treatment is quite difficult to achieve anatomical reduction, particularly in 3- and 4-part fractures. However, surgical anatomical reduction is now possible thanks to improvements in implant technologies. Conversely, in other circumstances where there is no anatomical reduction, the functional outcomes can still be adequate. Radiological anatomical reduction does not always lead to good functional outcomes [8].

In the investigation, the study discovered that anatomical decrease had no effect on CMS and VAS scores. The patient with a three-part fracture who had a 15° varus displacement in the non-operative group received the best CMS (100) and VAS (1) scores. In a randomized clinical trial of patients with displaced proximal humerus fractures, Rangan *et al.* discovered no difference between surgical treatment and non-surgical treatment in terms of patient-reported clinical outcomes over 2 years following fracture incidence. Despite the PROFHER study's larger size and superior design, comparable outcomes were achieved without data. This might be because our study is more realistic in terms of daily life due to the comparison with the healthy control group and the use of privacy objective evaluations. In contrast, Poeze *et al.* discovered that in the non-operative group, a trans scapular (Y) radiograph seen in the 1st week was a predictive finding for functional outcomes based on their analysis of 55 patients with mildly displaced proximal humerus fractures [9,10].

There are still unknown factors that influence the functional outcomes of proximal humerus fractures in addition to excellent anatomical fracture healing and effective physical therapy. With surgical treatment, additional issues such as incision infection and screw penetration were noted. The operation group had lower VAS scores, and this difference was statistically significant. The use of various implants for surgical stabilization is one of the potential causes of this variation. According to Lange *et al.*, there was no difference between the two groups' objective functioning results [11].

The treatment of two-part fractures is decided according to age, displacement, and angulation. There was no difference in the outcomes

of treating two-part fractures surgically or non-operatively, according to Lange *et al.*'s study using Targon nails. Similarly, Fjalestad and Hole, in their randomized controlled trial, found no better results with surgical treatment than conservative treatment for patients with displaced proximal humeral fracture at 2-year follow-up, while Tamimi *et al.*, who used percutaneous K-wiring in their study, determined that subjective functional results in the surgical group were much better. In our study, CMS scores were higher in the two-part fractures than three-part surgical group; this was statistically significant [12-14].

The incidence of AVN in the proximal humerus is doubled by extensive soft-tissue exposure during surgery. Percutaneous fixation provides the benefit of being minimally invasive, with less exposure and soft tissue stripping, which lowers the risk of AVN [15,16]. The study discovered that the operating group had increased joint range of motion, particularly for the shoulder, and hand grip strength. This might be as a result of the gentle reduction techniques for two-part fractures, which are simpler to treat than three part, as well as the lateral deltoid split approach, which does not harm the rotator cuff muscles, particularly the subscapularis muscle.

The study's drawback was the paltry amount of samples that we used. This is because not all patients could be contacted and some patients refused to participate in the trial. On the other hand, PHILOS plates might have had a favorable or negative impact on the surgical outcomes. Our adoption of the Neer's categorization is the final flaw in our analysis. It is based on the mechanism of injury or the level of the fracture line, but it also has low intra- and inter-observer reliability and ignores tuberosity displacement. However, because this classification system aids in directing therapy and classifying fracture patterns for study, surgeons continue to utilize it. Increased patient enrollment and prospective and randomized clinical trials can improve future investigations.

CONCLUSION

A safe method for treating displaced two- and three-part humerus fractures with good functional outcomes is PHILOS humerus plating. We did not report any complications in the group of 2- part fractures. Comparable to other reconstructive techniques documented in the literature, 3- part fracture complication rates are more closely correlated with patient age and bone quality than they are with a particular surgical technique or fixation device. The issue of the surgical indication in older patients is still up for debate, but in our opinion, their care should be organized in accordance with their general condition and functional requirements.

ACKNOWLEDGMENTS

The authors thank the academics whose works are referenced in the manuscript's references for their invaluable assistance.

AUTHORS' CONTRIBUTIONS

None

COMPETING INTERESTS

No conflicts of interest have been reported.

AUTHORS' FUNDING

No funding sources are available.

ETHICS CLEARANCE

The Institutional Ethics Committee provided the ethical clearance certificate.

REFERENCES

1. Palvanen M, Kannus P, Niemi S, Parkkari J. Update in the epidemiology of proximal humeral fractures. Clin Orthop Relat Res 2006;442:87-92.
2. Spence RJ. Fractures of the proximal humerus. Curr Opin Orthop 2003;14:269-80.

3. Baron JA, Barrett JA, Karagas MR. The epidemiology of peripheral fractures. *Bone* 1996;18:209S-13.
4. Court-Brown CM, Caesar B. Epidemiology of adult fractures: A review. *Injury* 2006;37:691-7.
5. Robinson CM, Page RS. Severely impacted valgus proximal humeral fractures. Results of operative treatment. *J Bone Joint Surg Am* 2003;85:1647-55.
6. Dheenadhayalan J, Prasad VD, Devendra A, Rajasekaran S. Correlation of radiological parameters to functional outcome in complex proximal humerus fracture fixation: A study of 127 cases. *J Orthop Surg (Hong Kong)* 2019;27:2309499019848166.
7. Lind T, Krøner K, Jensen J. The epidemiology of fractures of the proximal humerus. *Arch Orthop Trauma Surg* 1989;108:285-7.
8. Neer CS 2nd. Displaced proximal humeral fractures: Part I. classification and evaluation. 1970. *Clin Orthop Relat Res* 2006;442:77-82.
9. Rangan A, Handoll H, Brealey S, Jefferson L, Keding A, Martin BC, et al. Surgical vs nonsurgical treatment of adults with displaced fractures of the proximal humerus: The PROFHER randomized clinical trial. *JAMA* 2015;313:1037-47.
10. Poeze M, Lenssen AF, Van Empel JM, Verbruggen JP. Conservative management of proximal humeral fractures: Can poor functional outcome be related to standard transscapular radiographic evaluation? *J Shoulder Elbow Surg* 2010;19:273-81.
11. Lange M, Brandt D, Mittlmeier T, Gratl G. Proximal humeral fractures: Non-operative treatment versus intramedullary nailing in 2-, 3-and 4-part fractures. *Injury* 2016;47:S14-9.
12. Fjalestad T, Hole MO. Displaced proximal humeral fractures: Operative versus non-operative treatment--a 2-year extension of a randomized controlled trial. *Eur J Orthop Surg Traumatol* 2014;24:1067-73.
13. Tamimi I, Montesa G, Collado F, González D, Carnero P, Rojas F, et al. Displaced proximal humeral fractures: When is surgery necessary? *Injury* 2015;46:1921-9.
14. Yu Z, Zheng L, Wang Y, Zhang Y, Zhang X, Ma B. Functional and radiological evaluations of unstable displaced proximal humeral fractures treated with closed reduction and percutaneous pinning fixation. *Eur Surg Res* 2010;45:138-45.
15. Muncibi F, Paez DC, Matassi F, Carulli C, Nistri L, Innocenti M. Long term results of percutaneous fixation of proximal humerus fractures. *Indian J Orthop* 2012;46:664-7.