

## A STUDY ON THE OCULAR MANIFESTATIONS OF ROAD TRAFFIC ACCIDENT CASES ATTENDING GOVERNMENT REGIONAL EYE HOSPITAL

RAJIV KRISHNA\*

Department of Ophthalmology, Andhra Medical College, Visakhapatnam, Andhra Pradesh, India. Email: ksrk9999@gmail.com

Received: 24 September 2022, Revised and Accepted: 30 October 2022

### ABSTRACT

**Objectives:** Road traffic accidents (RTA) are increasing day by day because of rapid increase in India's population resulting in a greater number of people commuting. Added to this due to busy schedules of both employees and students there is enormous rise in RTA. The aim of the study is to analyze various ocular manifestations of eye injuries due to RTA attending an eye hospital.

**Methods:** This study is cross-sectional study. 144 patients attending Regional Eye Hospital from January 2022 to June 2022 with various RTA were examined clinically by noting Best corrected visual acuity, Anterior segment, posterior segment examination, and Radiological imaging. Data were analyzed using Microsoft excel 2019 software.

**Results:** In this study, nearly 50% of subjects were in 16–35 years age group. Two-thirds in the study group were males. People from all walks of lives were involved in RTA. About 35% of the study group were commuting in a two-wheeler. More than 50% of the patients presented between 24 and 72 h after RTA. Majority of patients presented with some visual loss. Almost all the patients presented with some form of eyelids involvement like bruising or edema. Most common anterior segment finding was subconjunctival hemorrhage.

**Conclusion:** Ocular injuries due to RTA cause significant morbidity in certain individuals. Frequent commuters are more prone for RTA. Strictly abiding traffic rules and wearing protective gears will significantly reduce ocular trauma.

**Keywords:** Road traffic accidents, Ocular injury, Road safety measures.

© 2023 The Authors. Published by Innovare Academic Sciences Pvt Ltd. This is an open access article under the CC BY license (<http://creativecommons.org/licenses/by/4.0/>) DOI: <http://dx.doi.org/10.22159/ajpcr.2023v16i2.46438>. Journal homepage: <https://innovareacademics.in/journals/index.php/ajpcr>

### INTRODUCTION

Road traffic accidents (RTA) are common in everyday life. Increase in number of new vehicles, new drivers, various government schemes, and easily available loans are some of the factors for increased vehicular traffic [1]. Added to this busy schedule of students, employees and businessman require faster commuting leading to freak RTA. In developing countries like India, traffic rules are not followed properly and infrastructure is poor. The impact of RTA is devastating. It affects the victim, his/her family and ultimately society as a whole [2]. The WHO global data on RTA show road traffic injuries are the leading cause of death for children and young adults aged 5–29 years. Approximately 1.3 million people die each year as a result of road traffic crashes. More than half of all road traffic deaths are among vulnerable road users which include pedestrians, cyclists, and motorcyclists. About 93% of the world's fatalities on the roads occur in low- and middle-income countries, even though these countries have approximately 60% of the world's vehicles. Road traffic crashes cost most countries 3% of their gross domestic product. Between 20 and 50 million more people suffer non-fatal injuries, with many incurring a disability as a result of their injury [3].

This study aims to evaluate various ocular manifestations due to RTA at Government Regional Eye Hospital, Visakhapatnam, Andhra Pradesh, India which is a tertiary eye care center for North coastal Andhra Pradesh and Southern districts of Orissa.

### MATERIALS AND METHODS

This is a cross-sectional study. 144 patients attending Government Regional Eye hospital with injuries due to various RTA from January 2022 to June 2022 were studied. Informed consent from the patients taken. Data were analyzed using Microsoft excel 2019 software.

### Inclusion criteria

The following criteria were included in the study:

1. Patients who met with RTA and sustained ocular injuries.

### Exclusion criteria

1. Patients with ocular injuries due to other causes.
2. Patients with life threatening injuries.

Details of the RTA incident were taken from either the patient or the attendant. Best corrected visual acuity was noted in all the patients, anterior segment was examined with slit lamp, posterior segment was evaluated using indirect ophthalmoscopy. Imaging modalities like computed tomography/magnetic resonance imaging were ordered and analyzed where ever required and studied.

### RESULTS

Out of the 144 patients studied, 71 were in 16–35 years age group, followed by 35–60 age group (Fig. 1). Two-thirds of the patients in the study group were males (Fig. 2). People from all walks of lives were involved in RTA, frequent commuters more specifically are at high risk for obvious reasons (Fig. 3). About 35% of the study group were commuting in a two-wheeler, most of them were not using proper protective gear (Fig. 4). More than 50% of the patients presented between 24–72 h after RTA, one reason being this center is a referral center in this part of our state (Fig. 5). Majority of patients presented with some visual loss. Complete loss of vision was noted in 10 patients (Table 1). Majority of the patients presented with some form of eyelids involvement such as bruising or edema leading to black eye (Table 2). Most common anterior segment finding was subconjunctival hemorrhage (Table 3). Some patients also had posterior segment involvement also (Table 4).

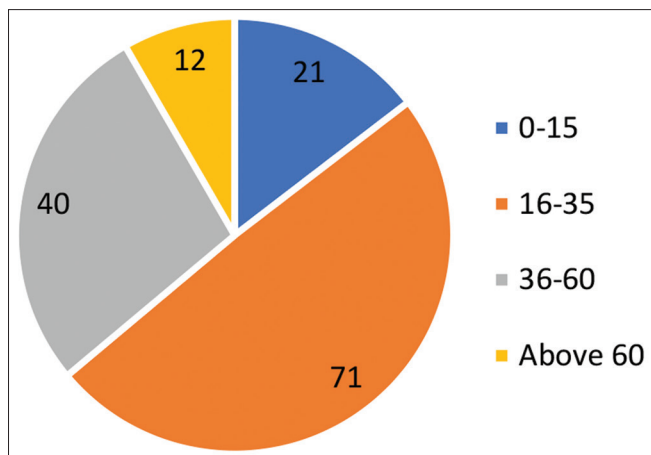


Fig. 1: Showing No. of patients in each group

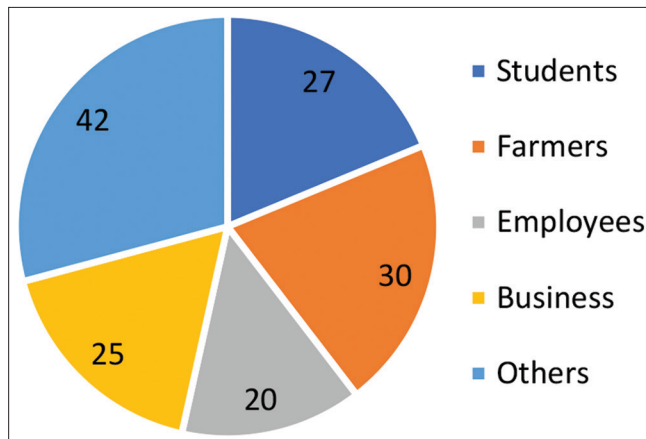


Fig. 3: Occupation wise distribution of the study population

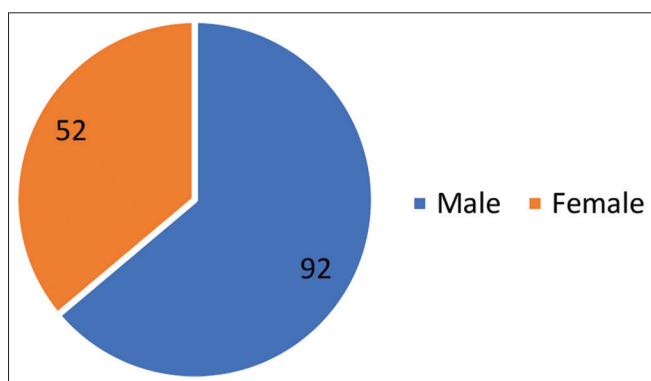


Fig. 2: Gender-wise distribution of the study population

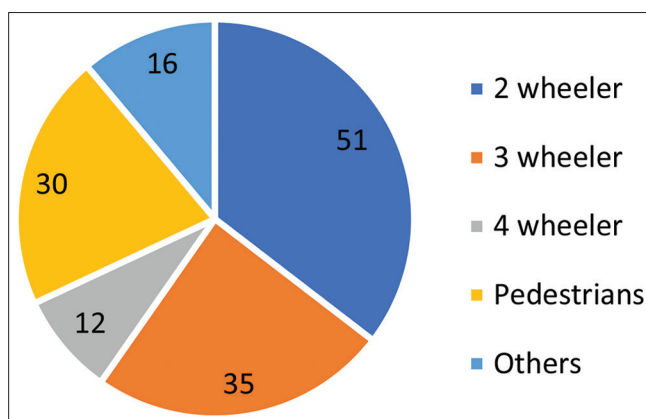


Fig. 4: Mode of travel by the patients

**DISCUSSION**

Eye is one of the most evolved sense organs in the human body. Any ocular injury especially after RTA which occur more commonly in young and breadwinning member of the family can cause severe loss to the individual, family as well as to the society.

Ocular trauma was classified using BETTS, Birmingham Eye Trauma Terminology [4] System as shown in the diagram below:

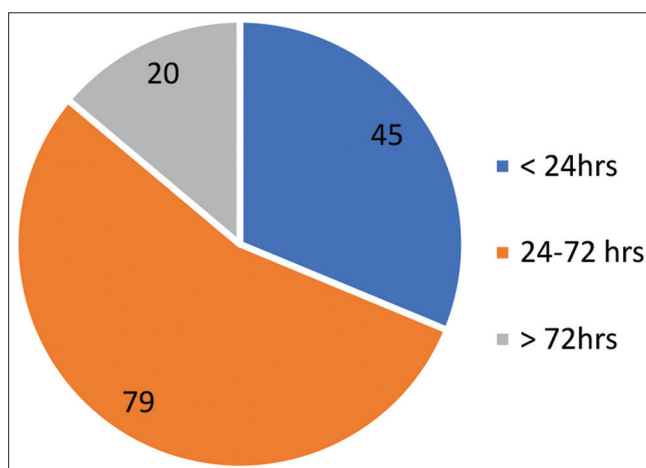
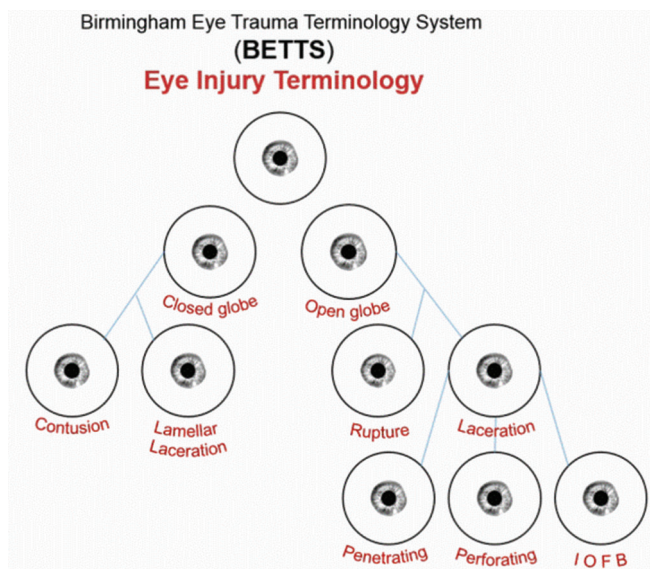


Fig. 5: The time at which patients presented after road traffic accidents

Young persons are getting involved in RTA due to their rash driving especially on motorcycles and not wearing helmets properly. Other risk factors noted are night driving and driving under the influence of alcohol or other drugs. Panagiotidis *et al.* [5] in their study on ocular injuries due to motor vehicle accidents concluded that ratio between men and women at 2.7:1 with the mean age of 31.7 years. Namala *et al.* [6] in their study showed two-wheeler riders are more prone for ocular injuries which are similar in this study. Das *et al.* [7] in their study showed students, farmers, business people, etc., who commute more frequently are more prone to ocular injuries related to RTA which is similar in the present study. Majority

**Table 1: Visual acuity of the patients who suffered RTA**

Visual acuity	No of patients
6/6-6/9	27
6/12-6/36	55
6/60-CF 1 mt	40
CF 1mt-PL+	12
No PL	10

RTA: Road traffic accidents

**Table 2: Type of extra ocular injuries noted**

Type of extra ocular injuries	No. of patients
Black eye	124
Eyelid lacerations	30
Orbital wall fractures	25
Nerve palsies	8

**Table 3: Type of anterior segment injuries**

Type of anterior segment injury	No. of patients
Conjunctival tears	33
Subconjunctival hemorrhage	95
Corneal abrasions	27
Corneal perforations	12
Scleral perforations	8
Hyphema	32
Iris injuries	30
Lens involvement	25

**Table 4: Type of posterior segment injuries**

Type of posterior segment injuries	No of patients
Vitreous hemorrhage	10
Comotio retina	15
Retinal detachment	3
Optic nerve injury	8
IOFB	2

of injuries in this study are closed globe injuries which are like the study done by Menon *et al.* [8]. In this study, common causes of fall of vision were corneo-scleral tears, Hyphema, vitreous hemorrhage, optic nerve injury, and Berlin's edema. Marudhamuthu *et al.* [9] observed similar causes of fall of vision in their study. Ajibode *et al.* [2] in their study showed 65.7% patients had extraocular and anterior segment involvement. In this study also majority of the patients presented with black eye and subconjunctival hemorrhage. Malik *et al.* [10] in their study on orbital fractures noted that majority of cases are due to RTA. 25 patients in this study had orbital fractures. Vitreous hemorrhage and commotio retinae were common clinical findings of posterior segment in this study. Similar findings were noticed in the study done by Shetgar *et al.* [11].

## CONCLUSION

Trauma to the eyes from RTA is one of the major causes of decreased vision. It is seen more commonly in males who commute frequently. Not following traffic rules, rash driving, drunk and driving, not wearing protective gear are the major causes of ocular trauma due to RTA.

Working groups on road safety in their reports to Government of India [12] proposed **4 E's Road Safety**:- The main thrust of accident prevention and control across the world has been on 4 E's vis (i) Education; (ii) Enforcement; (iii) Engineering; and (iv) Environment and Emergency care of road accident victims. The Government of India has been focusing on all these four approaches in its policies and program. If implemented by the government and citizens adhere to it road travel will become safe and enjoyable.

## ACKNOWLEDGMENTS

I sincerely thank administration of our Institute and all the patients who participated in this study.

## AUTHOR'S CONTRIBUTION

Dr. K. S. Rajiv Krishna, Assistant Professor of ophthalmology, GREH/AMC Visakhapatnam construed the idea, collected, and analyzed the data and drafted the article.

## CONFLICTS OF INTEREST

The author declares that they have no conflicts of interest

## AUTHORS FUNDING

The study was not supported by any grants or funds.

## REFERENCES

- Retallack AE, Ostendorf B. Current understanding of the effects of congestion on traffic accidents. *Int J Environ Res Public Health* 2019;16:3400. doi: 10.3390/ijerph16183400, PMID 31540246
- Ajibode HA, Thanni LO, Onabolu OO, Bodunde OT, Otulana TO. Eye injuries among road traffic accident victims in Ogun State, Nigeria. *Niger J Ophthalmol* 2009;17:55-8.
- World Health Organization. Road Traffic Injuries. Geneva: World Health Organization; 2022. Available from: <https://www.who.int/news-room/fact-sheets/detail/WHOfactsheets>
- Available from: [https://eyewiki.aao.org/w/index.php?title=birmingham\\_eye\\_trauma\\_terminology-\(bett\)oldid=81475](https://eyewiki.aao.org/w/index.php?title=birmingham_eye_trauma_terminology-(bett)oldid=81475)
- Panagiotidis DN, Theodossiadi PG, Petsias CB, Kyriaki TE, Marakis TP, Friberg TR, *et al.* Ocular injuries secondary to motor vehicle accidents. *Eur J Ophthalmol* 2004;14:144-8. doi: 10.1177/112067210401400210, PMID 15134112
- Namala B, Rao KS, Gurunadh VS. Road accidents and ocular injuries. *J Surg* 2019;1:13-6.
- Das D, Gupta S. A clinical study of road traffic accidents related ocular injuries in a rural tertiary care hospital. *Int J Sci Res* 2020;9:39-41.
- Menon L, Mani S, Mathew A. The prevalence of ocular manifestations in road traffic accidents treated at a rural tertiary care hospital in south India: A cross sectional study. *Int J Res Med Sci* 2017;5:4380-4. doi: 10.18203/2320-6012.ijrms20174562
- Marudhamuthu E, Sivakumar N, Kumaravel T. Study of ocular injuries in road traffic accident patients. *J Evol Med Dent Sci* 2017;6:3219-22. doi: 10.14260/Jemds/2017/697
- Malik TG, Khalil M, Farooq K. Broken bones and blind eyes: Ocular and orbital injuries in craniofacial trauma. *Pak J Med Health Sci* 2015;9:381-5.
- Padmaraj JM, Shetgar AC, Mallkarjunaswamy DL, Ramanna D, Venkatesh RH. Ocular injuries following road traffic accidents: A hospital-based case series study. *Indian J Clin Exp Ophthalmol* 2020;6:266-9. doi: 10.18231/j.ijceo.2020.057
- Government of India. Ministry of Road Transport and Highways. Available from: <https://morth.gov.in/reports-working-group-4-es-road-safety-0>