

CORRELATION OF ULTRASONOGRAPHY AND CT WITH HISTOPATHOLOGY IN DIAGNOSIS OF ACUTE APPENDICITISJASWINDER KAUR MOHI¹, POONAM TORAY^{1*}, ASHWANI KUMAR², AMANJEET KAUR³¹Department of Radiodiagnosis, Government Medical College and Rajindra Hospital, Patiala, Punjab, India. ²Department of Surgery, Rajindra Hospital, Patiala, Punjab, India. ³Department of Radiodiagnosis, Rajindra Hospital, Patiala, Punjab, India.*Corresponding author: Poonam Toray; Email: poonamtoray27@gmail.com

Received: 03 March 2023, Revised and Accepted: 27 April 2023

ABSTRACT

Objectives: The aim of the study was to compare the diagnostic accuracy of the ultrasound and contrast enhanced computed tomography scan in the diagnosis of acute appendicitis (AA) and subject all patients clinically suspected of AA to both ultrasound and computed tomography (CT) whole Abdomen.

Methods: It was a prospective and observational study carried on 50 patients with clinical diagnosis of AA, presenting to the surgery emergency ward and referred to Department of Radiodiagnosis, Rajindra Hospital, Patiala.

Results and Conclusions: CT scan has more diagnostic accuracy than ultrasonography. The accuracy of ultrasound was 84%, sensitivity: 89.13%, specificity: 75%, positive predictive value: 97%, negative predictive value: 37%. Comparing ultrasound and CT, our study showed better performance of CT with accuracy of 90%, sensitivity: 97.83%, specificity: 100%, PPV:100% and NPV: 80% respectively.

Key words: Appendicitis, Ultrasonography, Computed tomography, Diagnosis, Comparison, Correlation.

© 2023 The Authors. Published by Innovare Academic Sciences Pvt Ltd. This is an open access article under the CC BY license (<http://creativecommons.org/licenses/by/4.0/>) DOI: <http://dx.doi.org/10.22159/ajpcr.2023v16i9.47737>. Journal homepage: <https://innovareacademics.in/journals/index.php/ajpcr>

INTRODUCTION

Acute appendicitis (AA) is the most common surgical emergency. The typical presentation includes vague mid-abdominal pain, anorexia, and nausea, followed by, localized right lower quadrant (RLQ) abdominal pain, guarding, and leukocytosis. Such presentation of AA is easy to diagnose. The accuracy of clinical examination has been reported to range from 71% to 97% and varies greatly depending upon the experience of the examiner [1]. Patients with typical clinical findings undergo immediate surgery without radiological evaluation. Up to 45% of cases may have atypical symptoms and signs [2]. Variable positions of appendix, body habitus, gynecological disorders, immunocompromised status, old age, and children often give an atypical presentation of AA that poses a diagnostic dilemma for surgeons. Delay in the diagnosis of AA and a consequent delay in appendectomy can lead to complications such as perforation and peritonitis. Hence, to prevent perforation, the surgeons may adopt flexible criteria for surgery, which results in negative appendectomy rates of 15–22% [3]. Negative appendectomy rate is higher in young women (up to 45%) because of the prevalence of pelvic inflammatory disease and other common obstetrical/gynecological disorders [4]. Unnecessary surgery causes pain, potential complications, and loss of valuable health-care resources [5]. On the other hand, attempts to reduce the rate of unnecessary surgery often lead to unacceptable perforation rates. To balance perforation rates and negative appendectomy rates, radiological investigations play a key role in providing a conclusive diagnosis of AA without increasing the number of operation theatre cases.

METHODS**Study population**

A prospective and observational study was done on 50 patients admitted in the surgical emergency ward within the age group of 15–45 years presenting with clinical findings and symptoms of AA such as right iliac fossa pain, fever, and vomiting. All of them were subjected to both ultrasound and CT scans. Informed consent was taken from each participating patient.

Inclusion criteria

The following criteria were included in the study:

1. All patients presenting with right iliac fossa or periumbilical region pain, in whom the provisional diagnosis of AA is made.
2. Patients who were willing to give consent for their inclusion in the study.
3. Patients who have undergone both ultrasound and CT.

Exclusion criteria

The following criteria were excluded from the study:

1. Patient with a clear diagnosis of acute abdomen conditions other than appendicitis.
2. Pregnant women.
3. Patients <15 years.
4. Patients not willing to give consent.
5. Patients only undergoing either ultrasound or CT imaging.

Technique**Ultrasonography (USG) protocol**

A routine USG was done using an ultrasound machine Philips EPIQ Serial no. US 318 C0517 using C 5-1 convex probe L12-3 linear probe for upper abdomen and pelvis to rule out alternative diagnosis related to solid organs and to rule out the free fluid. Then, graded compression and color Doppler sonography of the RLQ giving attention to the site of maximal tenderness were performed. The normal appendix was visualized as a blind-ending loop with no peristalsis. The graded compression technique is used to displace the bowel loops, allowing differentiation between an incompressible inflamed appendix and compressible normal bowel loops. The diagnosis of appendicitis was given when a blind ending, non compressible, tubular structure with diameter greater than 6mm was found. On Color Doppler, there was an increase in peripheral vascularity in the wall of the appendix due to mural inflammation. Additional findings such as appendicolith and periappendicular were recorded. Total time of 10-15 min on average

was taken. The USG findings were reported as positive, negative, and not visualized for AA.

CT protocol

Patients were instructed to come NPO. History, laboratory investigations, previous imaging records, and any prior history of allergic reactions were taken. 20 ml of ionic oral contrast diluted in 800–1000 ml of water was given to patients 1.5 h before the scan. Examinations were performed on GE Medical Systems Revolution EVO 128 slice MDCT machine of the abdomen and pelvis, from the xiphoid to the pubic symphysis, using 80–100 ml@ 2.5–3ml/s of non-ionic contrast material with 300 mg/ml concentration administered by pressure injector intravenously. The normal appendix, when visualized, was reported. The CT findings were reported as positive and negative. The criteria for appendicitis are similar to that of USG. Alternative diagnoses, when achieved, were reported.

Follow-up of the patients was done and results of ultrasound and CT were compared with surgical and histopathological findings.

Data analysis

Statistical analysis was performed using the IBM SPSS version 22.0, Chicago, Illinois, USA. Data were statistically described in terms of mean±standard deviation (SD), range, frequencies (no. of cases), and percentages. It was represented in the form of tables, pie, bar diagrams, and flow charts. Diagnostic statistics, namely, sensitivity, specificity, positive predictive value, negative predictive value, and accuracy were conducted.

Ethical considerations

Ethical clearance was received from Research and Ethical Committee, Government Medical College, Patiala. The study was approved by the Faculty of Medical Sciences, Baba Farid University of Health Sciences, Faridkot on December 15, 2021 (BFUHS/2K21p-TH/14774)

RESULTS

The majority of the patients were in the age group of 21-35 years. Mean age was 26.08±10.22 years.

Males (64%) were more affected than females (36%).

Out of total 50 cases, 42 cases were diagnosed as acute appendicitis on ultrasound and 8 patients were negative.

Sonographic findings were described according to the diagnostic criteria for acute appendicitis. Acutely inflamed appendix was non-compressible in 42 (84%) patients, 7 (14%) patients had a compressible appendix and the appendix was not visualized in 1 (2%) patient. The majority of the appendix diameters, 64%, belonged to the 6-10 mm group, with the mean diameter (±SD) being 8.56±2.99 mm. The majority of the wall thicknesses of the appendix (68 %) belonged to the 1-3 mm group, with the mean wall thickness (±SD) being 2.83±0.91 mm. Periappendiceal fluid was present in 9 (18%) patients and absent in 41 (82%) patients. Fat stranding was present in 31 (62%) and absent in 19 (38%) patients. Appendicolith was present in 1 (2%) and absent in 49 (98%) patients. Mural hyperemia was present in 38 (76%) patients and absent in 12 (24%) of patients.

Out of total 50 cases, 45 cases were diagnosed as acute appendicitis positive and 5 were negative on CECT abdomen. Out of those 5 patients, 2 patients were positive on ultrasound and 3 were negative on CT. The 2 patients that were positive on ultrasound, one patient had inflamed appendix on surgery and HPE and other patient had negative HPE.

Position of the appendix, Pelvic (most common) > retrocecal > pre-ileal > postileal (least common) on CECT abdomen.

CECT findings were also described according to the diagnostic criteria for acute appendicitis. The majority of appendix diameters (64%)

Table 1: Ultra sound in the diagnosis of acute appendicitis

Ultra sound	Frequency	Percentage
Positive	42	84
Negative	8	16
Total	50	100

Table 2: Sonographic findings in acute appendicitis

Sonographic findings	Frequency	Percentage
Compressibility		
Present	7	14
Not visualized	1	2
Absent	42	84
Max. diameter (mm)		
Visualized	49	98
Not Visualized	1	2
Wall thickness (mm)		
Visualized	49	98
Not Visualized	1	2
Periappendiceal fluid		
Present	9	18
Absent	41	82
Fat stranding		
Present	31	62
Absent	19	38
Appendicolith		
Present	1	2
Absent	49	98
Mural hyperemia		
Present	38	76
Absent	12	24

Table 3: CECT abdomen in diagnosis of acute appendicitis

CECT	Frequency	Percentage
Positive	45	90
Negative/normal	5	10
Total	50	100

Table 4: Position of appendix on CECT abdomen

Position of appendix	Frequency	Percentage
Pelvic	22	44
Retrocecal	16	32
Pre-ileal	7	14
Post-ileal	5	10
Total	50	100

Table 5: Diameter of appendix (mm) on CECT abdomen

Diameter (mm)	Frequency	Percentage
<6 mm	3	6
6–10 mm	32	64
10–15 mm	11	22
>15 mm	4	8
Total	50	100
Mean±SD	9.46±3.48	
Median	8.35	
Range	5.5–21.0	

belonged to the 6-10 mm group with a mean diameter of 9.46±3.48 (±SD). Wall enhancement was present in 43 (86%) and absent in 7 (14%) of patients. The majority of the wall thicknesses of the

Table 6: Wall thickness of appendix on CECT abdomen

Wall thickness (mm)	Frequency	Percentage
1-3 mm	29	58
3-5 mm	20	40
>5 mm	1	2
Total	50	100
Mean±SD	3.22±1.08	
Median	3.00	
Range	2.0-8.0	

Table 7: CECT findings in acute appendicitis

CECT findings	Frequency	Percentage
Wall enhancement		
Present	43	86
Absent	7	14
Appendicolith		
Present	8	16
Absent	42	84

Table 8: Periappendiceal inflammation on CECT abdomen

Periappendiceal inflammation	Frequency	Percentage
Fat stranding		
Present	39	78
Absent	11	22
Extraluminal fluid		
Present	13	26
Absent	37	74
Phlegmon		
Present	4	8
Absent	46	92
Abscess		
Present	2	4
Absent	48	96

Table 9: Surgical findings

Surgical findings	Frequency	Percentage
Inflamed Appendix	48	96
Normal	2	4
Total	50	100

Table 10: Histopathology findings

HPE	Frequency	Percentage
Inflamed Appendix	46	92
Normal	4	8
Total	50	100

Table 11: Correlation of ultra sound with CT

Ultrasound	CT		Total	X ²	p value
	Positive	Negative			
Positive	40 (95.24%)	2 (4.76%)	42 (100%)	8.003	0.005
Negative	5 (62.50%)	3 (37.50%)	8 (100%)		
Total	45 (90%)	5 (10%)	50 (100%)		

CT: Computed tomography

appendix (58 %) belonged to the 1-3 mm group, with the mean wall thickness (±SD) being was 3.22±1.08 mm on the CECT abdomen

Table 12: Correlation of ultra sound with HPE

Ultra sound	HPE		Total	X ²	p value
	Inflamed appendix	Normal			
Positive	41 (97.62%)	1 (2.38%)	42 (100%)	11.261	0.001
Normal	5 (62.50%)	3 (37.50%)	8 (100%)		
Total	46 (92%)	4 (8%)	50 (100%)		

Table 13: Correlation of CT with HPE

CT	HPE		Total	X ²	p value
	Inflamed appendix	Normal			
Positive	45 (100%)	0 (0%)	45 (100%)	39.130	0.001
Normal	1 (20%)	4 (80%)	5 (100%)		
Total	46 (92%)	4 (8%)	50 (100%)		

Table 14: Type of appendicitis

Type of appendicitis	Frequency	Percentage
Uncomplicated	46	92
Complicated	4	8
Total	50	100

Table 15: Comparison of CECT abdomen and USG

Statistical parameters	CT	USG
Accuracy	90%	84%
Sensitivity	97.83%	89.13%
Specificity	100%	75%
PPV	100%	97%
NPV	80%	37%

PPV: Positive predictive value, NPV: Negative predictive value

[Table 6]. Periappendiceal inflammation in the form of fat stranding, extraluminal fluid, phlegmon and abscess was also noted amongst cases. Fat stranding was present in 39 patients (78%) and absent in 11 (22%), extraluminal fluid was present in 13 patients (26%) and absent in 37 patients (74%). Phlegmon was present in 4 patients (8%) and absent in 37 patients (74%). Phlegmon was present in 4 patients (8%) and absent in 46 patients (92%). Abscess was present in 2 patients (4%) and absent in 48 patients (96%). Appendicolith was present in 8 (16%) and absent in 42 (84%) patients.

Additional findings were also detected on CECT abdomen, with a majority having no associated findings and others being hepatomegaly in 8 patients (16%), abdominal lymphadenopathy in 7 patients (14%), thickening of the terminal ileum, ileocecal junction and caecum in 7 patients (14%), mesenteric lymphadenopathy in 2 patients (4%). Other findings included ascites, collections in RIF, dilated common bile duct, fracture of bilateral pars interarticularis L5 vertebra, splenomegaly, ileocolitis, hydroureteronephrosis left undescended testis, left bifid ureter, liver abscess, renal concretions, right ureteric calculus with mild HDN, right VUJ calculus with mild HDN, sliding hiatus hernia, subacute intestinal obstruction and vesical calculus in each 1 patient (2%).

Contents of lumen were observed intraoperatively. 41 patients (82%) had fecal matter, 7 patients (14%) had appendicoliths, 1 patient (2%) had appendicolith with pus and 1 patient (2%) had only pus as a content of lumen.

Out of 50, 48 patients (96%) had inflamed and 2(4%) had normal appendixes intraoperatively on surgery.

Out of 48 inflamed appendixes on surgery, the US was able to correctly diagnose 41 cases, 7 cases were missed by the US .CT was able to correctly diagnose 44 cases, 4 cases were missed by CT.

Out of 50, 46 patients (92%) had inflamed and 4(8%) had normal appendixes on histopathological examination.

Out of total 46 inflamed appendixes on histopathology, Ultrasound was able to correctly diagnose 41 cases and CT 45 cases of acute appendicitis

Out of 50 cases, the US was able to diagnose acute appendicitis in 42 cases,8 cases were negative, Out of which 5 cases were missed by the US, which was diagnosed on CT.3 were negative on ultrasound and HPE.

Out of 50, uncomplicated appendicitis was seen in 46 cases and 4 had complicated appendicitis.

CT is more accurate, sensitive and specific than the US, with corresponding values of 90%, 97.83% and 100%, for CT and 84%, 89.13% and 75% for the US.

The negative appendectomy rate was 8%.

Most of the studies, including our study, have shown that CT has more sensitivity, specificity, negative predictive value and positive predictive value in diagnosing appendicitis. Based on the results of our study, CT is more accurate than the USG in the diagnosis of acute appendicitis. CT was able to detect complicated appendicitis better than the USG. However, USG is the first investigation of choice in children and young women. In doubtful results, CT should be used as a problem-solving tool in them.

In elderly and obese patients, CT can be the first modality of choice in diagnosing acute appendicitis.

In order to reduce radiation exposure during standard CT, Low- dose CT shows promising results in the future.

The Table 1 shows that the number of patients who were diagnosed positive for acute appendicitis was 42(84%) and negative were 8(16%) for acute appendicitis using US among the 50 patients.

The Table 2 shows sonographic findings in acute appendicitis, including compressibility, maximum diameter, wall thickness, periappendiceal fluid, fat stranding, appendicolith and mural hyperemia. 42 patients (84%) had a non-compressible appendix, 7(14%)patients had compressible appendix and appendix was not visualized in 1(2%) patients. In 49 (98%) patients,the maximum diameter and wall thickness of the appendix could be measured. Periappendiceal fluid was present in 9 patients(18%) and was absent in 41 patients(82%).Fat stranding was present in 31 patients(62%) and it was absent in 19 patients(38%). Appendicolith was seen only in 1 patient(2%).Mural hyperemia of the appendix was seen in 38 patients(76%) and not seen in 12 patients(24%).

The Table 3 shows the number of cases that were found positive on CECT. A total of 50 out of 45 were positive and 5 were negative.

The Table 4 shows the position of the appendix with pelvic (most common) >retrocecal>pre-ileal>postileal (least common) on the CECT abdomen.

The Table 5 shows the mean diameter(±SD) was 8.596±2.99 mm using US among the 50 patients. The range of diameter was between 5–18 mm.The majority of the appendix diameters 64%, belonged to the 6–10 mm group.

The Table 6 shows the mean wall thickness (±SD) was 3.22±1.08 mm on the CECT abdomen among the 50 patients. The range of wall thickness was between 2.0-8.0 mm. The majority of the wall thicknesses of the appendix (58%) belonged to the 1-3 mm group.

Table 7 shows the number of patients who had post contrast wall enhancement and presence of appendicolith. Wall enhancement was present in 43(86%)and absent in 7(14%)patients .Appendicolith was present in 8 and absent in 42 patients.

The Table 8 shows periappendiceal inflammation in the form of fat stranding, extraluminal fluid, phlegmon and abscess. Fat stranding was present in 39 patients (78%) and absent in 11patients (22%), extraluminal fluid was present in 13 patients (26%) and absent in 37 patients (74%). Phlegmon was present in 4 patients (8%) and absent in 46 patients (92%). Abscess was present in 2 patients (4%) and absent in 48 patients (96%).

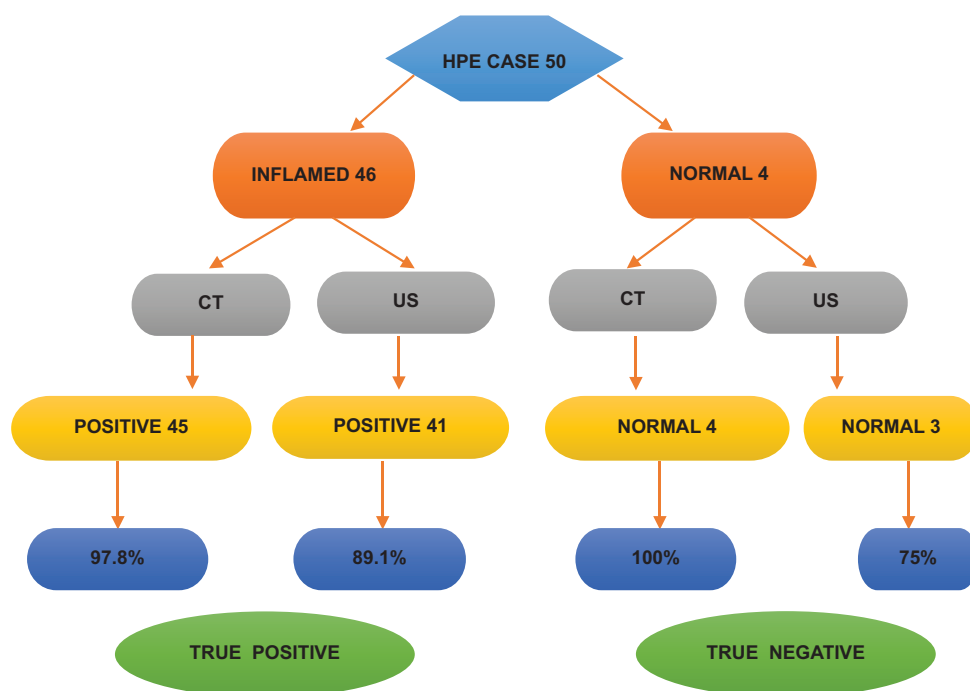


Fig. 1: Histopathology

The Table 9 shows the number of cases that were found positive for Surgery. Out of 50, 48 patients (96%) had inflamed and 2(4%) had normal appendixes.

The Table 10 shows the number of cases that were found positive on Histopathology. Out of 50, 46 patients (92%) had inflamed and 4(8%) had normal appendixes.

The Table 11 shows that out of 50 patients, 42 patients were positive and 8 were negative on ultrasound. On CT scan, 45 patients had positive findings and five were negative. 40 patients were true positive and 3 patients were true negative found in both, i.e., ultrasound and CT scan. Of the rest of the patients that 5 were negative on ultrasound but positive on CT and 2 were positive on ultrasound but negative on CT.

Tables 12 and 13 shows that out of 50 patients, ultrasound was negative in 8 patients. Out of these 8 patients, 5 patients were positive for acute appendicitis on CT and had a strong clinical suspicion of acute appendicitis. On surgery as well as on HPE inflamed appendix was found in these patients. On CT, 5 patients were negative for acute appendicitis. Out of these 5 patients, 2 patients were positive on ultrasound but negative on CT. Based on clinical and ultrasound findings, one patient was operated and inflamed appendix was found on surgery and HPE. Other patient had a borderline appendix measurement of 6mm and had a large liver abscess which is closely associated with appendicitis due to portal venous spread of infection. Abscess was drained. This patient had negative HPE. But after surgery this patient improved. In this patient underlying reason could be an early sub clinical appendicitis at microcellular level. 3 patients were true negative on ultrasound, CT and HPE. These patients were taken up for diagnostic laparoscopy. One patient was a case of recurrent attacks of right iliac fossa pain and on diagnostic laparoscopy this patient had few adhesions around appendix which were removed along with the appendix. Patient improved after surgery. This patient also right had right ureteric stone which could also be contributing to the pain in right iliac fossa. Two other patients had recurrent attacks of right iliac fossa pain and had high clinical suspicion of acute appendicitis, On diagnostic laparoscopy, inflamed appendix and salpingitis was found. The appendix was removed. HPE was negative. Out of these 2 patients, one patient had an additional finding of mesenteric lymphadenitis on CT [Table 12].

The Table 14 shows that out of 50 patients, 46 patients had uncomplicated appendicitis and 4 patients had complicated appendicitis.

The Table 15 shows that CECT is more accurate, sensitive and specific than Ultrasound.

DISCUSSION

AA is the acute inflammation of the vermiform appendix. It is one of the most common causes of abdominal pain that brings a patient to a surgical emergency. Clinically, AA may mimic various conditions leading to misdiagnosis. Clinical acumen, scores, and laboratory tests are not conclusive in the accurate diagnosis of AA. An incorrect diagnosis of appendicitis in patients with other causes of abdominal pain may result in the removal of a normal appendix and has significant clinical and cost implications [6]. Radiological imaging plays a crucial role in becoming an aide to the diagnosis of AA for operating surgeons. Imaging techniques are useful to prevent unnecessary appendectomies and to help avoid costly hospital admissions. Furthermore, imaging can expedite the diagnosis of appendicitis, minimizing surgical delays, and the subsequent risk of appendiceal perforation.

The optimal imaging approach should have several key characteristics. Imaging tests should be sensitive, specific, accurate, easy to perform with less discomfort, and complications/side effects for patients [7]. Out of imaging investigations, X-rays and Barium studies are becoming obsolete and rarely indicated. Whether to opt for an ultrasound or CT for patients presenting with AA remains a controversy.

Ultrasound is non-invasive, inexpensive, and has a great resolution power in the near field [8]. It allows a direct communication with the patient and orients specific questions when examining the region of maximum tenderness. Certain US findings may bring out a specific question to the patient. Ultrasound is strongly operator dependent; however, requiring expertise and there may be difficulties in identifying appendicitis when there is pain, obesity, overlying gas, or perforation. Several appendiceal imaging techniques have been advocated in the literature. Puylaert (1986) described a graded compression sonographic technique for appendiceal imaging and reported to be 83–96% accurate for the diagnosis of appendicitis [9]. Extending this technique to various maneuvers such as posterior manual compression, upward graded compression technique and left oblique lateral decubitus position are helpful in localizing an atypical position of appendix on the US.

CT has the ability to detect the normal appendix, (rules out the diagnosis of appendicitis), appendicoliths (especially when using helical CT), retrocecal appendicitis, and perforation with its complications and provides alternative diagnoses. The drawbacks include the increased cost of CT, the use of ionizing radiation, the need of contrast material (which is expensive), contrast-related adverse effects, and the time required to prepare the patient, to perform and analyze the scan.

Various CT protocols include unenhanced CT, focused CT, use of enteric contrast material, oral administration, use of IV contrast material, and unenhanced CT with selective use of contrast material. Our study used oral plus IV contrast protocol as its better than using only IV contrast, as proved by a study done by Wadhvani *et al.* (2015) [10].

The present study was conducted with the aim of comparing the diagnostic accuracy of routine CT scans and ultrasounds with histopathology as a gold standard. This study comprised of 50 patients who presented with clinical suspicion of AA who were examined by the surgeons and taken for surgery were taken in to study. Informed written consent was taken from all patients/attendants. The USG findings were reported as positive, negative/normal, or not visualized for AA. The contrast-enhanced CT report was reported as positive and negative/normal. Sonographic and CECT criteria for diagnosing AA were tabulated. Alternative diagnoses, when achieved, were reported. Surgery and histopathology findings were reported as an inflamed or normal appendix.

In our hospital, USG is the initial imaging study in patients clinically suspected of having appendicitis. In case of a suboptimal or inconclusive USG examination, we perform an intravenous plus oral contrast-enhanced CT scan.

Following are the Figs. 2-4 of few patients that were in study:

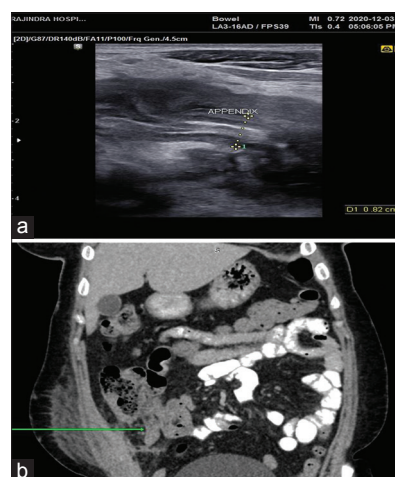


Fig. 2: (a) Ultrasound, (b) CECT abdomen coronal section

US findings

Positive for appendicitis, appendix measured ~8.2 mm, mural hyperemia, fat stranding, and fluid collection were seen.

CECT Findings

Positive for AA, appendix measured 11.5 mm, not opacified by contrast. A heterogeneous peripherally enhancing thick walled collection ms~2.5cmx2cmx0.8cm was seen in the right iliac fossa. Tip of appendix was not separately defined from this collection; s/o Periappendicular lump/abscess with extensive surrounding fat stranding, inflammatory changes, adhesions, and mild vascular congestion was seen. Adjacent anterior abdominal wall muscles and iliopsoas muscles posteriorly were thickened and edematous. Subcutaneous inflammatory changes were seen. Circumferential mural thickening of adjacent caecum and abdominal lymphadenopathy was noted.

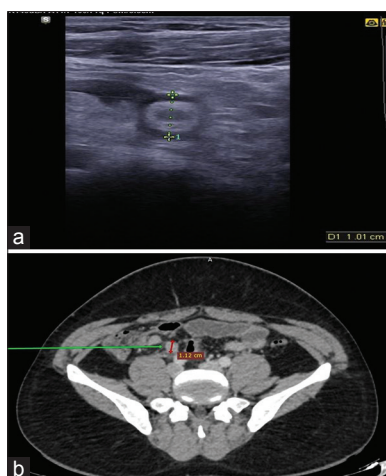


Fig. 3: (a) Ultrasound, (b) CECT abdomen axial section

US findings

Positive for appendicitis, appendix measured ~10 mm in diameter with minimal periappendiceal fluid and fat stranding.

CECT findings

Positive for AA, appendix measured 11 mm, post-ileal in position with enhancing wall ms ~5 mm, and periappendiceal fat stranding were seen. No appendicolith was seen. Mild hepatosplenomegaly was also noted.

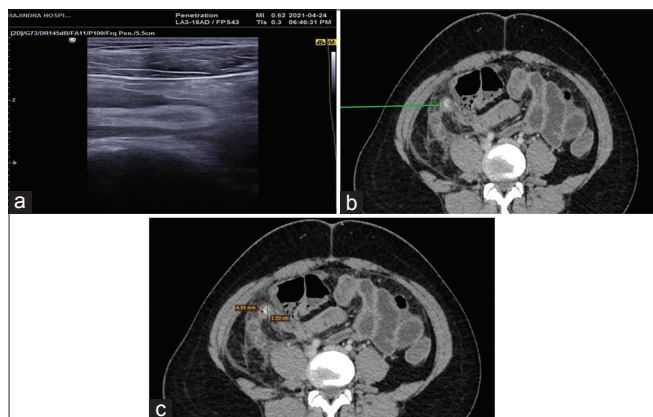


Fig. 4: (a) Ultrasound, (b) CECT abdomen axial section, (c) CECT abdomen axial section

US findings

Positive for AA, appendix measured ~14.7 mm minimal periappendiceal fluid, and fat stranding were noted.

CECT findings

Positive for AA, appendix measured 15 mm, retrocecal in position with enhancing wall ms ~4.6 mm. Periappendiceal fat stranding and minimal fluid were seen in right iliac fossa. Appendicolith ms ~7 mm was seen.

Age distribution

The mean age of presentation of cases in our study was 26.08±10.22 years. Maximum patients were in the age group of 21–35 years. The results of the present study can be compared with a study conducted by Raffa et al. which reported that the average age was 21–40 years [11].

Sex distribution

Our study had a male predominance which is similar to the study done by Alshebromi et al. [12].

Appendix position

The most common location of the appendix in our study was pelvic (44%), retrocecal (16%), preileal (14%), and post-ileal (10%). Same findings were found by Willekens et al. [13].

As US sensitivity is limited and non-diagnostic, US examinations with non-visualization of the appendix are more common. CT becomes the investigation of choice due to its higher sensitivity and specificity.

Comparison of imaging modalities

In the present study, the diagnostic accuracies of both US and CT imaging in diagnosing AA were compared. The US accuracy was 84%, sensitivity was 89.13% and specificity was 75%, positive predictive value (PPV) was 97%, and negative predictive value (NPV) was 37%. Comparing US to CT imaging, this study showed better performance for CT imaging which was 90% accurate, 97.83 sensitive, and 100% specific, with PPV of 100% and NPV of 80%. These findings were in line with the results obtained by Raffa et al. with accuracy, sensitivity, specificity, PPV, and NPV of US as 77%, 85%, 50%, 85%, and 50% and corresponding values in CT as 88.7%, 92%, 75%, 93.8%, and 69%.

The negative appendectomy rate of the present study is 8% which is in concordance with a study done by Krishnamoorthi et al., which had a negative appendectomy rate of 8.1% [14].

Similarly, Hwang reported the diagnostic pooled values for sensitivity, specificity, PPV, and NPV in US imaging were 86%, 94%, 100%, and 92%, respectively. Meanwhile, the respective values for CT imaging were 95%, 94%, 95%, and 99% [15]. In another study done by Alshebromi et al. reported that US imaging has a sensitivity of 37.0% and specificity of 100.0% while CT imaging has 86.0% and 16.7%, respectively.

A systematic review conducted by Karul et al. revealed that US imaging also had lower sensitivity and specificity than CT imaging, in general. For US imaging, the pooled sensitivity and specificity values ranged from 71.2–92.0% and 83.3–96.6%, respectively. For CT imaging, the respective pooled values ranged from 89.0–100.0% and 89.0–98.0% [16]. The same findings regarding the accuracy of the two were also obtained by Van Randen et al. in which the sensitivity of CT was higher at 94% compared to the 76% of sensitivity of US imaging [17].

Recently, low-dose CT has reported similar diagnostic efficiency in detecting AA when compared with the standard dose. Yi et al. compared ultrasound and standard-dose CT to a low-dose CT and found that low-dose CT is effective and relatively accurate for diagnosing AA in patients in childhood, adolescence, and young adults. A conclusion that low-dose CT may be a superior diagnostic tool when compared with USG and may be an alternative modality to standard CT for assessing pediatric patients suspected of having AA was made [18]. At our institute, how low dose CT fares are yet to be studied.

Attempts toward conservative treatment now require that CT to be used not only to diagnose the presence of appendicitis but also to differentiate complicated from uncomplicated appendicitis. CT

imaging features used for differentiating complicated appendicitis from uncomplicated appendicitis include abscess, extraluminal air, appendiceal wall enhancement defect, periappendiceal fat stranding, ileus, periappendiceal fluid collection, ascites, intraluminal air, extraluminal appendicolith, and intraluminal appendicolith [19]. Our study also detected a few of these features and differentiated between complicated and uncomplicated appendicitis.

Selection of imaging modality

US is widely used as the basic diagnostic technique and is considered a more viable choice for children, non-obese young adults, including women of reproductive age group. Transvaginal sonography is an added technological boon for diagnosing gynecological conditions mimicking AA [20]. However, the US usually gave an inconclusive result for older and obese patients [11].

CT imaging is considered a more applicable choice to some patients such as obese and older individuals, in which US imaging is not that clear. A study that demonstrated the effect of BMI on the accuracy of US and CT in diagnosing appendicitis in children also revealed that CT has better sensitivity of 96% and specificity of 97% compared to that of US, with an overall sensitivity of 38% and a comparable specificity of 97%. It was also observed that CT gave excellent accuracy regardless of BMI, while the US has a decreasing sensitivity with an increasing BMI [21].

It is recommended that inconclusive US imaging results should be verified through CT imaging [11,16]. This is further strengthened by WSES and European Association of Endoscopic Surgery guidelines, which also recommend that US scan as the first line of investigation and reserve CT scan in patients with inconclusive US findings. Such a strategy increases cost-effectiveness and reduces radiation exposure. CT scan may be a more appropriate first-line investigation in overweight or elderly patients [22].

Limitations

The body-mass-index (BMI) of the patients was not studied. It is well known that US has the difficulty in penetrating the fat; thus, the US findings might be equivocal for obese patients, in some patients.

The US findings may vary depending on the experience of the resident who performed the US scan. Being used for initial and urgent diagnosis, US is usually performed and reported by an unsupervised radiological resident rather than a consultant. In some literature, it was found that US results performed by an unsupervised resident gave a significantly lower sensitivity than that interpreted by a senior radiologist/consultant [23].

Children, <15 years and pregnant women were excluded from the study. We were unable to explore potential differences in accuracy between computed tomography (CT) and US in these groups.

The duration of the study and enrolment of patients was limited, so the results cannot be generalized. Further studies with larger sample size and longer duration are therefore warranted.

CONCLUSION

Considering the imaging technique, there comes a question of which is the best. Both US and CT have pros and cons. Usually, the USG is the first modality of choice, considering its easy availability, low cost, and reproducible with no radiation. However, it has its own pitfalls, being operator dependent, highly depending on the skill and experience of the radiologist who does the scan, and also other factors like the build of the patient and the various positions of the appendix make it difficult for the scanning radiologist to visualize the appendix. Sometimes USG also gives an equivocal finding wherein we are forced to switch over to CT. CT, on the other hand, is more specific than USG and hence could rule out appendicitis. Both the imaging techniques could give an alternate diagnosis if appendicitis is ruled out and have definitely reduced the rate of negative appendectomy in recent years.

Most of the studies, including our study, have shown that CT has more sensitivity, specificity, negative predictive value and positive predictive value in diagnosing appendicitis. Based on the results of our study, CT is more accurate than the USG in the diagnosis of AA. CT was able to detect complicated appendicitis better than the USG. However, USG is the first investigation of choice in children and young women. In doubtful results, CT should be used as a problem-solving tool in them.

In elderly and obese patients, CT can be the first modality of choice in diagnosing AA.

To reduce radiation exposure during standard CT, low-dose CT shows promising results in the future.

CONFLICTS OF INTEREST

The authors have declared that no competing interests existed.

AUTHOR CONTRIBUTIONS

Dr. Jaswinder Kaur Mohi, Dr. Poonam Toray, Dr. Amanjeet Kaur, and Dr. Ashwani Kumar. All contributed equally in the conduct of the study and the preparation of the manuscript.

FUNDING

This research received no specific grant from any funding agency in the public, commercial, or not for profit sectors.

REFERENCES

1. John H, Neff U, Kelemen M. Appendicitis diagnosis today: Clinical and ultrasonic deductions. *World J Surg* 1993;17:243-9. doi: 10.1007/BF01658936. PMID: 8511921
2. Poole GV. Appendicitis. The diagnostic challenge continues. *Am Surg* 1988;54:609-12. PMID: 3052200
3. Lau WY, Fan ST, Yiu TF, Chu KW, Wong SH. Negative findings at appendectomy. *Am J Surg* 1984;148:375-8. doi: 10.1016/0002-9610(84)90475-6. PMID: 6476229
4. Lewis FR, Holcroft JW, Boey J, Dunphy E. Appendicitis. A critical review of diagnosis and treatment in 1,000 cases. *Arch Surg* 1975;110:677-84. doi: 10.1001/archsurg.1975.01360110223039. PMID: 16566087
5. Deutsch AA, Shani N, Reiss R. Are some some appendectomies unnecessary? An analysis of 319 white appendices. *J R Coll Surg Edinb* 1983;28:35-40. PMID: 6834311
6. Lee SL, Walsh AJ, Ho HS. Computed tomography and ultrasonography do not improve and may delay the diagnosis and treatment of acute appendicitis. *Arch Surg* 2001;136:556-62. doi: 10.1001/archsurg.136.5.556. PMID: 11343547
7. Wise SW, Labuski MR, Kasales CJ, Blebea JS, Meilstrup JW, Holley GP, et al. Comparative assessment of CT and sonographic techniques for appendiceal imaging. *AJR Am J Roentgenol* 2001;176:933-41. doi: 10.2214/ajr.176.4.1760933. PMID: 11264081
8. Jeffrey RB Jr., Laing FC, Lewis FR. Acute appendicitis: High-resolution real-time US findings. *Radiology* 1987;163:11-4. doi: 10.1148/radiology.163.1.3547490. PMID: 3547490
9. Puylaert JB. Acute appendicitis: US evaluation using graded compression. *Radiology* 1986;158:355-60. doi: 10.1148/radiology.158.2.2934762. PMID: 2934762
10. Wadhvani A, Guo L, Saude E, Els H, Lang E, McRae A, et al. Intravenous and oral contrast vs intravenous contrast alone computed tomography for the visualization of appendix and diagnosis of appendicitis in adult emergency department patients. *Can Assoc Radiol J* 2016;67:234-41. doi: 10.1016/j.carj.2015.09.013. PMID: 27318889
11. Raffa A, Abduljabbar A, Alharthy A. Comparison of ultrasound and computed tomography scanning accuracy in diagnosing acute appendicitis at King Abdulaziz university hospital. *Cureus* 2022;14:e31880. doi: 10.7759/cureus.31880. PMID: 36440296; PMCID: PMC9693829
12. Alshebromi MH, Alsaigh SH, Aldhubayb MA. Sensitivity and specificity of computed tomography and ultrasound for the prediction of acute appendicitis at King Fahad Specialist Hospital in Buraidah, Saudi Arabia. *Saudi Med J* 2019;40:458-62. doi: 10.15537/smj.2019.5.23777. PMID: 31056622; PMCID: PMC6535167
13. Willekens I, Peeters E, De Maeseneer M, de Mey J. The normal appendix

- on CT: Does size matter? PLoS One 2014;9:e96476. doi: 10.1371/journal.pone.0096476. PMID: 24802879; PMCID: PMC4011757
14. Krishnamoorthi R, Ramarajan N, Wang NE, Newman B, Rubesova E, Mueller CM, *et al.* Effectiveness of a staged US and CT protocol for the diagnosis of pediatric appendicitis: Reducing radiation exposure in the age of ALARA. Radiology 2011;259:231-9. doi: 10.1148/radiol.10100984. PMID: 21324843
 15. Hwang ME. Sonography and computed tomography in diagnosing acute appendicitis. Radiol Technol 2018;89:224-37. PMID: 29298941
 16. Karul M, Berliner C, Keller S, Tsui TY, Yamamura J. Imaging of appendicitis in adults. Rofo 2014;186:551-8. doi: 10.1055/s-0034-1366074. PMID: 24760428
 17. Van Randen A, Laméris W, van Es HW, van Heesewijk HP, van Ramshorst B, Ten Hove W, *et al.* A comparison of the accuracy of ultrasound and computed tomography in common diagnoses causing acute abdominal pain. Eur Radiol 2011;21:1535-45. doi: 10.1007/s00330-011-2087-5. PMID: 21365197; PMCID: PMC3101356
 18. Yi DY, Lee KH, Park SB, Kim JT, Lee NM, Kim H, *et al.* Accuracy of low dose CT in the diagnosis of appendicitis in childhood and comparison with USG and standard dose CT. J Pediatr (Rio J) 2017;93:625-31. doi: 10.1016/j.jpeds.2017.01.004. PMID: 28445687
 19. Kim HY, Park JH, Lee YJ, Lee SS, Jeon JJ, Lee KH. Systematic review and meta-analysis of CT features for differentiating complicated and uncomplicated appendicitis. Radiology 2018;287:104-15. doi: 10.1148/radiol.2017171260. PMID: 29173071
 20. Debnath J, George RA, Ravikumar R. Imaging in acute appendicitis: What, when, and why? Med J Armed Forces India 2017;73:74-9. doi: 10.1016/j.mjafi.2016.02.005. PMID: 28123249; PMCID: PMC5221358
 21. Abo A, Shannon M, Taylor G, Bachur R. The influence of body mass index on the accuracy of ultrasound and computed tomography in diagnosing appendicitis in children. Pediatr Emerg Care 2011;27:731-6. doi: 10.1097/PEC.0b013e318226c8b0. PMID: 21811194
 22. Teng TZ, Thong XR, Lau KY, Balasubramaniam S, Shelat VG. Acute appendicitis-advances and controversies. World J Gastrointest Surg 2021;13:1293-314. doi: 10.4240/wjgs.v13.i11.1293. PMID: 34950421; PMCID: PMC8649565
 23. Laméris W, van Randen A, van Es HW, van Heesewijk JP, van Ramshorst B, Bouma WH, *et al.* Imaging strategies for detection of urgent conditions in patients with acute abdominal pain: Diagnostic accuracy study. BMJ 2009;338:b2431. doi: 10.1136/bmj.b2431. PMID: 19561056; PMCID: PMC3273785