

CLINICAL STUDY OF TOPICAL APPLICATION OF PLATELET-RICH PLASMA IN MANAGEMENT OF CHRONIC WOUNDS AT A TERTIARY CARE CENTER

MONIKA PAREEK, ASHOK KUMAR, DIWAN JAKHAR, SANJAY LODHA, NAVRATAN GAHLTOT*

Department of Surgery, Sardar Patel Medical College, Bikaner, Rajasthan, India.

*Corresponding author: Dr. Navratan GahlTOT; Email: gahlTOTn842@gmail.com

Received: 16 May 2023, Revised and Accepted: 29 June 2023

ABSTRACT

Objective: To study the efficacy and safety of platelet-rich plasma in the management of chronic wounds when applied locally.

Methods: A hospital-based prospective study was conducted on 30 cases with the diagnosis of a chronic wound and fulfilling inclusion criteria by convenience sampling presented to surgical OPD and emergency in the study period of 12 months (December 2021 to November 2022) at the Dept. of Surgery, S.P. Medical College, and P.B.M. Hospital, Bikaner.

Results: The mean age was 48.76 ± 5.65 years with male preponderance, and most of the cases were rural. 36.67% of cases presented in 6–12 months; 36.67% had traumatic etiology; 30% had diabetic; 26.67% had vascular; and 6.67% had burn etiology. 53.33% of cases had a lesion on the foot, and 22% of cases had joint involvement, with a mean size of an ulcer of 8.94 ± 2.14 cm². 73.33% of cases had partial healing, and 26.67% had complete healing. The mean duration for complete healing was 10.5 ± 3.4 weeks. Mean dressings were needed for the complete healing were 21.1 ± 5.9 dressings.

Conclusion: PRP was found to be useful in treating chronic ulcers. However, further controlled, randomized prospective clinical trials are necessary to definitively demonstrate its efficacy.

Keywords: Chronic wounds, Healing, Platelet rich plasma.

© 2023 The Authors. Published by Innovare Academic Sciences Pvt Ltd. This is an open access article under the CC BY license (<http://creativecommons.org/licenses/by/4.0/>) DOI: <http://dx.doi.org/10.22159/ajpcr.2023v16i12.48338>. Journal homepage: <https://innovareacademics.in/journals/index.php/ajpcr>

INTRODUCTION

Chronic wounds that refuse to heal pose a serious threat to the public's health and place a heavy financial strain on the healthcare system [1]. A wound is considered chronic if it takes longer than 3 weeks to heal, which is typical for that type of wound. In affluent nations, it is predicted that 1–2% of the population will encounter a chronic wound at some point in their lives [2]. These figures will rise due to the population's accelerated aging because age has a negative correlation with wound closure [3]. Indian studies on the epidemiology of chronic wounds are scarce, although one study put the frequency at 4.5/1000 people. At 10.5/1000 people, the frequency of acute wounds was more than double the national average [4].

These lesions are associated with considerable morbidity and death, with mortality rates from Stage IV pressure ulcers reaching 68.9% and patients with diabetic foot ulcers having a 6-fold greater risk of amputation [5].

Any treatment modality's principal objective is to quickly achieve wound closure. The standard course of treatment entails a sufficient amount of debridement, infection management, revascularization of ischemic tissue, and avoiding excessive pressure on the wound. Skin grafting has demonstrated some effectiveness, but it is unable to supply the required growth factors to control the healing [6]. Despite major healthcare resources being dedicated to wound care, non-healing wounds are linked to catastrophic side effects such as burn scars and disfigurement, amputation for diabetic foot ulcers, etc.

Known around the world, platelet-rich plasma (PRP) is a cutting-edge therapeutic approach. PRP is a source of growth factors, and as a result, it has mitogenic, angiogenic, and chemotactic qualities. This makes it an intriguing supplementary treatment option for wounds that are resistant to other methods. In addition, PRP supplies fibrinogen and other sticky proteins to the wound, both of which are necessary for the healing process [7]. PRP injections have been shown to be successful

in treating both acute and chronic ulcers. The upregulation of various cell-cycle regulatory proteins has been linked to increased rates of cell migration and proliferation [8].

Based on this background, platelet growth factors in the form of PRP started in the management of chronic ulcers and wounds, with variable but encouraging results necessitating the need for continued use and further studies into its effectiveness.

Aim

To study the efficacy and safety of PRP in the management of chronic wounds when applied locally.

METHODS

This hospital-based prospective study was conducted on 30 cases with the diagnosis of a chronic wound and meeting the inclusion criteria. The cases were presented to the surgical OPD and emergency department over the course of a 12-month period (December 2021 to November 2022) at the Department of Surgery, S.P. Medical College, and P.B.M. Hospital, Bikaner. Patients of both sexes and in the age range of 15–80 years who were diagnosed with chronic wounds lasting more than 3 weeks and who presented to the surgical department were all included in the study. Chronic wounds proved to be malignant by biopsy; pediatric age group patients; patients serologically positive for HIV, HCV, and HbsAg; patients with known or suspected osteomyelitis; acute chronic ischemia confirmed by color doppler or CT angiography were excluded from the study. All the patients with the diagnosis of the chronic wound were included in the study. The history recording was done and relevant biochemical and pathological investigations were done in all the cases. A radiological examination was done.

Autologous PRP

Around 20–40 mL of venous blood was collected in a vacutainer containing anticoagulant. RBCs are separated from platelets and

plasma by centrifuging at 2000 rpm for 10 min. The supernatant containing the plasma and platelets is aspirated and centrifuged at 5000 rpm for 5–10 min again. The lowermost layer, containing around 1.5 mL/10 mL, was taken and activated by adding 10% calcium chloride (0.3 mL for 1 mL of PRP). Following surgical debridement of the wound, the activated PRP obtained by the above technique was applied immediately over the ulcer, followed by dressing. The procedure was repeated twice a week for 12 weeks or until the ulcer healed, whichever was earliest.

As most of the ulcers are irregular in shape, the wound shape was considered to be elliptical, and the area was calculated with the formula: $\text{Area} = \text{length} \times \text{width} \times 0.7854$ [9].

Similarly, volume was calculated with the formula: $\text{Volume} = (\text{length} \times \text{width} \times 0.7854) \times \text{depth}$

According to the blood bank’s guidelines, PRP was created by centrifuging human blood taken from healthy donors. A 23-G needle was used to inject half of the PRP subcutaneously inside and around the edges of the wound or ulcer, then calcium gluconate (0.2 mL, 10%) was added to the remaining PRP to create gel sheet PRP, which forms a platelet gel that adheres to the wound’s surface. The patients were monitored for a period of 12 weeks following therapy, and the PRP injection and gel dressing were repeated twice weekly until a nearly full healing was obtained (1 cm at the widest length or breadth).

Wounds were measured at day 0 with tape in the two largest perpendicular diameters and multiplied to obtain the area in cm^2 , and initial photography was taken. Measurements of the ulcer size and photography were routinely taken on days 7, 14, 21, 28, and later every week until the healing of the wound. Deep tissue culture and systemic antibiotics according to culture sensitivity were given before starting the PRP therapy.

The study was initiated only after obtaining the necessary permissions, like permission from the ethics committee of the medical college. Informed consent was obtained from the study subjects.

Data analysis

The data were collected from the understudied population through a pretested and semi-structured questionnaire, which was designed in such a manner that more information regarding demographic profile, risk factors, and morbidity could be collected. Reasons for the study were explained to the patients; before interview, written consent was taken. The recorded data was compiled and entered in a spreadsheet computer program (Microsoft Excel 2010) and appropriate tests were applied. For all tests, confidence level and level of significance were set at 95% and 5%, respectively.

RESULTS

Maximum 50% were observed in 46–60 years, whereas minimum were 6.67% in 15–30 years age group. The mean age was 48.76 ± 5.65 years with male preponderance and most of cases were rural (Table 1).

All cases had wounds, and 30% had other complaints. 36.67% of cases presented in 6–12 months, whereas a minimum of 6.67% were in 1–3 months and >24 months. The mean duration of chief complaints was 9.54 ± 3.47 months. 53.33% of cases had a lesion on the foot, 22% had joint involvement, and 70% had serous or serosanguineous discharge (Table 2).

36.67% of cases had a traumatic etiology, 30% had a diabetic etiology, 26.67% had a vascular etiology, and 6.67% had a burn etiology (Fig. 1).

Maximum 30% of cases had an ulcer size of 11–20 cm^2 and >30 cm^2 , whereas minimum 16.67% had 1–10 cm^2 followed by 23.33% had 21–30 cm^2 , with a mean size of ulcer of 8.94 ± 2.14 cm^2 (Fig. 2).

Table 1: Socio-demography of study participants

Age (years)	No of patients	Percent
15–30	2	6.67
31–45	10	33.33
46–60	15	50.00
>60	3	10.00
Sex		
Male	21	70.00
Female	9	30.00
Residence		
Rural	24	80.00
Urban	6	20.00

Table 2: Chief complaints and location of wound among study participants

Chief complaints	No of patients	Percent
Wound	30	100.0
Other complaint	9	30.0
Location		
Foot	16	53.33
Leg	4	13.33
Hand	6	20.00
Forearm	4	13.33

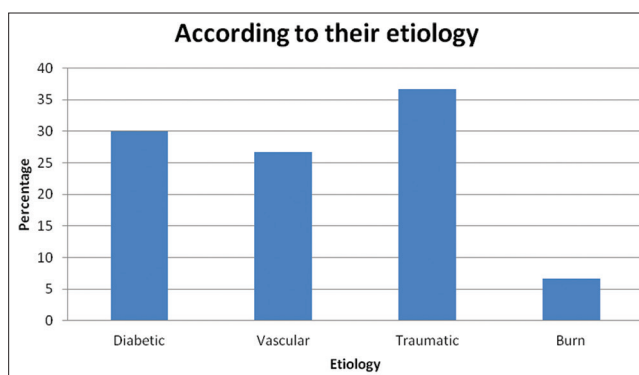


Fig. 1: Etiology of ulcer among study participants

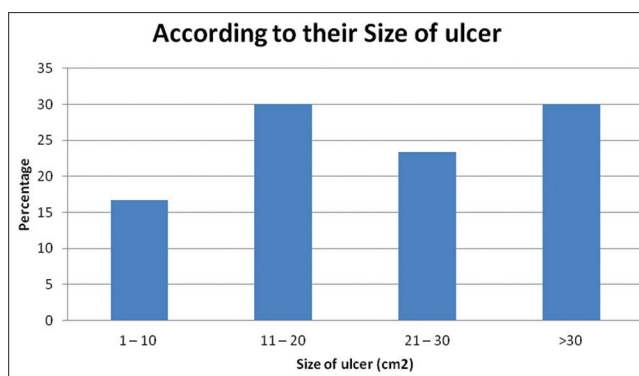


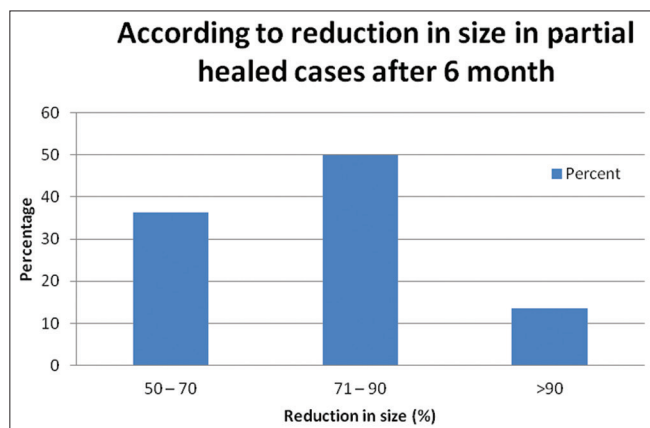
Fig. 2: Size of ulcer among study participants

73.33% of cases had partial healing, and 26.67% had complete healing. The mean duration for complete healing was 10.5 ± 3.4 weeks. The mean number of dressings needed for the complete healing was 21.1 ± 5.9 dressings (Table 3).

In our study, a maximum of 50% of cases had a 71–90% reduction in the size of the ulcer, whereas a minimum of 13.64% had a >90% reduction and 36.36% had a 50–70% reduction in the ulcer size (Fig. 3).

Table 3: Outcome of clinical condition

Outcome of clinical condition	No of patients	Percent
Partial healing	22	73.33
Complete healing	8	26.67
No healing	0	0.00
Duration (n=8)	10.5±3.4	
Dressing for healing (n=8)	21.1±5.9	

**Fig. 3. Reduction in size at 6 months in partial healed cases**

DISCUSSION

The intricate process of healing a wound requires cellular processes triggered by several mediators. PRP (platelet-concentrated plasma, plasma-rich growth factor, and autologous platelet gel) offers numerous platelets that are concentrated into a tiny volume of plasma. Plasma proteins such as fibrin, fibronectin, and vitronectin, as well as the growth factors produced by the granules of active platelets, are crucial in regulating tissue repair and regeneration.

The biochemical reactions that platelets set off during tissue repair and regeneration include directed chemotaxis, angiogenesis, cell proliferation, and cell differentiation. They are rich in cytokines and growth factors that are important for tissue repair and inflammation. Due to these properties, platelets have been proposed as a therapeutic agent to aid in wound healing, especially in individuals whose ability to regenerate tissue is impaired.

In our study, 26.67% of instances had full healing, whereas 73.33% of cases had partial healing. Similar to this, Prabhu *et al.* (2018) [10] discovered that 85 patients' non-healing ulcers (81.73%) were healed at the conclusion of the last dressing. Skin grafting was used to treat 13 patients' non-healing ulcers (12.5%). In addition, Bharathi and Tarun (2018) [11] discovered that in 4 cases (or 40%), the ulcers healed completely through re-epithelialization. Once the ulcer has properly granulated, six (or 60%) of the remaining ulcers are selected for skin transplantation. Furthermore, Aldein *et al.* (2021) [12] found that the rate of complete healing for ulcers in group A was achieved in six patients (40%) at the 5th week, while five patients (33.33%) were healed completely by the 6th week, and only one patient (6.67%) healed in the 9th week.

In our study, the average time for full healing was 10.5-3.4 weeks, and the average number of dressings required for full healing was 21.1-5.9. In a similar vein, Gopinath *et al.* (2019) [13] discovered that the average healing time was 7.512.9 weeks and that all ulcers resolved within a 12-week period. Within 6 weeks, 8 (24.24%) patients had fully recovered from their ulcer. In addition, Bharathi and Tarun (2018) [11] noted that the length of time needed for re-epithelialization to complete wound healing ranged from 6 weeks for one venous ulcer to 16 weeks for one diabetic foot ulcer.

In our study, the size of the ulcer was reduced in up to 50% of instances by 71-90%, a minimum of 13.64% by >90%, and 36.36% by 50-70%. Similar to this, Gopinath *et al.* (2019) [13] discovered that at the conclusion of 6 weeks, the total improvement in the area and volume of ulcers was 85.7% and 90.7% (median), respectively.

CONCLUSION

Chronic wounds are a common issue in underdeveloped nations since they frequently result in superinfection, are frequently difficult to heal, and lack the critical GFs for healing. The different GFs included in PRP are essential for wound healing. In addition, the PRP's high leukocyte content aids in the prevention of infections. Critical scientific facts about the advantages of PRP in clinical procedures are still few. PRP was discovered to be effective in the current study's treatment of chronic ulcers. To prove its effectiveness, however, additional controlled, randomized prospective clinical trials are required.

ACKNOWLEDGMENT

We owe a debt of gratitude to the SPMC for assistance during the course of the research.

AUTHORS' CONTRIBUTION

All the authors have contributed equally.

CONFLICT OF INTEREST

The authors declare no conflicts of interest.

AUTHOR'S FUNDING

The authors hereby state that they did not get any financial assistance for their research, writing, or publication of this paper.

REFERENCES

- Hersant B, Sid-Ahmed M, Braud L, Jourdan M, Baba-Amer Y, Meningaud JP, *et al.* Platelet-rich plasma improves the wound healing potential of mesenchymal stem cells through paracrine and metabolism alterations. *Stem Cells Int* 2019;2019:1234263. doi: 10.1155/2019/1234263, PMID 31781232
- Gottrup F. A specialized wound-healing center concept: Importance of a multidisciplinary department structure and surgical treatment facilities in the treatment of chronic wounds. *Am J Surg* 2004;187:38S-43S. doi: 10.1016/S0002-9610(03)00303-9, PMID 15147991
- Wicke C, Bachinger A, Coerper S, Beckert S, Witte MB, Königsrainer A. Aging influences wound healing in patients with chronic lower extremity wounds treated in a specialized wound care center. *Wound Repair Regen* 2009;17:25-33. doi: 10.1111/j.1524-475X.2008.00438.x, PMID 19152648
- Shukla VK, Ansari MA, Gupta SK. Wound healing research: A perspective from India. *Int J Low Extrem Wounds* 2005;4:7-8. doi: 10.1177/1534734604273660, PMID 15860447
- Davis WA, Norman PE, Bruce DG, Davis TM. Predictors, consequences and costs of diabetes-related lower extremity amputation complicating type 2 diabetes: The fremantle diabetes study. *Diabetologia* 2006;49:2634-41. doi: 10.1007/s00125-006-0431-0, PMID 17001469
- Lazaro JL, Izzo V, Meaume S, Davies AH, Lobmann R, Uccioli L. Elevated levels of matrix metalloproteinases and chronic wound healing: An updated review of clinical evidence. *J Wound Care* 2016;25:277-87. doi: 10.12968/jowc.2016.25.5.277, PMID 27169343
- Kim SA, Ryu HW, Lee KS, Cho JW. Application of platelet-rich plasma accelerates the wound healing process in acute and chronic ulcers through rapid migration and upregulation of cyclin A and CDK4 in HaCaT cells. *Mol Med Rep* 2013;7:476-80. doi: 10.3892/mmr.2012.1230, PMID 23242428
- Sarvajnamurthy S, Suryanarayan S, Budamakuntala L, Suresh DH. Autologous platelet rich plasma in chronic venous ulcers: Study of 17 cases. *J Cutan Aesthet Surg* 2013;6:97-9. doi: 10.4103/0974-2077.112671, PMID 24023432
- Carter MJ, Fylling CP, Parnell LK. Use of platelet rich plasma gel on wound healing: A systematic review and meta-analysis. *EPlasty* 2011;11:e38. PMID 22028946

10. Prabhu R, Vijayakumar C, Chandra AA, Balagurunathan K, Kalaiarasi R, Venkatesan K, *et al.* Efficacy of homologous, platelet-rich plasma dressing in chronic non-healing ulcers: An observational study. *Cureus* 2018;10:e2145. doi: 10.7759/cureus.2145, PMID 29632754
11. Bharathi MS, Tarun T. Role of platelet rich plasma [PRP] in the treatment of chronic wounds. *IJCMR* 2018;5:E13-6. doi: 10.21276/ijcmr.2018.5.5.39
12. Aldein HA, Salib WF, Nageeb RM, Mohamed AA, Radwan AF. Autologous platelet-rich plasma versus conventional dressing in treatment of chronic venous leg ulcers. *QJM An Int J Med* 2021;114:hcab097-002. doi: 10.1093/qjmed/hcab097.002
13. Gopinath VP, Simi VM, Ahammed KB, Farisa PM, Ali Rishad CM. Intralesional autologous platelet rich plasma therapy in chronic nonhealing cutaneous ulcers: An interventional study from a tertiary care centre in North Kerala. *Int J Res Dermatol* 2019;5:116-22. doi: 10.18203/issn.2455-4529.Intjresdermatol20185080