

COMPARISON OF LEVOBUPIVACAINE WITH TWO DIFFERENT ADJUVANTS (DEXAMETHASONE VS. DEXMEDETOMIDINE) IN ULTRASONOGRAPHY-GUIDED TRANSVERSUS ABDOMINIS PLANE BLOCK FOR UNILATERAL INGUINAL HERNIORRHAPHY: A RANDOMIZED DOUBLE-BLINDED CONTROL TRIAL

SEEMA PARTANI¹, SWATI KARIA², PRIYAM SHARMA³, CHARU SHARMA^{1*}, SAVITA CHOUDHARY¹, ANURAG KUMAR¹, YASH BAWEJA¹, VAISHALI CHAUHAN¹

¹Department of Anaesthesiology, Geetanjali Medical College and Hospital, Udaipur, Rajasthan, India. ²Department of Anaesthesiology, Pandit Deendayal Upadhyay Medical College and Hospital, Rajkot, Gujarat, India. ³Department of Anaesthesiology, Fortis Memorial and Research Institute, Gurgaon, Haryana, India.

*Corresponding author: Charu Sharma; Email: charusharma19@gmail.com

Received: 15 June 2023, Revised and Accepted: 29 July 2023

ABSTRACT

Objectives: Ultrasonography (USG)-guided transversus abdominis plane (TAP) block is an effective technique for postoperative analgesia in patients undergoing intraabdominal surgery. This study was aimed to compare the post-operative analgesia, hemodynamic variables, sedation, and adverse effects of levobupivacaine with two different adjuvants (dexamethasone and dexmedetomidine) in USG-guided TAP block for patients undergoing unilateral inguinal herniorrhaphy under subarachnoid block.

Methods: A double-blind randomized control study, conducted on 96 patients, allocated in three groups of 32 each. Patients in group C received 0.25% levobupivacaine (20 mL) with normal saline (2 mL), group D₁ received 0.25% levobupivacaine (20 mL) added with 0.1 mg/kg dexamethasone (2 mL) and group D₂ received 0.25% levobupivacaine added with 0.5 mcg/kg dexmedetomidine diluted in NS (2 mL). Pain was assessed using Visual Analog Scale (VAS). The time for request of first analgesia (TFA), total number and total dose of rescue analgesic in 24 h were recorded. Statistical analysis was done using unpaired Student's t-test and ANOVA.

Results: At 12 and 24 h >30% of patients had VAS ≥ 4 in control group while it was <10% in groups D₁ and D₂ ($p < 0.001$). TFA was earliest in control group (6.10 ± 0.96 h) as compared to group D₁ (7.26 ± 1.22 h) and group D₂ (7.49 ± 1.02 h) ($p < 0.001$). The total number and total dose of analgesic given were higher in the control group than other two groups ($p < 0.001$). However, it was comparable between groups D₁ and D₂ ($p < 0.05$).

Conclusion: Dexamethasone and dexmedetomidine when added as an adjuvant to levobupivacaine for TAP significantly prolonged the duration of post-operative analgesia as compared to levobupivacaine alone, however, it was found to be comparable between adjuvant groups.

Keywords: Ultrasonography guided transversus abdominis plane block, Postoperative analgesia, Levobupivacaine, Dexamethasone, Dexmedetomidine.

© 2024 The Authors. Published by Innovare Academic Sciences Pvt Ltd. This is an open access article under the CC BY license (<http://creativecommons.org/licenses/by/4.0/>) DOI: <http://dx.doi.org/10.22159/ajpcr.2024v17i1.48619>. Journal homepage: <https://innovareacademics.in/journals/index.php/ajpcr>

INTRODUCTION

Inguinal herniorrhaphy is a common day care surgical procedure, usually performed under regional anesthesia. Post-operative pain relief is challenging particularly during the immediate postoperative period to facilitate early mobilization and reduce the length of hospital stay. Inadequate control of pain can lead to adverse effects ranging from the discomfort of the patient to prolonged immobilization and thromboembolic phenomenon. Multimodal analgesia including regional nerve blocks is usually used as a part of opioid-sparing analgesic technique for pain management [1].

USG-guided transversus abdominis plane (TAP) block was first described by Hebbard *et al.* [2] Identification of the neurofascial plane between the internal oblique and transverse abdominis and deposition of local anesthetic in this plane inhibits the neural afferents from T7 to L1 and blocks the sensation from the skin, anterior abdominal wall, and parietal peritoneum [3].

Various local anesthetic along with different adjuvants has been used for peripheral nerve blocks to enhance the duration of postoperative analgesia. Levobupivacaine is the levorotatory isomer of bupivacaine and has a safer pharmacological profile with a reduced risk of cardiac and neurological adverse effects [4]. In literature search, we did not

reveal any study regarding the comparison of levobupivacaine with two different adjuvants (dexamethasone and dexmedetomidine) in USG-guided TAP block for post-operative analgesia.

This study aimed primarily to compare the postoperative analgesia in both groups in terms of pain measurement by visual analog score, time to first rescue analgesic and total number and total dose of rescue analgesic. Hemodynamic variables, Ramsay sedation score, adverse effects such as nausea, vomiting, shivering, sedation, pruritus, and any hematoma at the site of injection after block were considered as secondary objectives.

METHODS

This prospective double-blinded randomized study was conducted at a tertiary care center after obtaining approval from the Institutional Research Ethical Board and written informed consent. All patients of the American Society of Anaesthesiologists (ASA) class 1 and 2 between the age group of 18 and 60 years posted for unilateral inguinal hernia surgery under spinal anesthesia were included in the study. Patients with pre-existing cardiac disease, uncontrolled hypertension, asthma, diabetes mellitus, severe renal or hepatic dysfunction, chronic pain syndrome, obesity with body mass index above 35 kg/m², alcohol or drug abuse, infection at the site of injection, pain medications

within 24 h before surgery, contraindication of spinal anesthesia like coagulopathy, patients having a history of allergy to study drugs were excluded from the study. Those patients in which procedure was converted to general anesthesia were withdrawn from the study and were not included in the statistical analysis.

A total of 96 patients were randomly divided into three groups (C, D1, and D2) of 32 each. Computer-generated random number tables were used for randomization. Groups assigned were sealed within opaque envelopes to ensure blinding. The envelopes were opened by the principal administrator just before the administration of study drugs. Anesthesiologist who was not involved in the study and data collection prepared the study drugs according to the randomization group. The anesthesiologist who monitored and recorded the hemodynamic parameters, nurses, surgeon, research assistant, and the patient were blinded to the randomization. The study drug prepared for group C (control) contained 20 mL of 0.25% levobupivacaine with 2 mL of 0.9% normal saline (NS). Group D1: 20 mL of 0.25% levobupivacaine with 0.1 mg/kg dexamethasone (2 mL) and group D2 contained – 20 mL of 0.25% levobupivacaine with 0.5 mcg/kg dexmedetomidine diluted in NS to get 2 mL. The total volume was kept 22 mL in all three groups.

All patients were subjected to thorough preanesthetic evaluation and educated about methods of sensory and motor assessment, visual analog pain score of 0–10 (0–3=no pain, 4–7=discomfort, 8–10=severe pain) before study. Tablet alprazolam 0.5 mg and tab ranitidine 150 mg orally was given night before surgery. Patients were kept nil per oral 6 h before surgery. 18 G intravenous cannula in nondominant upper limb was inserted and an infusion of ringer lactate 6–8 mL/kg was started. Anesthetic and surgical techniques were standardized.

On arrival in operation theater, standard monitoring including electrocardiogram, non-invasive blood pressure, and pulse oximeter were attached. Baseline parameters such as heart rate (HR), systolic blood pressure (SBP), diastolic blood pressure (DBP), mean arterial pressure (MAP), and oxygen saturation (SPO₂) were recorded. Subarachnoid block (SAB) was performed at L3-L4 intervertebral space using 25 G quincke spinal needle and 12.5 mg of 0.5% bupivacaine heavy was injected. Surgery was allowed only when the adequate block height was achieved (T10).

At the end of surgery, USG-guided TAP block was given. After skin disinfection, the abdominal wall was scanned using a linear array transducer probe (6–13 MHz) in the multi-beam mode, connected to a portable ultrasound unit (Seiman Medical Solution USA). The edge of the probe was covered by a sterile plastic transducer sheath (Tegaderm) and a sterile gel was applied to the skin. The probe was placed in the mid-axillary line transversely to the lateral abdominal wall between the iliac crest and the subcoastal margin to obtain a transverse view of the abdominal layers. The 23 G spinal needle was inserted 2 cm medial to the transducer probe and advanced in-plane technique using ultrasonography (USG). The injection site was defined between aponeurosis of the internal oblique and the transversus abdominis muscles. 2 mL saline was injected to hydrodissect the tissue followed by injection of study drugs in 5 ml increments with intermittent aspiration. The hypochoic enlargement on USG confirmed the distribution of LA solution.

Data were recorded on a structured proforma. Demographic data such as age, sex, height, weight, ASA grade, and duration of surgery were noted. Hemodynamic parameters such as HR, SBP, DBP, MAP, and SPO₂ were recorded at the end of surgery (baseline) and after giving TAP block at various time intervals (10, 30, 60 min, and 2, 4, 6, 8, 10, 12 and 24 h). Any decrease in HR (below 55/bpm) was regarded as bradycardia and was treated with atropine 0.01 mg/kg intravenously. Decrease in mean blood pressure (below 20% of baseline) was regarded as hypotension and was treated by intravenous fluid bolus and if required inj. mephentermine 6 mg iv was given in increments.

Sensory blockade was assessed by pinprick method in a caudal to cephalic direction using a sterile 25 gauge blunt needle along the

mid-clavicular line bilaterally every 2 min for 10 min, then every 5 min till maximum height of sensory block was achieved. Time to reach T10 dermatome, i.e., time between injection of intrathecal drug and absence of pain in T10 dermatome and maximum height of sensory block was noted. Surgery was allowed after the T10 level was achieved. Sensory level at the time of giving TAP block was also noted.

If patients complained of pain during surgery aliquots of fentanyl 50 mcg IV (one or two doses) was administered (partial failure) and if the pain persisted general anesthesia was administered (complete failure). Patients with partial and complete failure were not analyzed statistically.

Postoperatively pain assessment was done using Visual Analog Scale (VAS) score (0–10) at different time intervals (30, 60, 90 min and 2, 3, 4, 5, 6, 8, 10, 12, 24 h). Time to first request for rescue analgesia or VAS \geq 4 was noted and Inj diclofenac 75 mg was given intravenously as rescue analgesic. The total number and total dose of analgesic required in 24 h were also noted. Ramsay sedation scale (RSS) was noted at the same intervals where VAS was noted. Incidences of postoperative side effects such as nausea, vomiting, bradycardia, hypotension, hypertension, shivering, bleeding at the site of injection, hematoma, and any other adverse effects such as headache and backache were recorded. Inj. ondansetron 4 mg iv was given for nausea and vomiting. The patient's satisfaction score was recorded at the time of discharge (<3= not satisfactory, 3–5 satisfactory, 5–7 good, 7–10 excellent).

Statistical Package for Social Sciences (SPSS) version 22 (SPSS, Chicago, IL) was used for statistical analysis. Quantitative data were analyzed using Student *t*-tests and ANOVA. Categorical data were analyzed using Chi-square test. $p < 0.05$ was considered statistically significant. The sample size was determined by power analysis with an alpha error 5% i.e. confidence level 95% and beta error to be 20%, i.e., power of study to be 80%. The minimum sample size was 30 in each group. With 6% clinically acceptable margin, we took 96 patients (considering dropouts) which were randomly divided into three groups of 32 each.

RESULTS

This prospective randomized double-blind study was conducted on 96 adult patients who underwent unilateral inguinal herniorrhaphy surgery under spinal anaesthesia. Out of these 2 patients in each group (total 6) were not included in statistical analysis because of failure of SAB (Fig. 1).

The patients in all three groups were comparable regarding demographic data and duration of surgery (Table 1).

VAS scores were <4 in all groups till 3 h postoperatively ($p > 0.05$). However, after that control group showed an increase in VAS score. At 5 h on movement the number of patients with VAS ≥ 4 was 33.3% in the control group while only 10% of patients were with VAS ≥ 4 in adjuvant groups ($p < 0.05$). At 12 and 24 h more than 30% of patients were with VAS ≥ 4 in the control group while it was $<10\%$ in adjuvant groups ($p < 0.001$) (Fig. 2a and b).

Time (h) of first rescue analgesic requirement was earliest in the control group (6.10 ± 0.96) as compared to adjuvants groups group D1 (7.26 ± 1.22) and group D2 (7.49 ± 1.02) ($p < 0.001$). The total number and total dose of analgesic given was also highest in the control group than other two groups ($p < 0.001$). However, it was comparable between adjuvant groups (D1 and D2) which was statistically nonsignificant ($p > 0.05$) (Table 2).

Perioperative hemodynamic changes were statistically insignificant between the three groups ($p > 0.05$) (Figs. 3 and 4).

No patients were found to have RSS ≥ 3 in any groups at any time intervals. The mean RSS was higher in patients who received dexmedetomidine however it was found to be statistically insignificant

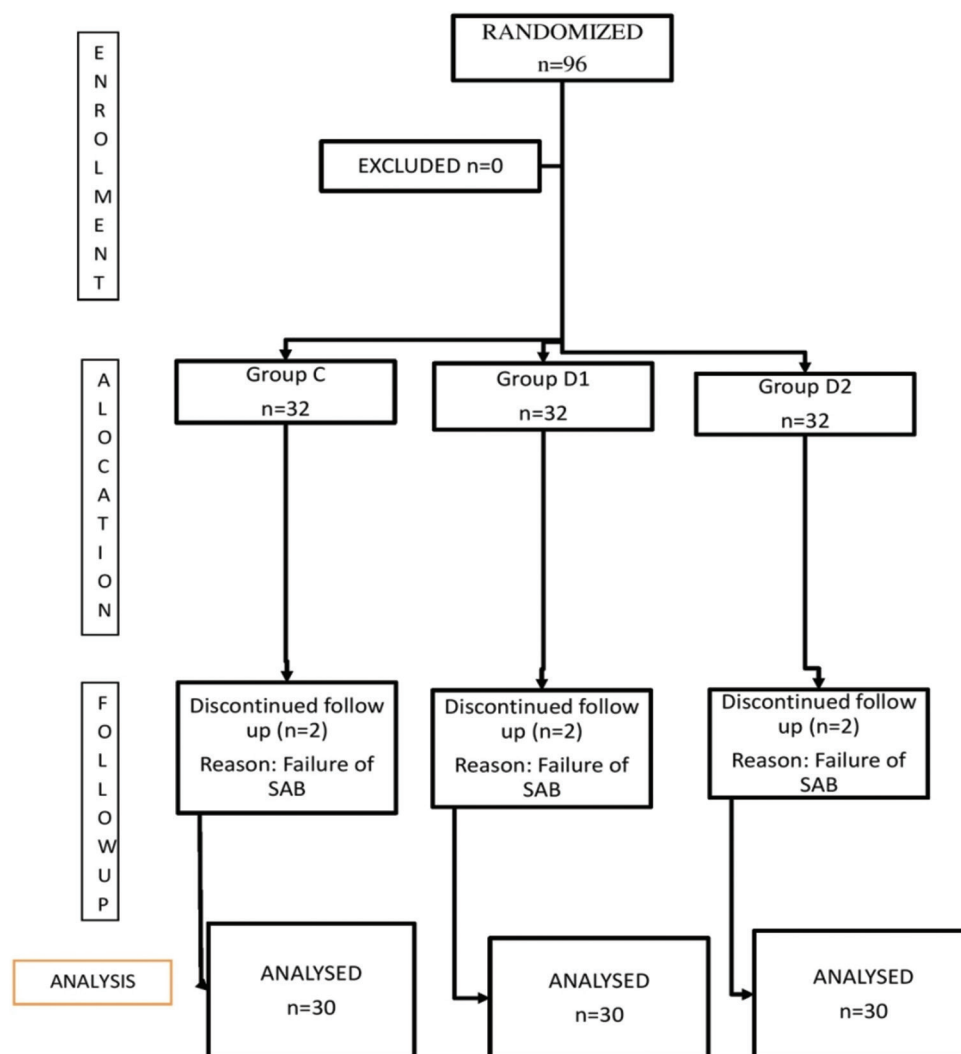


Fig. 1: Consort diagram showing patients allocation at different stages of the study

Table 1: Comparison of demographic data in between three groups

Variables	Group C (n=30) Mean±SD	Group D ₁ (n=30) Mean±SD	Group D ₂ (n=30) Mean±SD	p-value
Age (years)	44.60±11.15	40.47±9.32	42.07±11.25	>0.05
Weight (kgs)	69.67±5.37	63.60±4.23	66.20±4.76	>0.05
Height (cms)	167.30±5.87	167.57±5.83	168.50±5.65	>0.05
ASA status (I/II)	(16/14)	(20/10)	(17/13)	>0.05
Duration of surgery (minutes)	74.67±5.37	68.60±4.23	71.20±4.76	>0.05

($p > 0.05$). Majority of the patients in groups D1 and D2 were satisfied and reported excellent analgesia (>50%) than group C ($p > 0.001$). The number of patients having nausea and vomiting was more in group C (16%) than in group D2 (10%) and group D1 (6.6%).

DISCUSSION

Postoperative pain is experienced by majority of patients. Adequate control of pain plays an essential role in facilitating early recovery to normal function and improves patient satisfaction. A multimodal approach which includes the administration of two or more drugs through same or different routes, each acting at different sites of pain pathway has been suggested as the optimal combination for the pain relief along with reducing opioids requirements [5,6]. Recently USG guided transverses abdominis plane block (TAPB) has been performed as an alternative modality in abdominal surgeries with different drug

combinations for effective postoperative analgesia. The addition of adjuvants to the local anesthetics have been used to improve the quality and duration of analgesia in different peripheral nerve block techniques [7].

Dexmedetomidine, an imidazole compound is the pharmacologically active dextroisomer of medetomidine that exhibits selective alpha 2-adrenoceptor agonist action [8]. Activation of the receptors in the brain and spinal cord by dexmedetomidine inhibits neuronal firing, causing hypotension, bradycardia, sedation, and analgesia [9].

Dexamethasone, a glucocorticoid, is emerging as a potent adjunct to local anesthetic. It produces analgesia through its anti-inflammatory and immunosuppressive actions [10,11]. It acts locally on nociceptive C-fibers to increase the activity of inhibitory potassium channels [12].

Table 2: Comparison of requirement of Rescue analgesic between three groups

Variables	Group C (n=30) Mean±SD	Group D ₁ (n=30) Mean±SD	Group D ₂ (n=30) Mean±SD	p-value
Time to first rescue analgesic (h)	6.10±0.96	7.26±1.22	7.49±1.02	<0.001 (HS)
Total no. of rescue analgesic doses in 24 h (n)	2.33±0.48	1.97±0.32	1.93±0.25	<0.001 (HS)
Total dose of rescue analgesics in 24 h (mg)	175.00±36.0	147.50±23.99	145.00±19.03	<0.001 (HS)

Data=Mean±SD; HS=highlySignificant (p<0.001), Rescue analgesic inj. Diclofenac 75 mg

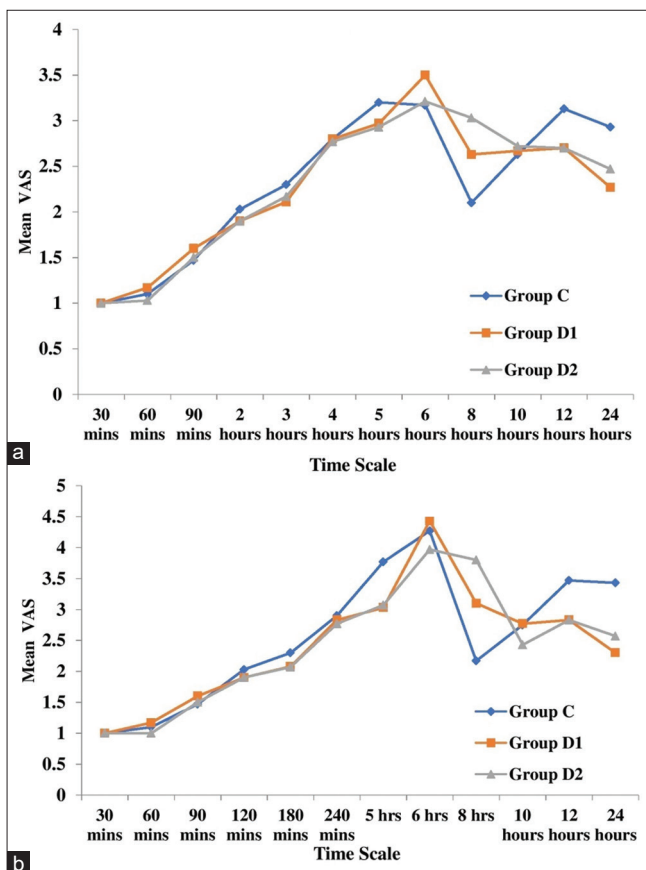


Fig. 2: (a) Graphical representation of changes in VAS on rest between three groups. (b) Graphical representation of changes in VAS on movement between three groups

The analgesic efficacy of dexmedetomidine and dexamethasone in different doses with different local anesthetics has been evaluated in various studies [13-16]. In the present study, all patients in three groups were comfortable (VAS<4) till 4 h postoperatively which may be due to the additive effect of SAB to TAP block. At 5 h, the number of patients with VAS ≥4 on movement were highest (33.3%) in the control group as compared to adjuvant groups (10%). Similarly, at later, postoperative period (12 and 24 h) higher VAS score (≥4) was observed in majority of patients in the control group than the patients who received adjuvant with local anesthetic. Studies done by Qian *et al.* [17] and Sharma *et al.* [18] also showed similar results where VAS scores were significantly lower in adjuvant groups at 6–24th h in comparison to the control group.

Diclofenac sodium 75 mg iv was given once the patient complained of pain (VAS≥4) as a rescue analgesic. The total dose of rescue analgesic required in 24 h was lowest in patients who received dexmedetomidine (145±19.03 mg) as compared to dexamethasone (147.50±23.99 mg) and levobupivacaine alone (175.00±36.00 mg) (p<0.05). However, it was comparable between adjuvant groups (p>0.05). These results are in consistent with observations of other authors in different studies [16,18,19].

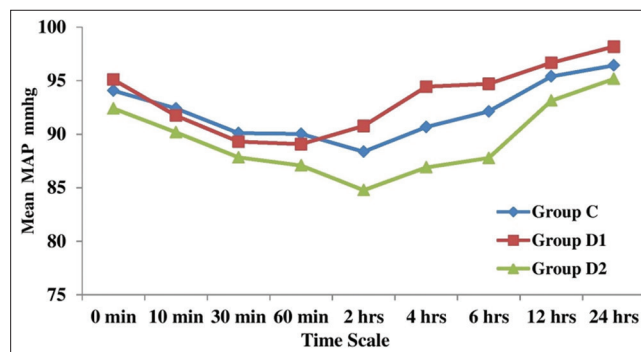


Fig. 3: Graphical representation of changes in mean arterial pressure between three groups

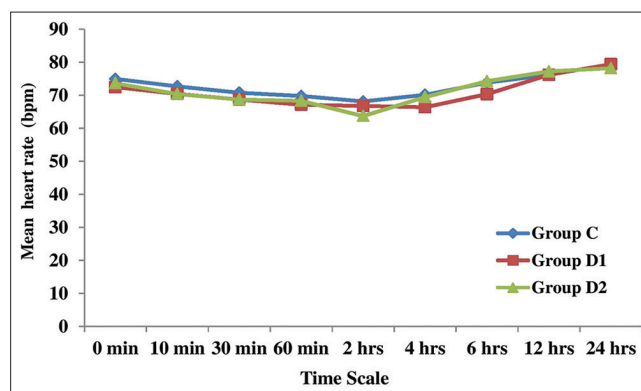


Fig. 4: Graphical representation of changes in heart rate between two groups

Time (hours) to request for first rescue analgesic (TFA) was earliest in the control group (6.10±0.96) than the patients receiving dexamethasone (7.26±1.22) and dexmedetomidine (7.49±1.02) which was found to be highly significant (p<0.001). The patients receiving dexamethasone and dexmedetomidine as an adjuvant were significantly pain-free for 76 min and 99 min respectively than the patients receiving levobupivacaine alone (p<0.001). However, it was found to be comparable between adjuvant groups (p>0.05). Similarly, other authors also found prolonged TFA when dexamethasone and dexmedetomidine were used as an adjuvant to LA in their studies [18,20,21]. However, Varshney *et al.* [13] and Parameswari *et al.* [14] reported prolonged TFA (10 h and 14 h respectively) in parturients receiving dexmedetomidine as an adjuvant in TAP block than the present study (7.49±1.02 h). Gupta *et al.* [15] also reported delayed TFA in parturients receiving dexmedetomidine as an adjuvant (19 h). The prolonged TFA in these studies may be attributed to intrathecal administration of 25 mcg fentanyl with local anesthetics along with administration of inj. paracetamol 1 g iv just before shifting to the recovery room. The results of above-mentioned studies strengthen the practice of multimodal analgesia.

In contrast to the present study, Singla *et al.* [1] reported the superiority of dexmedetomidine over dexamethasone as an adjunct to ropivacaine in TAP block which can be attributed to higher dose of dexmedetomidine (1mcg/kg) used in their study.

All patients were hemodynamically stable in three groups in the present study ($p>0.05$), however, the incidence of bradycardia was recorded more in patients receiving dexmedetomidine (10%) than dexamethasone (3.3%) and none of the patient in the control group. This can be explained by the action of dexmedetomidine on presynaptically mediated inhibition of norepinephrine release at the neuroreceptor junction and its vagomimetic action. These effects are more significant when given intravenously than with other routes. Similar results were also observed by other authors in their studies [14,17].

Dexmedetomidine also has anxiolytic and sedative effects which can be beneficial in patients undergoing long-duration surgeries, while higher sedation scores may be harmful in elderly and high-risk patients owing to risk of respiratory depression [22]. In the present study Ramsay Sedation Score (RSS) was compared amongst three groups at different time intervals which was found to be statistically insignificant ($p>0.05$). However, patients who received dexmedetomidine had increased mean RSS as compared to the control and dexamethasone group. Similarly higher sedation score in patients receiving dexmedetomidine as adjuvant was also reported in different studies [14,21,23].

Incidence of complications is more in blind TAP block technique than USG-guided TAP blocks. USG-guided drug administration allows accurate deposition of local anesthetic in the correct neurovascular plane and avoid procedure-related complications such as injury to surrounding viscera, transient femoral nerve palsy, and high volume of drug used which can cross the serum toxic levels [23-25].

The number of patients having nausea and vomiting was more in control group (16%) than in patients receiving dexmedetomidine (10%) and dexamethasone (6.6%). Gupta *et al.* [15], Deshpande *et al.* [16], and Seervi *et al.* [19] also reported decreased incidence of nausea and vomiting in the dexamethasone group. The antiemetic effect of dexamethasone can be attributed to its anti-inflammatory effect or direct central action at the solitary tract nucleus [26]. Shivering was observed in 10% of patients of group C while it was only 6.6% in adjuvants groups ($p>0.05$). Other side effects such as headache and backache were also reported in group C (16%) while it was 13% in each adjuvant group which could be due to the SAB. No other drug or procedure-related side effects like injury to surrounding viscera, hematoma, or LA toxicity were not reported in any group. The observations of other studies [15,18,20] are in accordance to present study which strengthens the efficacy and safety of USG-guided TAP block.

In the present study, all patients were satisfied regarding postoperative analgesia. However, majority of patients in group D1 and D2 reported excellent analgesia (>50%) than group C (13%). Similarly, studies were done by Sachdeva and Sinha [20] and Abdelaal *et al.* [5] also reported that the addition of dexmedetomidine and dexamethasone as adjuvant in TAPB resulted in excellent patient satisfaction score as compared to the control group.

Major strengths of the present study were the prospective randomized double-blind trial design with a follow-up until 24 h and extensive literature search. However, the study has few limitations. First, a relatively small sample size of ASA grade 1 and 2 patients only who were operated under SAB. A larger sample size including high-risk patients under general anesthesia and using different doses of adjuvants to local anesthetics may be needed to investigate the extent and efficacy of TAPB. Second, the time at which the TAPB began to work and the time at which the sensory effect of intrathecal block began to wear off could not be differentiated, which may be important in assessing a successful TAPB.

CONCLUSION

TAPB is effective and safe method for providing postoperative analgesia following inguinal herniorrhaphy. Dexamethasone and dexmedetomidine both prolonged the duration of postoperative analgesia when used as adjuvant to levobupivacaine and found to have no statistically significant difference.

AUTHORS' CONTRIBUTION

All the authors contributed to the preparation of the final manuscript

CONFLICT OF INTEREST

There is no conflict of interest.

FINANCIAL SUPPORT AND SPONSORSHIP

Nil.

REFERENCES

- Singla N, Garg K, Jain R, Malhotra A, Singh MR, Grewal A. Analgesic efficacy of dexamethasone versus dexmedetomidine as an adjuvant to ropivacaine in ultrasound-guided transversus abdominis plane block for post-operative pain relief in caesarean section: A prospective randomised controlled study. *Indian J Anaesth* 2021;65:S121-6.
- Hebbard P, Fujiwara Y, Shibata Y, Royse C. Ultrasound-guided transversus abdominis plane (TAP) block. *Anaesth Intensive Care* 2007;35:616-8.
- Abdel-Wahab AH, Osman EA, Ahmed AY. Comparison of postoperative analgesic effects of two doses of dexamethasone in ultrasound-guided transversus abdominis plane block for inguinal hernia repair: A randomized controlled trial. *Ain Shams J Anesthesiol* 2021;13:20.
- Bajwa SJ, Kaur J. Clinical profile of levobupivacaine in regional anaesthesia: A systematic review. *J Anaesthesiol Clin Pharmacol* 2013;29:530-9.
- Abdelaal W, Metry AA, Refaat M, Ragaie M, Nakhla G. Comparative study between levobupivacaine versus levobupivacaine plus dexmedetomidine for transversus abdominis plane block "TAP" in postoperative pain management after abdominoplasty. *Enliven J Anesthesiol Crit Care Med* 2015;2:4.
- Rosero EB, Joshi GP. Preemptive, preventive, multimodal analgesia: What do they really mean? *Plast Reconstr Surg* 2014;134:85S-93.
- Bollag L, Richebe P, Sialy M, Ortner CM, Gofeld M, Landau R. Effect of transversus abdominis plane block with and without clonidine on post-caesarean delivery wound hyperalgesia and pain. *Reg Anesth Pain Med* 2012;37:508-14.
- Kaur M, Singh PM. Current role of dexmedetomidine in clinical anesthesia and intensive care. *Anesth Essays Res* 2011;5:128-33.
- Naaz S, Ozair E. Dexmedetomidine in current anaesthesia practice a review. *J Clin Diagn Res* 2014;8:GE01-4.
- McCormack K. The spinal actions of nonsteroidal anti-inflammatory drugs and the dissociation between their anti-inflammatory and analgesic effects. *Drugs* 1994;47:28-45.
- Ahlgren SC, Wang JF, Levine JD. C-fiber mechanical stimulus-response functions are different in inflammatory versus neuropathic hyperalgesia in the rat. *Neuroscience* 1996;76:285-90.
- Attardi B, Takimoto K, Severns C, Levitan ES. Glucocorticoid induced upregulation of a pituitary K⁺ channel mRNA *in vitro* and *in vivo*. *Recept Channels* 1993;1:287-93.
- Varshney A, Prabhu M, Periyadka B, Nanjundegowda DC, Rao A. Transversus abdominis plane (TAP) block with levobupivacaine versus levobupivacaine with dexmedetomidine for postoperative analgesia following cesarean delivery. *J Anaesthesiol Clin Pharmacol* 2019;35:161-4.
- Parameswari AR, Udayakumar P. Comparison of efficacy of bupivacaine with dexmedetomidine versus bupivacaine alone for transversus abdominis plane block for postoperative analgesia in patients undergoing elective caesarean section. *J Obstet Gynecol India* 2018;68:98-103.
- Gupta A, Gupta A, Yadav N. Effect of dexamethasone as an adjuvant to ropivacaine on duration and quality of analgesia in ultrasound-guided transversus abdominis plane block in patients undergoing lower segment cesarean section - A prospective, randomised, single-blinded study. *Indian J Anaesth* 2019;63:469-74.
- Deshpande JP, Ghodki PS, Sardesai SP. The analgesic efficacy of dexamethasone added to ropivacaine in transversus abdominis plane block for transabdominal hysterectomy under subarachnoid block. *Anesth Essays Res* 2017;11:499-502.
- Qian H, Zhang Q, Zhu P, Zhang X. Ultrasound-guided transversus abdominis plane block using ropivacaine and dexmedetomidine in patients undergoing caesarian sections to relieve post-operative analgesia: A randomized controlled clinical trial. *Exp Ther Med* 2020;20:1163-8.

18. Sharma UD, Prateek, Tak H. Effect of addition of dexamethasone to ropivacaine on post-operative analgesia in ultrasonography-guided transversus abdominis plane block for inguinal hernia repair: A prospective, double-blind, randomised controlled trial. *Indian J Anaesth* 2018;62:371-5.
19. Seervi SN, Singariya G, Kamal M, Kumari K, Siddeshwara A, Ujwal S. Effect of buorenorphine or dexamethasone to levobupivacaine on postoperative analgesia in ultrasound guided tranversus abdominis plane block in patients undergoing unilateral inguinal hernia repair: A prospective randomized double blind controlled trial. *Korean J Anesthesiol* 2019;72:245-52.
20. Sachdeva J, Sinha A. A randomized controlled trial to study the effect of dexamethasone as additive to ropivacaine on duration of ultrasound guided tranversus abdominis plane block in caesarean section. *Indian J Pain* 2016;30:181-5.
21. Bansal P, Sood D. Effect of dexmedetomidine as an adjuvant to ropivacaine in ultrasound-guided transversus abdominis plane block for post-operative pain relief in cesarean section. *J Obstet Anaesth Crit Care* 2018;8:79-82.
22. McMorrow RC, Ni Mhuircheartaigh RJ, Ahmed KA, Aslani A, Ng SC, Conrick-Martin I, et al. Comparison of transversus abdominis plane block vs. spinal morphine for pain relief after Caesarean section. *Br J Anaesth* 2011;106:706-12.
23. Khare A, Thada B, Yadav D, Mathur V, Singh M. A randomized double blind study to infraumbilical surgeries. *Anesth Pain Intensive compare* 1% 2-chloroprocaine and 0.5% bupivacaine in spinal anesthesia for *Care* 2019;23:162-7.
24. Loane H, Preston R, Douglas MJ, Massey S, Papsdorf M, Tyler J. A randomized controlled trial comparing intrathecal morphine with transversus abdominis plane block for post-caesarean delivery analgesia. *Int J Obstet Anesth* 2012;21:112-8.
25. De Oliveira GS Jr., Fitzgerald PC, Marcus RJ, Ahmad S, McCarthy RJ. A doseranging study of the effect of transversus abdominis block on postoperative quality of recovery and analgesia after outpatient laparoscopy. *Anesth Analg* 2011;113:1218-25.
26. Chu CC, Hsing CH, Shieh JP, Chien CC, Ho CM, Wang JJ. The cellular mechanisms of the antiemetic action of dexamethasone and related glucocorticoids against vomiting. *Eur J Pharmacol* 2014;722:48-54.