

INJECTION OF AUTOLOGOUS WHOLE BLOOD VERSUS CORTICOSTEROID FOR LATERAL EPICONDYLITIS: A COMPARATIVE STUDY

AWEZ KHAN*^{ORCID}, BHIMANI FAHAD WAHID^{ORCID}, MUKESH TIWARI^{ORCID}, RAJESH KUMAR KANOJI^{ORCID},
PRADEEP KUMAR SUTHAR^{ORCID}

Department of Orthopedics, National Institute of Medical Sciences Jaipur, Rajasthan, India.

*Corresponding author: Awez Khan; E-mail: awezkhan87@gmail.com

Received: 28 September 2023, Revised and Accepted: 10 November 2023

ABSTRACT

Objective: The objective is to compare the efficacy, in terms of pain relief and functional improvement, of autologous whole blood and corticosteroid injection in managing lateral epicondylitis (Tennis elbow).

Methods: This was a comparative study conducted in Department of Orthopedics, National Institute of Medical Sciences Jaipur, Rajasthan, India. Eighty patients diagnosed to be having lateral epicondylitis were included in this study on the basis of predefined inclusion and exclusion criteria. The patients were divided into 2 groups on the basis of whether they were given autologous whole blood (Group B) or corticosteroid injection (Group S). Efficacy of both the treatment modality was compared in terms of Pain relief (as assessed by reduction in visual analogue score [VAS] score) and functional improvement (as assessed by improvement in Mayo Elbow performance score). SSPS 22.0 software was used for statistical analysis and $p < 0.05$ was taken as statistically significant.

Results: A total of 80 patients were included in this study out of which there were 37 (46.25%) males and 43 (53.75%) females with a M: F ratio of 1:1.16. The mean age of patients in group B and group S was found to be found to be 52.36 ± 9.98 years and 48.46 ± 10.12 years, respectively. The mean age of patients in both the groups was found to be comparable with no statistically significant difference ($p = 0.0866$). At the time of 4 weeks, 8 weeks, and 12 weeks follow-up, the mean VAS score in Group B was less as compared to group S and the difference was found to be statistically highly significant ($p < 0.0001$). At the time of 4 weeks, 8 weeks, and 12 weeks' follow-up, the mean MEPS in Group B was more as compared to group S, and the difference was found to be statistically significant ($p < 0.05$).

Conclusion: For lateral epicondylitis, whole blood injection demonstrated superior efficacy in terms of pain relief and functional improvement as compared to injection of corticosteroid.

Keywords: Tennis elbow, Lateral epicondylitis, Autologous whole blood, Corticosteroids.

© 2023 The Authors. Published by Innovare Academic Sciences Pvt Ltd. This is an open access article under the CC BY license (<http://creativecommons.org/licenses/by/4.0/>) DOI: <http://dx.doi.org/10.22159/ajpcr.2023v16i12.49952>. Journal homepage: <https://innovareacademics.in/journals/index.php/ajpcr>

INTRODUCTION

Lateral epicondylitis, commonly known as tennis elbow, is a common musculoskeletal condition affecting the extensor tendons of the forearm, specifically the common extensor tendon originating at the lateral epicondyle of the humerus [1]. Lateral epicondylitis is characterized by degenerative changes rather than inflammatory processes, despite its historical terminology. Individuals engaged in professions or sports that involve frequent and forceful use of the forearm, such as carpentry, painting, or playing racquet sports, are at an increased risk. Poor technique during sports or work-related activities can also contribute to the strain on the tendons [2]. Age plays a role, as the risk tends to increase with advancing age, possibly due to the natural aging process and decreased tendon flexibility. In addition, inadequate muscle strength and improper equipment, such as using a tennis racket with an inappropriate grip size, may contribute to the development of lateral epicondylitis. The primary etiology is often attributed to repetitive overuse, leading to microtrauma and subsequent degeneration of the extensor tendon [3]. Clinically, patients with lateral epicondylitis typically present with lateral elbow pain exacerbated by gripping and wrist extension, often hindering daily activities and affecting work performance. Diagnosis is primarily clinical, with the presence of localized tenderness at the lateral epicondyle and pain upon resisted

wrist extension. Imaging studies are rarely necessary but may be employed to rule out other potential causes of symptoms [4].

In the management of lateral epicondylitis, various conservative approaches are employed, including rest, physical therapy, nonsteroidal anti-inflammatory drugs, and bracing [5]. When conservative measures fail to provide relief, more invasive interventions, such as injections, become a crucial aspect of treatment. Two commonly employed injection therapies for lateral epicondylitis are autologous whole blood and corticosteroids. These interventions aim to reduce pain and promote healing, but their mechanisms of action differ significantly [6].

Autologous whole-blood injections involve drawing the patient's blood and re-injecting it into the affected area, typically at the origin of the extensor tendon. This approach harnesses the regenerative potential of platelets and growth factors within the patient's blood to stimulate tissue repair. In contrast, corticosteroid injections target inflammation by delivering potent anti-inflammatory agents directly to the site of injury. While corticosteroids can provide rapid relief of symptoms, concerns about their potential adverse effects, including tendon atrophy and impaired healing, have fuelled interest in alternative therapies such as autologous whole blood [7].

Despite the prevalence of lateral epicondylitis and the various treatment options available, there exists a notable gap in our understanding of the comparative effectiveness of autologous whole blood versus corticosteroid injections. While both interventions have

been individually studied, there is a scarcity of high quality, direct comparative studies that evaluate their relative efficacy, safety, and long-term outcomes. This knowledge gap leaves clinicians grappling with the decision of which injection therapy to prioritize, lacking evidence-based guidance to inform their treatment decisions [8].

This research paper aims to address this critical gap in the existing literature by conducting a comprehensive comparative study on the injection of autologous whole blood versus corticosteroid for lateral epicondylitis. By systematically evaluating and comparing the outcomes of these two interventions, our study intends to provide evidence-based insights into the optimal choice of injection therapy for patients with lateral epicondylitis.

METHODS

This was a comparative study conducted in the Department of Orthopedics, National Institute of Medical Sciences Jaipur, Rajasthan, India. The duration of the study was 1 year. 80 patients diagnosed to be having lateral epicondylitis (tennis elbow) were included in this study on the basis of a predefined inclusion and exclusion criteria. Written and informed consent was obtained from all the patients before enrolling them in the study. The sample size was calculated by formula $n = Z^2 P (1-P)/d^2$ using OPENEPI software version 3 on the basis of pilot studies done on the topic of body lateral epicondylitis assuming 90% power and 95% confidence interval, the sample size required was 38 patients. Based on central limit theorem, the sample size was determined to be enough if it was more than 38 thus 40 patients were included in each group. Total 80 patients were divided into 2 groups of 40 patients each. Patients were randomized by simple randomization (alternate patient in each group). Demographic details such as age, gender, and occupation of all the patients were noted. Height and weight were noted and body mass index of each patient was calculated. A detailed history was obtained in terms of presence of any chronic system illness such as hypertension, diabetes mellitus, arthritis or any autoimmune disorder.

A thorough general clinical examination as well as a local examination was done. The presence of tenderness over the lateral epicondyle was noted. Basic investigations such as complete blood count, C-reactive protein, erythrocyte sedimentation rate and rheumatoid factor were done. Anteroposterior and oblique X-ray of affected elbow was done in all cases. Local ultrasound was also done in all the cases. Magnetic resonance imaging was done in selected cases. The diagnosis of lateral epicondylitis was made on the basis of clinical features and imaging abnormalities such as Thickening of the common extensor tendon along with diffuse heterogeneity and areas of focal hypoechogenicity on ultrasound. Patients were divided into following 2 groups by simple randomization-

- Group B: 2 mL of autologous venous blood mixed with 1 mL of 2% prilocaine hydrochloride injected proximal to the lateral epicondyle under the surface of the extensor carpi radialis brevis by peppering technique under strict aseptic precautions.
- Group S: 1 mL of 40 mg methylprednisolone acetate mixed with 1 mL of 2% prilocaine hydrochloride injected proximal to the lateral epicondyle under the surface of the extensor carpi radialis brevis by peppering technique under strict aseptic precautions.

After the injection small sterile dressing was applied over the injection site. Upper limb rest 48 h was advised and the patient was asked to avoid strenuous activities or weight lifting of the affected upper limb for at least 10 days. Passive stretching of the extensor muscles was advised after 3 days of injection unless there was significant pain in which case passive stretching was postponed till pain is subsided. Patients were assessed for pain by visual analogue score (VAS) [9] and for functional status by Mayo Elbow Performance Score (MEPS) score [10] at the time of presentation and at the time of each follow up visits. The patients were followed up at 2 weeks, 4 weeks, 8 weeks and 12 weeks. A VAS up to 3 was taken as pain relief and VAS score of more than 3 was considered suboptimal pain relief. Functional outcome was assessed by

Mayo Elbow score. SPSS 21.0 software was used for statistical analysis and $p < 0.05$ was taken as statistically significant.

Inclusion criteria

1. Patients diagnosed to be having lateral epicondylitis (Tennis elbow) on the basis of clinical features and imaging
2. Gave informed written consent to be part of the study
3. Age more than 18 years
4. Failed to respond to conservative management for 3 months.

Exclusion criteria

1. Age less than 18 years
2. Those who refused written consent to be a part of the study
3. Any previous local intervention such as any local injection
4. Any previous surgery on the affected hand likely to hinder proper functional assessment
5. Conditions likely to affect functional assessment such as autoimmune arthritis or polyarthritis, rheumatoid arthritis, etc.

RESULTS

A total of 80 patients were included in this study out of which there were 37 (46.25%) males and 43 (53.75%) females with a M: F ratio of 1:1.16. Although in both the groups there was a slight female preponderance the gender distribution was found to be comparable in both the groups with no statistically significant difference among the 2 groups ($p=0.4939$) (Table 1).

In Group B, the most commonly affected age group was 41–50 years (37.50%) followed by 51–60 years (30%). Only 3 (7.50%) patients were below 30 years of age. In Group S, the most common affected age group was 51–60 years (32.50%) followed by 41–50 years (27.50%) and 31–40 years (20.00%). Only 2 (5%) patients were below 30 years of age. The mean age of patients in Group B and Group S was found to be found to be 52.36 ± 9.98 years and 48.46 ± 10.12 years, respectively. The mean age of patients in both the groups was found to be comparable with no statistically significant difference ($p=0.0866$) (Table 2).

The analysis of patients on the basis of body mass index (BMI) showed that most of the patients with lateral epicondylitis (tennis elbow) were either overweight (45.00%) or obese (32.50%). It was less common in individuals having healthy BMI (16.25%) or underweight individuals (6.25%) (Fig. 1).

Table 1: Gender distribution of the studied cases.

Gender distribution	Male		Female		p-value
	No. of cases	Percentage	No. of cases	Percentage	
Group B	19	17.50	21	32.50	0.4939
Group S	18	22.50	22	27.50	Not significant
Total	37	40.00	43	60.00	

Table 2: Comparison of age distribution in both the groups

Age groups	Group B		Group S	
	No. of cases	Percentage	No. of cases	Percentage
30 years or less	3	7.50	2	5.00
31–40 years	5	12.50	8	20.00
41–50 years	15	37.50	11	27.50
51–60 years	12	30.00	13	32.50
>60 years	5	12.50	6	15.00
Total	40	100.00	40	100.00
Mean age	52.36 ± 9.98		48.46 ± 10.12	

$p=0.0866$ (Not significant)

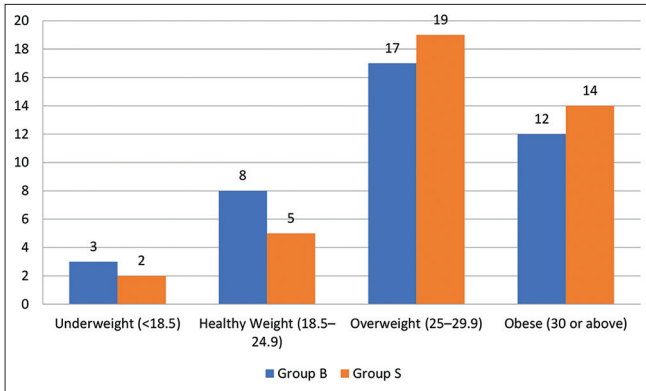


Fig. 1: Comparison of body mass index in both the groups

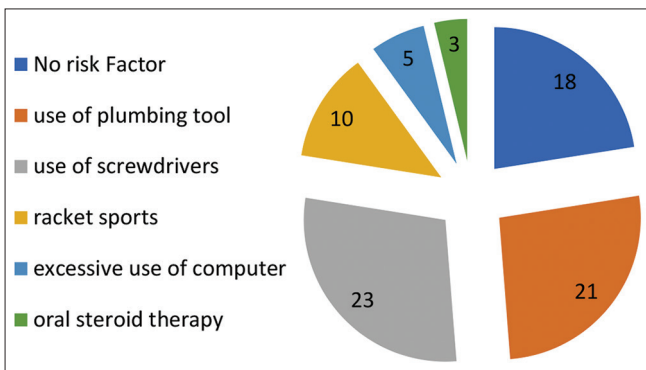


Fig. 2: Risk factors for development of lateral epicondylitis in studied cases

The analysis of the patients on the basis of risk factors showed that out of 80 studied cases the most common risk factor was use of excessive daily use of screwdrivers (28.75%) followed by repeated use of plumbing tool as a profession (26.25%), playing racket sports (12.50%), excessive use of computer (6.25%) and oral steroid therapy (3.75%). In 18 (22.50%) patients, no risk factor could be identified (Fig. 2).

The analysis of the patients on the basis of duration of pain showed that most of the patients had pain since 9–12 months (50%) duration followed by 6 months to 9 months (28.75%) and 3–6 months (8.75%). 10 (12.50%) patients had pain of more than 1 year duration. The mean duration of pain in group B and group S was found to be 10.12±2.86 and 9.46±3.12 months, respectively. The mean duration of pain was found to be comparable in both the groups with no statistically significant difference (p=0.6987) (Table 3).

At the time of presentation, all patients were having severe pain. The mean VAS score in Group B and Group S at the time of presentation was found to be 8.1±2.2 and 7.9±2.32, respectively. After the injection of whole blood (Group B) or steroid (Group S) VAS score was noted during each follow-up visit at 2 weeks, 4 weeks, 8 weeks, and 12 weeks (Fig. 3).

Till 2 weeks the reduction in VAS score was found to be comparable in both the groups. However, at the time of 4 weeks, 8 weeks, and 12 weeks' follow-up, the mean VAS score in Group B was less as compared to Group S and the difference was found to be statistically highly significant (p<0.0001) (Table 4).

Functional outcome in both the groups was assessed and compared by MEPS at presentation and at 2 weeks, 4 weeks, 8 weeks, and 3 months after the injection of whole blood or steroid. The mean MEPS in group B and group S at the time of presentation was found to be 40.24±12.80 and 44.86±13.98, respectively. After the injection of whole blood (Group B) or steroid (Group S) VAS score was noted during each follow up visit at

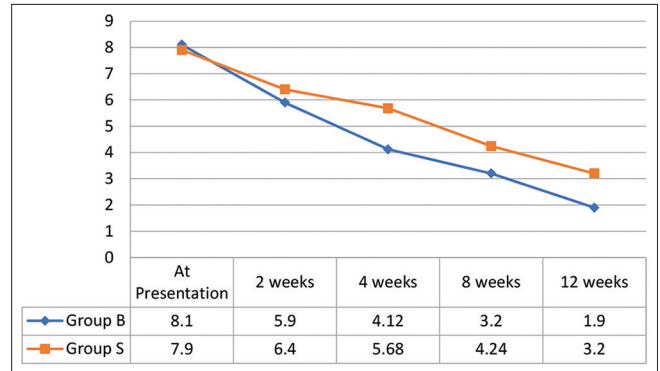


Fig. 3: Comparison of mean visual analogue scores in both the groups

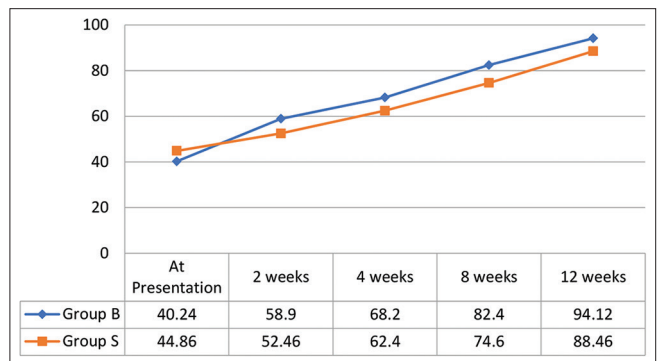


Fig. 4: Comparison of mean Mayo Elbow performance scores in both the groups

Table 3: Comparison of mean duration of pain in studied cases

Duration of pain	Group B		Group S	
	No. of cases	Percentage	No. of cases	Percentage
3–6 months	4	10.00	3	7.50
6–9 months	11	27.50	12	30.00
9 months–1 year	19	47.50	21	52.50
Above 1 year	6	15.00	4	10.00
Total	40	100.00	40	100.00
Mean duration (months)	10.12±2.86		9.46±3.12	

p=0.6987 (Not significant) 95% CI=-1.5923-1.0723

Table 4: Comparison of mean VAS Scores in both groups

Mean VAS score	Group B (whole Blood)	Group S (Steroid)	p-value	95% CI
At presentation	8.1±2.2	7.9±2.32	0.6875	-1861-0.7861
2 weeks	5.90±1.92	6.42±1.98	0.2367	-0.3482-1.3882
4 weeks	4.12±1.42	5.68±1.30	<0.0001*	0.9540-2.1660
8 weeks	3.20±0.84	4.24±0.92	<0.0001*	0.6478-1.4322
12 weeks	1.90±0.74	3.20±0.94	<0.0001*	0.9234-1.6766

*Significant. CI: Confidence interval, VAS: Visual Analog Score

2 weeks, 4 weeks, 8 weeks and 12 weeks. At the time of final follow-up, the mean MEPS in group B and Group S was found to be 94.12±8.80 and 88.46±11.10, respectively (Fig. 4).

Till 2 weeks the improvement in functional outcome was found to be comparable in both the groups. However, at the time of 4 weeks,

Table 5: Comparison of mean Mayo Elbow performance scores in both groups

Mean Mayo Elbow Score	Group B (whole Blood)	Group S (Steroid)	p-value	95% CI
At presentation	43.24±8.12	44.86±9.12	0.4040	-2.2238-5.4638
2 weeks	58.90±13.82	53.46±12.98	0.0748	-12.4082-0.4718
4 weeks	68.20±14.36	61.44±12.40	0.0270*	-12.7323-0.7877
8 weeks	82.40±10.24	74.62±11.80	0.0023*	-12.6980-2.8620
12 weeks	94.12±8.80	88.46±11.10	0.0135*	-10.1189-1.2011

*Significant. CI: Confidence interval

8 weeks, and 12 weeks' follow-up mean MEPS in Group B was more as compared to group S and the difference was found to be statistically significant ($p < 0.05$) (Table 5).

The analysis of the patients on the basis of adverse effects showed that there was no significant complication in any of the patients in any group. Three patients in group N and 2 patients in group S developed mild post-injection pain which was conservatively managed by cold compression and analgesics. There was no significant difference in rates of adverse effects among the studied groups. Complications such as infection, neurovascular damage, skin atrophy, or tendon rupture were not seen in any of the cases in any group.

DISCUSSION

In our study of 80 patients with lateral epicondylitis treated with either local injection of autologous whole blood or steroid injection, there were 37 (46.25%) males and 43 (53.75%) females with an M:F ratio of 1:1.16. There was only a slight female preponderance. Many studies have suggested that lateral epicondylitis may be more prevalent in females. The reasons behind this gender disparity are multifaceted. First, anatomical differences, such as differences in upper limb biomechanics and muscle mass distribution between males and females, may contribute to an increased susceptibility in women. In addition, hormonal factors, specifically hormonal fluctuations that occur during the menstrual cycle, might influence tendon integrity and recovery [11]. Furthermore, occupational factors and the increasing participation of females in activities that involve repetitive gripping and wrist extension may contribute to the higher incidence of lateral epicondylitis in women. As orthopedician, understanding and addressing these gender-specific considerations are essential for providing comprehensive and effective care for individuals, particularly females, affected by lateral epicondylitis [12].

In this study, the most common risk factor was the use of excessive daily use of screwdrivers (28.75%) followed by repeated use of plumbing tool as a profession (26.25%), playing racket sports (12.50%), excessive use of computer (6.25%) and oral steroid therapy (3.75%). In 18 (22.50%) patients, no risk factor could be identified. The repeated movements of the forearm causing overuse of the forearm extensor muscles, leading to microtears and inflammation at the origin of the extensor tendon on the lateral epicondyle of the humerus is thought to be responsible for tennis elbow [13]. Several risk factors contribute to the development of this condition. Repetitive and forceful gripping activities, such as those seen in racquet sports, manual labor, and certain occupational tasks, are major culprits. Poor technique during sports or work-related activities can exacerbate the strain on the extensor tendons. In addition, inadequate muscle strength and flexibility, as well as improper equipment, may contribute to the increased risk of developing lateral epicondylitis. Age is also a factor, with the condition more commonly affecting individuals between the ages of 30 and 50 years. Furthermore, systemic factors such as obesity and certain inflammatory conditions may predispose individuals to this condition [14].

In our study, till 2 weeks after injection, the reduction in VAS score was found to be comparable in both the groups. However, at the time of 4 weeks, 8 weeks, and 12 weeks' follow-up, the mean VAS score in Group B was less as compared to group S and the difference

was found to be statistically highly significant ($p < 0.0001$). Arik *et al.* conducted a study to compare efficacy of autologous blood injection and corticosteroid injection for tennis elbow. The participants, comprising 21 men and 59 women with a mean age of 45.2 years, were administered either autologous blood injection or corticosteroid injection by a single physician. Assessment at various intervals up to 90 days post-treatment revealed no complications, and both interventions led to significant improvements in elbow pain, function, and grip strength. However, the pattern of improvement differed between the two groups. Corticosteroid injection demonstrated a faster initial improvement over the first 15 days, followed by a decline, while autologous blood injection exhibited a steady and eventually superior improvement in all three parameters. Notably, a higher percentage of patients who received autologous blood injection achieved complete recovery, suggesting its greater effectiveness over the follow-up period. The study concluded that autologous blood injection is recommended as a first-line treatment for lateral epicondylitis due to its simplicity, cost-effectiveness, and superior efficacy [15]. Similar findings were also reported by the authors such as Kaya *et al.* [16] and Arirachakaran *et al.* [17].

Till 2 weeks the improvement in functional outcome was found to be comparable in both the groups. However, at the time of 4 weeks, 8 weeks and 12 weeks follow up mean MEPS in Group B was more as compared to group S and the difference was found to be statistically significant ($p < 0.05$). Jindal *et al.* conducted a single-blinded, prospective parallel group trial in which the efficacy of autologous blood injection versus local corticosteroid injection in the treatment of tennis elbow was assessed [18]. Fifty consecutive patients with untreated lateral epicondylitis were enrolled, with randomization into two groups: one receiving a steroid injection and the other receiving an injection of autologous blood. Baseline evaluation revealed no significant differences between the two groups. At the 2-week mark, between-group analysis showed no discernible distinction in pain relief and Nirschl stage. However, by the 6-week evaluation, the group receiving autologous blood injection demonstrated a significant decrease in pain levels and stage of disease compared to the steroid group. These findings suggest that autologous blood injection was more effective than steroid injection in the short-term follow-up for tennis elbow. Similar better functional outcome in patients receiving whole blood injection as compared to steroid injection was also reported by the authors such as Kazemi *et al.* [19] and Wolf *et al.* [20].

CONCLUSION

While autologous whole blood as well as steroid injections demonstrated significant improvement in pain (VAS scores) and functional outcomes (MEPS), the use of whole blood injection showed superior results compared to steroid injection at 4, 8, and 12 weeks of follow-up. Importantly, both interventions exhibited a favorable safety profile, with minimal and manageable adverse effects. This study suggests that whole blood injection presents as a promising therapeutic option for lateral epicondylitis.

CONFLICT OF INTEREST

None.

REFERENCES

- Buchanan BK, Varacallo M. Lateral epicondylitis (Tennis Elbow). In: StatPearls. Treasure Island, FL: StatPearls Publishing; 2023.
- Vaquero-Picado A, Barco R, Antuña SA. Lateral epicondylitis of the elbow. EFORT Open Rev 2017;1:391-7. doi: 10.1302/2058-5241.1.000049
- De Smedt T, de Jong A, Van Leemput W, Lieven D, Van Glabbeek F. Lateral epicondylitis in tennis: Update on aetiology, biomechanics and treatment. Br J Sports Med 2007;41:816-9. doi: 10.1136/bjsm.2007.036723
- Kotnis NA, Chiavaras MM, Harish S. Lateral epicondylitis and beyond: Imaging of lateral elbow pain with clinical-radiologic correlation. Skeletal Radiol 2012;41:369-86. doi: 10.1007/s00256-011-1343-8
- Calfee RP, Patel A, DaSilva MF, Akelman E. Management of lateral epicondylitis: Current concepts. J Am Acad Orthop Surg 2008;16:19-29. doi: 10.5435/00124635-200801000-00004
- Houck DA, Kraeutler MJ, Thornton LB, McCarty EC, Bravman JT, Jorak R, Esmaeilnejadganji SM, Bijani A, Kamali Ahangar S, Javer R, Mohammadi G. Local autologous blood and corticosteroid injection on pain and function in patients with tennis elbow. Caspian J Intern Med. 2023;14(4):633-639. doi:10.22088/cjim.14.4.633.
- Bisset L, Coombes B, Vicenzino B. Tennis elbow. BMJ Clin Evid 2011;2011:1117.
- Di Filippo L, Vincenzi S, Pennella D, Maselli F. Treatment, diagnostic criteria and variability of terminology for lateral elbow pain: Findings from an overview of systematic reviews. Healthcare (Basel) 2022;10:1095. doi: 10.3390/healthcare10061095
- Delgado DA, Lambert BS, Boutris N, McCulloch PC, Robbins AB, Moreno MR, et al. Validation of digital visual analog scale pain scoring with a traditional paper-based visual analog scale in adults. J Am Acad Orthop Surg Glob Res Rev 2018;2:e088. doi: 10.5435/JAAOSGlobal-D-17-00088
- Cusick MC, Bonnaig NS, Azar FM, Mauck BM, Smith RA, Throckmorton TW. Accuracy and reliability of the Mayo Elbow Performance Score. J Hand Surg Am 2014;39:1146-50. doi: 10.1016/j.jhsa.2014.01.041
- Cutts S, Gangoo S, Modi N, Pasapula C. Tennis elbow: A clinical review article. J Orthop 2019;17:203-7. doi: 10.1016/j.jor.2019.08.005
- Kaminsky SB, Baker CL Jr. Lateral epicondylitis of the elbow. Tech Hand Up Extrem Surg 2003;7:179-89. doi: 10.1097/00130911-200312000-00009
- Ahmad Z, Siddiqui N, Malik SS, Abdus-Samee M, Tytherleigh-Strong G, Rushton N. Lateral epicondylitis: A review of pathology and management. Bone Joint J 2013;95-B:1158-64. doi: 10.1302/0301-620X.95B9.29285
- Luk JK, Tsang RC, Leung HB. Lateral epicondylalgia: Midlife crisis of a tendon. Hong Kong Med J 2014;20:145-51. doi: 10.12809/hkmj134110
- Arik HO, Kose O, Guler F, Deniz G, Egerci OF, Ucar M. Injection of autologous blood versus corticosteroid for lateral epicondylitis: A randomised controlled study. J Orthop Surg (Hong Kong) 2014;22:333-7. doi: 10.1177/230949901402200313
- Kaya SS, Yardımcı G, Göksu H, Genç H. Effects of splinting and three injection therapies (corticosteroid, autologous blood and prolotherapy) on pain, grip strength, and functionality in patients with lateral epicondylitis. Turk J Phys Med Rehabil 2022;68:205-13. doi: 10.5606/tftrd.2022.8007
- Arirachakaran A, Sukthuyat A, Sisayanarane T, Laoratanavoraphong S, Kanchanatawan W, Kongtharvonskul J. Platelet-rich plasma versus autologous blood versus steroid injection in lateral epicondylitis: Systematic review and network meta-analysis. J Orthop Traumatol 2016;17:101-12. doi: 10.1007/s10195-015-0376-5
- Jindal N, Gaur Y, Banshiwal RC, Lamoria R, Bachhal V. Comparison of short term results of single injection of autologous blood and steroid injection in tennis elbow: A prospective study. J Orthop Surg Res 2013;8:10. doi: 10.1186/1749-799X-8-10
- Kazemi M, Azma K, Tavana B, Rezaiee Moghaddam F, Panahi A. Autologous blood versus corticosteroid local injection in the short-term treatment of lateral elbow tendinopathy: A randomized clinical trial of efficacy. Am J Phys Med Rehabil 2010;89:660-7. doi: 10.1097/PHM.0b013e3181ddcb31
- Wolf JM, Ozer K, Scott F, Gordon MJ, Williams AE. Comparison of autologous blood, corticosteroid, and saline injection in the treatment of lateral epicondylitis: A prospective, randomized, controlled multicenter study. J Hand Surg 2011;36A:1269-72.