

COMPLETE AND INCOMPLETE BONY BRIDGES NEAR FORAMEN OVALE WITH POTENTIAL SURGICAL AND CLINICAL IMPLICATIONS

RITUBHI MEHTA^{1*}, JAGMOHAN SHARMA², PANKAJ KUMAR SINGH², PRABHJOT KAUR CHHABRA²

¹Department of Anatomy, Mahatma Gandhi Medical College and Hospital, Mahatma Gandhi University of Medical Sciences and Technology, Jaipur, Rajasthan, India. ²Department of Anatomy, Mahatma Gandhi Medical College and Hospital, Jaipur, Rajasthan, India.

*Corresponding author: Ritubhi Mehta; Email: ritumehta2408@gmail.com

Received: 17 December 2023, Revised and Accepted: 27 February 2024

ABSTRACT

Objectives: Pterygospinous or Pterygoalar ligaments may pose mandibular nerve compression by when present near foramen ovale. The presence of ossified pterygospinous or pterygoalar ligaments might cause trouble to surgeons in performing percutaneous rhizotomy for trigeminal neuralgia, electroencephalographic procedures, or taking biopsy from cavernous sinus tumors. The present study aims to find the incidence and specific morphological variations related to the ossification of pterygospinous and pterygoalar ligaments.

Methods: The study was conducted on 200 dried adult human cadaveric skull of unknown age and sex in the department of Anatomy, Mahatma Gandhi Medical College and Hospital, Jaipur. Skulls were obtained from different medical colleges of the Rajasthan region. The study included fully dried, intact, adult human skull bones with no structural defects. Damaged, fractured, skull with the developmental anomaly, injured or pathologically malformed skull especially at or near the foramen ovale on either side were excluded from the study. Ossification of pterygospinous and pterygoalar bar was studied on both sides. Statistical analyses were performed using SPSS Version 26 software.

Results: Ossified ligaments were studied in 400 sides of 200 skulls. The ossification of pterygospinous bar was observed in 53 cases (13.25%). The pterygospinous bar was complete in twelve (3%) cases and incomplete in 41 cases (10.25%). The ossified pterygoalar ligament was observed in 62 cases (15.5%). Ossification was complete in 15 cases (3.75%) and incomplete in 47 cases (11.75%).

Conclusion: Ossification of pterygospinous and pterygoalar bars was observed in skulls obtained from medical colleges in the Rajasthan region. Knowledge of such morphological variations of the skull base will improve the therapeutic outcomes in the treatment of trigeminal neuralgia.

Keywords: Foramen ovale, Pterygospinous bar, Pterygoalar bar, Trigeminal neuralgia.

© 2024 The Authors. Published by Innovare Academic Sciences Pvt Ltd. This is an open access article under the CC BY license (<http://creativecommons.org/licenses/by/4.0/>) DOI: <http://dx.doi.org/10.22159/ajpcr.2024v17i5.50142>. Journal homepage: <https://innovareacademics.in/journals/index.php/ajpcr>

INTRODUCTION

Osseous bridging occurs in different areas of the body and is often age-dependent. This is a poorly understood consequence of secondary ossification of fibrous structures [1]. Nonetheless, the idea of genetic origins was raised by the observation of these bone bridges in children [2]. Many skull ligaments are significant from a clinical standpoint. The pterygospinous and pterygoalar ligaments are situated near the foramen ovale and have a significant clinical relationship with this structure. In contrast to the pterygoalar bar, which runs beneath the foramen ovale and divides it into two sections, the pterygospinous bar is either medial or below the foramen ovale [1].

Patients with compressive syndrome have shown that, in the absence of any clear etiology, the disorder is caused by ligament ossification. Ossification of the cranial base ligaments may hinder operating access and surgical routes in this area [3].

The pterygospinous ligament made up of the thicker fascia between the medial and lateral pterygoid muscles. It extends from the sphenoid spine to the top portion of the lateral pterygoid plate's posterior edge. Occasionally, muscular developments like the pterygospinous muscle, which is inserted into the temporomandibular joint capsule and extends to the articular disc, replace the pterygospinous ligament. The pterygospinous ligament may ossify completely or partially at times [4-6]. Mandibular nerve block may be hampered by the ossification of this ligament, which may entrap the neurovascular structures [7].

The purpose of this study is to examine the occurrence and architecture of pterygospinous and pterygoalar bars in human skulls and to understand their clinical significance.

METHODS

The present study was an observational study conducted to describe the ossification of pterygospinous and pterygoalar ligaments near foramen ovale.

The study was carried out on 400 foramen ovale using 200 adult human skulls. The specimens included in the study were of unknown sexes and ages. Skulls were obtained from different medical colleges of the Rajasthan region. The study included fully dried, intact, adult human skulls bones with no structural defects. Damaged, fractured, skull with developmental anomaly, injured or pathologically malformed skull especially at or near the Foramen ovale, and the lateral plate of the pterygoid process on either side were excluded from the study. Ossification of pterygospinous and pterygoalar bar was studied and variations on the right and left sides were noted.

Statistical analysis

The data were tabulated and statistically analyzed by using SPSS version 26 software. The categorical variables were described as numbers and percentages. The Chi-square test was applied to know the relatedness between categorical variables and $p < 0.05$ (two-tailed) was considered statistically significant.

RESULTS

In this study, a total of 200 dry skulls of adults from the Rajasthan population were examined for the presence or absence of pterygospinous and pterygoalar bar on both sides of foramen ovale.

There were 05 (2.5%) and 07 (3.5%) cases on the right and left side respectively where the pterygospinous bar was complete (Fig. 1), and in 27 (13.5%) and 14 (7%) cases where the pterygospinous bar was partially formed or incomplete (Fig. 2) and in 168 (84%) and 179 (89.5%) cases there was no pterygospinous bar present on the lateral pterygoid plate, respectively (Table 1).

There were 6 (3%) and 9 (4.5%) cases on the right and left side respectively where the pterygoalar bar was complete (Fig. 3), and incomplete in 21 (10.5%) and 26 (13%) cases where the pterygoalar bar was partially formed or incomplete (Fig. 4). In 173 (86.5%) and 165 (82.5%) cases, there was no pterygoalar bar present on the lateral pterygoid plate, respectively (Table 2).

On comparing ossification of pterygospinous and pterygoalar bars on both sides, it was observed that pterygospinous and pterygoalar bars were bilateral in 7 (3.5%) and 6 (3%) skulls (Fig. 5), 39 (19.5%) and 50 (25%) unilateral, and absent in 154 (77%) and 144 (72%) respectively (Table 3).

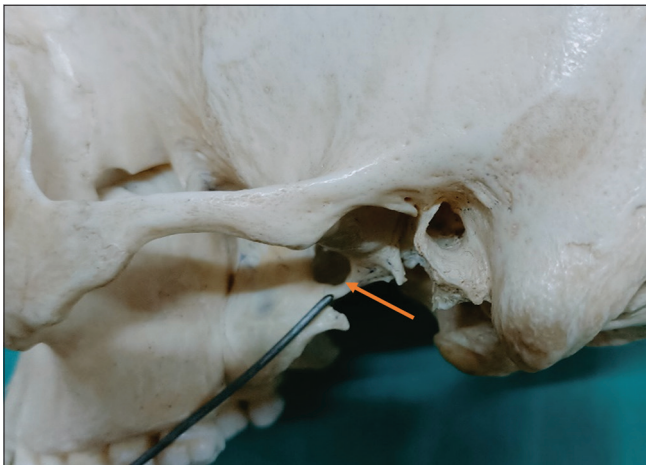


Fig. 1: Complete pterygospinous bar present on the left side (Arrow)

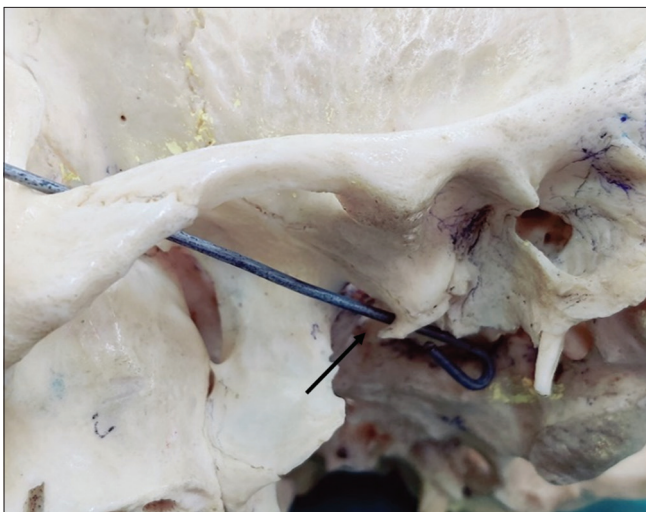


Fig. 2: Incomplete pterygospinous bar present on the left side (Arrow)

DISCUSSION

The present study is one of the few that provides information on the prevalence of pterygospinous and pterygoalar bars in the medical colleges in Rajasthan. The prevalence of pterygospinous and pterygoalar bars (full and incomplete) in our study was 15.5% and 13.25%, respectively. According to other studies, the prevalence of pterygospinous bars ranged from 1% to 31.2%, while pterygoalar bars ranged from 1.3% to 62.4%. [3,8,9]. The incidence of pterygospinous and pterygoalar bar was higher among Brazilian [8] population, followed by Greeks, [1] Indians [5], and Croatians [10]. Findings from our study correlate with these studies.

Complete ossification of pterygospinous bar in our study was 3% and it has also been noted in several studies and the incidence ranged from 2 to 6% [10-13]. Complete ossification of pterygoalar bar was noted

Table 1: Distribution of complete and incomplete absent pterygospinous bar from lateral pterygoid plate

Side	Pterygospinous bar			Total
	Complete	Incomplete	Absent	
Right (N-200)	05 (2.5%)	27 (13.5%)	168 (84%)	200
Left (N-200)	07 (3.5%)	14 (7%)	179 (89.5%)	200
Total	12 (3%)	41 (10.25%)	347 (86.75%)	400

$\chi^2=4.804, P=0.090$

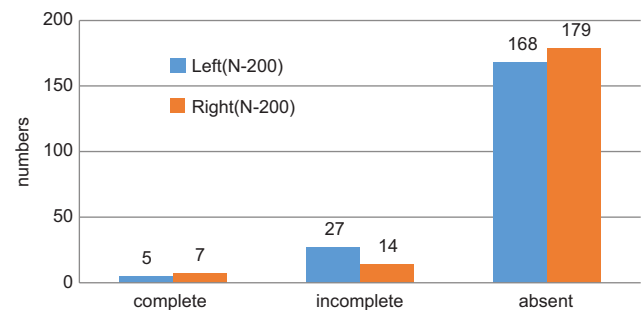
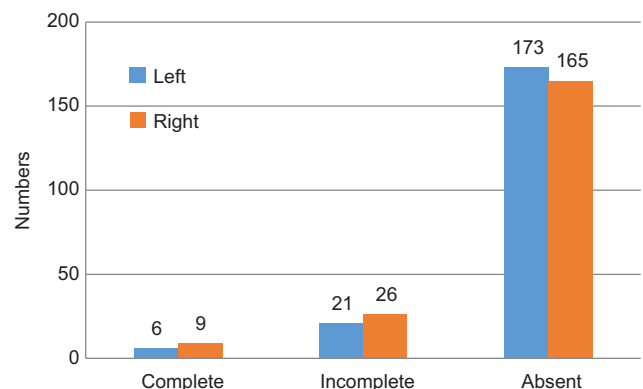


Table 2: Distribution of complete, incomplete, and absent pterygoalar bar from lateral pterygoid plate

Side	Pterygoalar bar (%)			Total
	Complete	Incomplete	Absent	
Right	06 (3)	21 (10.5)	173 (86.5)	200
Left	09 (4.5)	26 (13)	165 (82.5)	200
Total	15 (3.75)	47 (11.75)	338 (84.5)	400

$\chi^2=1.321, p=0.516$



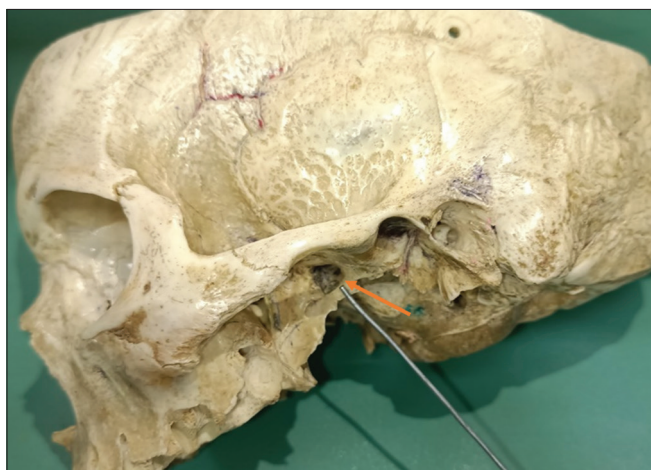


Fig. 3: Complete pterygoalar bar present on the left side

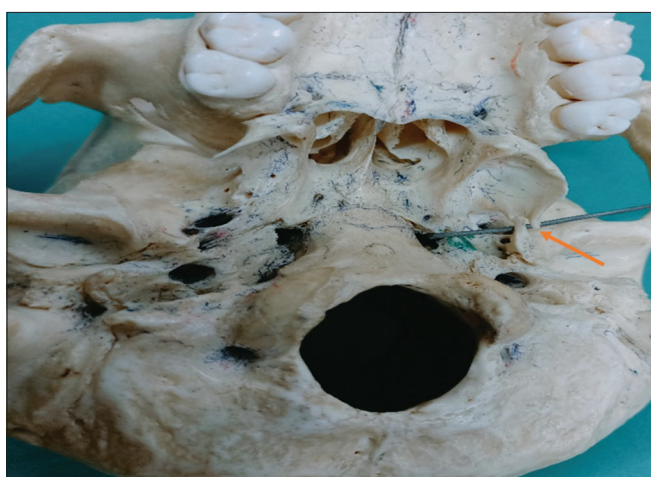

Fig. 4: Incomplete pterygoalar bar present at the margin of the foramen ovale

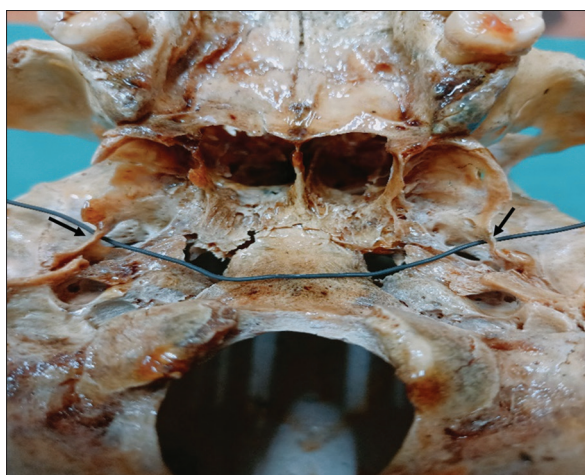


Fig. 5: Bilateral complete pterygoalar bar present (Arrow)

in 3.75% of skulls in the present study. Similar finding was noted by Natsis *et al.* in Greeks skulls [1]. The highest incidence was noted in an Indian study conducted by Chakravarthi and Babu [14]. Our study showed unilateral pterygospinous bar was seen in 39 (19.5%) skulls and unilateral pterygoalar bar in 50 (25%) skulls. Similar findings were noted by Kavitha Kamath and Vasantha [5] in Karnataka, India

Table 3: Comparison of the presence of pterygospinous and pterygoalar bar on both sides of foramen ovale

Ossification status	Pterygospinous bar (%)	Pterygoalar bar (%)
Absent	154 (77)	144 (72)
Unilateral	39 (19.5)	50 (25)
Bilateral	7 (3.5)	6 (3)

$X^2=1.772, p=0.412$

population but very low incidence was noted by Jansirani *et al.* [15] and Yadav *et al.* [12].

In Table 4 we have summarized the differences between pterygospinous and pterygoalar bar in various ethnic populations conducted worldwide (Table 4).

These ligaments' abnormal ossification can compress nearby structures, leading to challenges during localized surgeries, and significantly impede clinical and diagnostic processes [16]. These formations create crucial interactions with the otic ganglion, middle meningeal vessels, tympanic nerve, medial and lateral pterygoid muscles, mandibular nerve and its branches, and these formations occupy a deep and high area of the infratemporal fossa. These can produce changes that are clinically significant when they are crushed up against the bony structures [17,18]. The nearby osseous bars around the foramen ovale may have an impact on how the structures pass through this aperture anatomically and may alter their path, trapping them between the muscles and osseous structures and resulting in neuralgia [19]. An ossified pterygospinous ligament can compress the facial nerve's chorda tympani branch, impairing taste perception in the anterior two-thirds of the tongue [9] and blood supply to the trigeminal ganglion [3]. In addition, neurological symptoms, including parotid gland alterations in saliva, chewing difficulties, and pain and numbness in the buccal and tongue regions [14,20,21].

Mandibular nerve compression or entrapment of the motor or sensory branches can cause paresis, or weakening, in the innervated muscle, and paresthesia or neuralgia in the sensory branches [22]. The pterygoalar ligament totally precludes passage from the foramen ovale to the mandibular nerve or trigeminal ganglion via the supra or infrazygomatic approach. The majority of previous studies noted the prevalence of ossified ligaments in various parts of the world. These have extremely little clinical implications. Because the combination of additional traits makes them the rarest of the rare, different impediments, in addition to the pterygospinous and pterygoalar bar, have been explored [23].

The lingual nerve, which passes between the ossified pterygospinous ligament and the medial pterygoid muscle, may become trapped as a result [24]. This may result in pain associated with articulation, anesthesia of the lingual gums, and sensory impairment in the anterior two-thirds of the tongue. Dentists must always be aware of the possible signs of neurovascular compression in regions where the lingual nerve is situated [4,25].

Since the entire pterygoalar bar is more pronounced and has the potential to completely obliterate the passage to foramen ovale, it is clinically more significant than the complete pterygospinous bar [8,26]. These ossified ligaments may impede the needle's ability to pass through the foramen ovale during surgical procedures necessary to relieve trigeminal neuralgia, making it impossible to anesthetize the trigeminal ganglia or the mandibular nerve [19,25].

It is advised to use an inframandibular route to the trigeminal ganglion rather than a standard supramandibular or transzygomatic method to overcome the failure of a trigeminal ganglion block if these bars are found before the procedures. Therefore, to see the foramen ovale and its associated structures, radiological guidance is necessary, which facilitates and improves puncture accuracy [19]. While doing invasive

Table 4: Comparison between pterygospinous and pterygoalar bar in various populations

S. no.	Author	Year	Populations	n	Pterygospinous bar (%)		Total	Pterygoalar (%)		Total
					Complete	Incomplete		Complete	Incomplete	
1	Kapur et al. [10]	2000	Croatian	305	3.60	14.70	18.36	5.90	14.40	20.30
2	Peker et al. [21]	2002	Anatolians	452	8.80	-	8.80	7.50	-	7.50
3	Skrzat et al. [19]	2005	Poland	70	-	-	-	5.71	1.42	7.13
4	Das and Paul [9]	2007	New Delhi	50	-	1.00	1.00	-	-	-
5	Nayak et al. [28]	2007	Karnataka	416	5.76	3.84	9.61	-	-	-
6	Antonopoulou et al. [11]	2008	Greek	50	2.00	25.00	27.00	1.00	7.00	8.00
7	Tubbs et al. [29]	2009	American	154	0.65	0.65	1.30	0.65	0.65	1.30
8	Suazo et al. [17]	2010	Brazil	312	1.60	13.14	14.74	3.84	22.43	26.27
9	Rosa et al. [8]	2010	Brazil	93	19.36	8.61	27.97	12.91	49.44	62.35
10	Daimi et al. [25]	2011	Maharashtra	90	-	-	-	7.77	1.10	8.87
11	Shinde et al. [22]	2011	Karnataka	65	-	3.07	3.07	-	-	-
12	Aggarwal et al. [30]	2012	Patiala	67	5.97	13.43	19.40	-	-	-
13	Chakravarthi et al. [16]	2013	Kurnool	100	3	-	3	14	-	14
14	Saran et al. [7]	2013	Chennai	80	1.25	7.50	8.75	-	-	-
15	Ebenraj and Viahali [31]	2014	Tamil Nadu	90	5.55	64.44	69.99	-	-	-
16	Kavitha Kamath and Vasantha	2014	Shimoga	100	5.88	94.12	100	3.33	96.67	100
17	Yadav et al. [12]	2014	Kanpur	500	4	6.20	-	-	-	-
18	Goyal and Jain [32]	2015	Punjab	75	-	-	-	-	22.67	22.67
19	Vaishali et al. [33]	2018	Chennai	90	-	-	-	1.11	12.22	13.33
20	Singh and Niranjana [23]	2019	Uttarakhand	530	3.96	5.84	9.00	0.18	-	0.18
21	Kirwale and Sukre [34]	2020	Maharashtra	112	-	-	-	7.14	1.78	8.92
22	Sadashiv et al. [35]	2022	Dharwad	100	9.10	16.09	25.19	-	-	-
23	Present study	2023	Rajasthan	200	3	10.25	13.25	3.75	11.75	15.5

treatments in or near the infratemporal fossa, anesthesiologists, dentists, oral and maxillofacial surgeons, and neurosurgeons may find these details very helpful [3]. Shang et al. successfully accessed the foramen ovale with the needle across the pterygoalar bar using the Hartel approach during thermocoagulation for the treatment of trigeminal neuralgia [27].

CONCLUSION

Given the prevalence of these bars in the human population, it becomes imperative to broaden our understanding of the morphology and topography of these formations. Surgeons and practitioners require more precise information regarding the heterogeneity of human shape in order to increase treatment outcomes. Understanding the cranial base's osseous bridges is helpful in diagnosing and treating complex clinical neuralgias that affect the oral and maxillofacial regions.

Therefore, knowledge of anatomical structures and to evaluate them radiographically aids surgeons in making appropriate plans that improve the success rate of surgeries for trigeminal neuralgias. Therefore, a thorough anatomical analysis of this variation can aid in the understanding of neurological diseases as well as improve the efficacy of surgical interventions.

AUTHORS CONTRIBUTION

Ritubhi Mehta: Investigation, Writing-original draft, preparation, Literature search, Data analysis. Jagmohan Sharma: Conceptualization, Methodology, Resources, Validation, Writing-review and editing, Supervision. Pankaj Kumar Singh: Formal analysis, Writing-review, and editing, Validation. Prabhjot kaur: Formal analysis, Writing-review and editing, Data analysis, Validation.

CONFLICTS OF INTERESTS

Nil.

AUTHORS FUNDING

None.

REFERENCES

- Natsis K, Piagkou M, Skotsimara G, Totlis T, Apostolidis S, Panagiotopoulos NA, et al. The ossified pterygoalar ligament: An anatomical study with pathological and surgical implications. *J Craniomaxillofac Surg.* 2014 Jul 1;42(5):e266-70. doi: 10.1016/j.jcms.2013.10.003, PMID 24290255

- Coussens AK, Wilkinson CR, Hughes IP, Morris CP, van Daal A, Anderson PJ, et al. Unravelling the molecular control of calvarial suture fusion in children with craniosynostosis. *BMC Genomics.* 2007 Dec 12;8(1):458. doi: 10.1186/1471-2164-8-458, PMID 18076769
- Tubbs RS. *Anatomy, Imaging and Surgery of the Intracranial Dural Venous Sinuses.* Netherlands: Elsevier Health Sciences; 2019. p. 251.
- Piagkou M, Demesticha T, Piagkos G, Georgios A, Panagiotis S. Lingual nerve entrapment in muscular and osseous structures. *Int J Oral Sci.* 2010 Dec;2(4):181-9. doi: 10.4248/IJOS10063, PMID 21404967
- Kavitha Kamath B, Vasantha K. Anatomical study of pterygospinous and pterygoalar bar in human skulls with their phylogeny and clinical significance. *J Clin Diagn Res.* 2014;8(9):AC10-3. doi: 10.7860/JCDR/2014/9326.4888, PMID 25386415
- Pearce JM. Henry Gray's anatomy. *Clin Anat.* 2009;22(3):291-5. doi: 10.1002/ca.20775, PMID 19280653
- Saran RS, Ananthi KS, Subramaniam A, Balaji MT, Vinaita D, Vaithianathan G. Foramen of civinini: A new anatomical guide for maxillofacial surgeons. *J Clin Diagn Res.* 2013 Jul;7(7):1271-5. doi: 10.7860/JCDR/2013/5100.3115, PMID 23998043
- Rosa RR, Faig-Leite H, Faig-Leite FS, Moraes LC, Moraes ME, Filho EM. Radiographic study of ossification of the pterygospinous and pterygoalar ligaments by the Hirtz axial technique. *Acta Odontol Latinoam.* 2010;23(1):63-7. PMID 20645646
- Das S, Paul S. Ossified pterygospinous ligament and its clinical implications. *Bratisl Lek Listy.* 2007;108(3):141-3. PMID 17682541
- Kapur E, Dilberović F, Redzepagić S, Berhamović E. Variation in the lateral plate of the pterygoid process and the lateral subzygomatic approach to the mandibular nerve. *Med Arh.* 2000;54(3):133-7. PMID 11117007
- Antonopoulou M, Piagou M, Anagnostopoulou S. An anatomical study of the pterygospinous and pterygoalar bars and foramina - their clinical relevance. *J Craniomaxillofac Surg.* 2008;36(2):104-8. doi: 10.1016/j.jcms.2007.05.009, PMID 18280174
- Yadav A, Kumar V, Niranjana R. Pterygospinous bar and foramen in the adult human skulls of North India: Its incidence and clinical relevance. *Anat Res Int.* 2014;2014:286794. doi: 10.1155/2014/286794, PMID 24963408
- von Lüdinghausen M, Kageyama I, Miura M, Alkhatib M. Morphological peculiarities of the deep infratemporal fossa in advanced age. *Surg Radiol Anat.* 2006;28(3):284-92. doi: 10.1007/s00276-006-0078-z, PMID 16470343
- Chakravarthi K, Babu K. An anatomical study of the pterygo-alar bar and porus crotaphiticus buccinatorius. *Int J Health Sci.* 2012;1(3):3-9.

15. Jansirani DD, Mugunthan N, Anbalagan J, Sudha Rao SS. A study on ossified pterygospinous and pterygoalar ligaments in Indian skulls. *Natl J Basic Med Sci.* 2012;3(2):103-8.
16. Chakravarthi K, Nelluri V, Gandrakota R. Abnormal bone outgrowths and osseous structures around the foramen ovale may leads to mandibular compression or entrapment neuropathy. *Int J Bioassays.* 2013;2:922-5.
17. Suazo GI, Zavando MD, Smith RL. Anatomical study of the pterygospinous and pterygoalar bony bridges and foramens in dried crania and its clinical relevance. *Int J Morphol.* 2010;28(2):405-8.
18. Verma RK, Rani A, Rani A, Chopra J, Pankaj AK, Kumar N, et al. Civinini bar: Incidence in North Indians and its clinical relevance. *Natl J Clin Anat.* 2013;2(3):128.
19. Skrzat J, Walocha J, Srodek R. An anatomical study of the pterygoalar bar and the pterygoalar foramen. *Folia Morphol (Warsz).* 2005;64(2):92-6. PMID 16121326
20. Rossi AC, Freire AR, Manoel C, Prado FB, Botacin PR, Caria PH. Incidence of the ossified pterygoalar ligament in Brazilian human skulls and its clinical implications. *Braz J Morphol Sci.* 2011;28:69-71.
21. Peker T, Karaköse M, Anil A, Turgut HB, Gülekon N. The incidence of basal sphenoid bony bridges in dried crania and cadavers: Their anthropological and clinical relevance. *Eur J Morphol.* 2002;40(3):171-80. doi: 10.1076/ejom.40.3.171.16686, PMID 14566610
22. Shinde VS, Mallikarjun M, Patil R. A study on an ossified pterygospinous ligament. *J Clin Diagn Res.* 2011;5(5):978-9.
23. Singh AK, Niranjana R. Study of pterygospinous and pterygoalar bars in relation to foramen ovale in dry human skulls. *Natl J Clin Anat.* 2019;8(3):97-100. doi: 10.1055/s-0039-1698602
24. Erdogmus S, Pinar Y, Celik S. A cause of entrapment of the lingual nerve: Ossified pterygospinous ligament - a case report. *Neuroanatomy.* 2009;8:43-5.
25. Daimi SR, Siddiqui AU, Gill SS. Analysis of foramen ovale with special emphasis on pterygoalar bar and pterygoalar foramen. *Folia Morphol (Warsz).* 2011;70(3):149-53. PMID 21866524
26. Patnaik VV, Singla RK, Bala S. Bilateral pterygo-alar bar and porus crotaphitico buccinatorius: A case report. *J Anat Soc India.* 2001;50(2):161-2.
27. Shang Q, Lin F, Mu Q, Tan S, Wang H, Gao Y. Successful percutaneous cannulation of foramen ovale obstructed by completely ossified pterygoalar ligament using the Hartel approach: Two case reports. *Med (Baltimore).* 2023;102(25):e34102. doi: 10.1097/MD.00000000000034102, PMID 37352068
28. Nayak SR, Saralaya V, Prabhu LV, Pai MM, Vadgaonkar R, D'Costa S. Pterygospinous bar and foramina in Indian skulls: Incidence and phylogenetic significance. *Surg Radiol Anat.* 2007;29(1):5-7. doi: 10.1007/s00276-006-0154-4, PMID 17164987
29. Tubbs RS, May WR, Apaydin N, Shoja MM, Shokouhi G, Loukas M, et al. Ossification of ligaments near the foramen ovale: An anatomic study with potential clinical significance regarding transcutaneous approaches to the skull base. *Neurosurgery.* 2009;65(6 Suppl):60-4.; discussion 64. doi: 10.1227/01.NEU.0000345952.64041.9C, PMID 19935003
30. Aggarwal B, Gupta M, Kumar H. Ossified ligaments of the skull. *J Anat Soc India.* 2012 Jun 1;61(1):37-40. doi: 10.1016/S0003-2778(12)80010-4
31. Ebenraj TJ, Vishali N. Pterygospinous bar and multiple Civinini foramen- a rare anatomical variant and its clinical implications. *Int J Curr Res Rev.* 2014;6(10):126-33.
32. Goyal N, Jain A. An anatomical study of pterygoalar bar and its clinical relevance. *CHRISMED J Health Res.* 2015;2(4):333-6. doi: 10.4103/2348-3334.165744
33. Vaishali N, Ebenraj J, Rajathi G, Charanya N. Anatomical analysis of the abnormal bone outgrowth with special emphasis on pterygoalar bar and ITSCROTAPH-ITICO buccinatorius foramen. *Int J Anat Res;*6(1.2):4963-7.
34. Kirwale VS, Sukre SB. Study of anatomical variations of foramen ovale and pterygoalar bar with its clinical significance. *MIJOANT.* 2020;14(1):1-5. doi: 10.26611/10011411
35. Sadashiv R, Managutti S, Kulkarni V, Kulkarni AV, Dixit U. Morphological measurements of innominate foramina and bony spurs along the base of sphenoid as a potential risk factor for neurovascular entrapment, radiological interpretation and surgical access. *Malays J Med Sci.* 2023;30(2):90-5. doi: 10.21315/mjms2023.30.2.8, PMID 37102056