

APPLICATION OF SCROTAL ULTRASOUND IMAGING IN CLINICOPATHOLOGICALLY SUSPECTED CASES OF MALE INFERTILITY – A PROSPECTIVE STUDY IN A PERIPHERAL MEDICAL COLLEGE IN WEST BENGAL

PRASUN DAS*

Department of Radio-diagnosis, Tamralipto Government Medical College, Tamluk, West Bengal, India.

*Corresponding author: Prasun Das; Email: prasunprasun466@gmail.com

Received: 10 May 2024, Revised and Accepted: 22 June 2024

ABSTRACT

Objectives: The objective of this study was to identify various scrotal and extra-scrotal factors with the use of scrotal ultrasound causing male infertility and their correlation with clinical and radiological findings.

Methods: This prospective cross-sectional study was done on 100 male patients having suspected infertility referred to radiology department with clinical notes and pathological findings. All the patients underwent only scrotal ultrasonography with high frequency transducer having a frequency of 7.5 MHz and color Doppler wherever indicated.

Results: In this study, most commonly detected etiology by clinical suspicion and ultrasound was varicocele. Ultrasound detected more etiologies compared to physical examination. Most commonly detected pathology both by clinical and scrotal ultrasound evaluation was varicocele. p-value was 0.0001 showing extreme statistical significance.

Conclusion: Scrotal ultrasonography is important non-invasive diagnostic tools that minimize the need for more invasive studies in the evaluation of male infertility.

Keywords: Male infertility, Ultrasound, Scrotal, Testicular.

© 2024 The Authors. Published by Innovare Academic Sciences Pvt Ltd. This is an open access article under the CC BY license (<http://creativecommons.org/licenses/by/4.0/>) DOI: <http://dx.doi.org/10.22159/ajpcr.2024v17i8.51388>. Journal homepage: <https://innovareacademics.in/journals/index.php/ajpcr>

INTRODUCTION

The failure to become pregnant following regular unprotected sexual activity for a year is referred to as infertility in the current setting. In 20–42% of cases, male infertility is the primary cause; in the remaining 10–20% of individuals, it contributes [1,2]. Blockages that stop sperm from being delivered or disorders that impair sperm function or production are the most common causes of male infertility. When a couple has tried to conceive for more than a year, the workup for infertility is often started; however, if there is a strong suspicion of infertility and the female spouse is older than 35, it may be started earlier. Imaging is essential for determining the presence of potentially treatable infertility reasons, such as sperm transport-obstructing illnesses and congenital abnormalities. In addition to semen analysis, a thorough medical history and physical examination should be performed, ideally with the female spouse present. In addition, pertinent genetic, imaging, and endocrine tests must be carried out. Pre-testicular and post-testicular factors can all contribute to male infertility. High-resolution imaging of the prostate, seminal vesicles, and distal vas deferens is made possible by transrectal ultrasound, which is also used to diagnose obstructive azoospermia. Blockages in the sperm transport system or anomalies in the vas deferens, ejaculatory duct, or epididymis can cause obstructive azoospermia. In addition to evaluating the testicles, epididymis, and proximal vas deferens, scrotal ultrasonography can identify anomalies in the testis and paratesticular structures such as varicoceles and aberrant epididymis. It can also reveal secondary alterations brought on by obstruction of the distal genital duct [3].

Aim

This study evaluated prospectively the role of ultrasonography in peripherally located medical college – hospital-based population to identify various scrotal and extra-scrotal factors with the use of scrotal ultrasound causing male infertility and their correlation with clinical and radiological findings.

METHODS

This prospective cross-sectional study is being conducted on 100 male patients who complained of infertility and visited the radiology department of Tamralipto Government Medical College, Tamluk, over the course of a year, from November 1, 2022, to October 31, 2023.

All the patients were referred for scrotal ultrasonography with high-frequency transducer having a frequency of 7.5 MHz and color Doppler wherever indicated.

Study subjects

Patients were only chosen if they had never become fathers or if two successive semen samples taken at least 5 days apart had been proven to be abnormal.

Inclusion criteria

The following criteria were included in the study:

1. Males presenting with infertility and abnormal semen analysis
2. Any case of infertility with coincident scrotal findings on clinical examination
3. Patients had never attained fatherhood

Exclusion criteria

The following criteria were excluded from the study:

1. Any case of infertility attributable to known female causes
2. Infertility due to impotence
3. Infertility due to known pre-testicular causes
4. Patients not giving consent to be a part of the study
5. Patients having any acute scrotal pathology
6. Patients having any associated serious systemic conditions
7. Patients having incomplete medical records
8. Patients having HBsAg and HIV status positive

9. Patients who were referred to other center after clinical, laboratory, and radiological investigation.

Institutional Review Board approval for conducting this study was obtained and informed consent of all 100 patients was obtained. The patients those were selected based on above criteria carried relevant clinical notes and pathological reports (semen analysis report, serum follicle-stimulating hormone, testosterone, and luteinizing hormone) and prolactin hormone with them. Clinical note contained detailed history and physical examination with special attention to any history suggestive of mumps, trauma to the testes, any operation, similar illness in the past, evaluation of penis including location of the urethral meatus, presence of varicocele, secondary sexual characteristics including body habitus, hair distribution, and pattern of breast development, and at last digital rectal examination. All scrotal ultrasound scans were done using a linear probe (PHILIPS HD7, 7.5 MHz).

Statistical analysis

The obtained data were subjected to statistical analysis using statistical software Statistical Package for the Social Sciences version 20.0. Data were expressed as mean± standard deviation and statistical significance was analyzed by Chi-square test. Spearman’s correlation test was performed to assess the linear relationship between parameters.

RESULTS AND DISCUSSION

In this study, maximum number of patients were between the age 30 and 39 years of age (65%) (Fig. 1) with mean age 31.1 years. In our study, most common clinical finding that was noted was varicocele (40%) followed by hydrocele (10%). Most common etiology found on scrotal ultrasound (with Doppler) was varicocele (50%) followed by epididymal cyst/spermatocele (15%) (Fig. 2). In our study, only grade 4 and 5 of varicocele showed reduced sperm count (20.12 million per ejaculate in grade 4 and 15.23 million per ejaculate in grade 5) (Table 1).

In our study, 100% varicoceles were on isolated left side. In all cases (100%), testicular volume was within normal range (20–25 cc). In our study, there was an irregular distribution of mean sperm counts among patients with different sonographic findings.

Finding the reasons of infertility, such as congenital defects and conditions that impede sperm movement and may be treatable, is the primary use of imaging. Imaging can also direct techniques for sperm aspiration from the epididymis or seminiferous tubules, which can then be utilized for intracytoplasmic sperm injection or *in vitro* fertilization [3]. In our study, the mean age having suspected male infertility was 31.1 years, which is perfectly correlating with the study done by Kaushal *et al.* [4]. Most commonly clinically detected pathology in our study was varicocele (40%) followed by hydrocele (10%). In the study done by Mohi *et al.* [5], varicocele was also the most frequently detected finding on palpation (32%) followed by hydrocele (14%). In our study, all our varicocele were of left-sided isolated variety only (100%) (Table 2). In the study done by Raj [6], 80% of varicocele was of the left side and 42% was of the right sided, all right sided varicocele was associated with the left side. Most commonly detected pathology detected by scrotal ultrasound was varicocele (50%) (Fig. 3), followed by epididymal cyst (15%) (Fig. 4), hydrocele (10%), undescended testis (2%), and testicular microlithiasis (5%) (Fig. 5). In their evaluation of 1372 infertile men using Doppler ultrasonography, Pierik *et al.* [7] found that a noteworthy fraction of the infertile men (38%) had an abnormality in their scrotal region; a tumor was found in 0.5%, varicocele in 29.7%, and epididymal cysts in 7.6%. Ibrahim *et al.* [8], in their study on 115 infertile men, found varicocele in 39% cases, hydrocele in 26% cases, epididymo-orchitis in 7% cases, epididymal cyst in 5% cases, and testicular microlithiasis in 4% cases. Sakamoto *et al.* [9], in their study on 545 infertile men, found varicocele in 45% cases on physical examination as compared to 51.4% cases detected on ultrasound, which almost perfectly correlated with our study. Patients in our research with varying sonographic results showed an uneven distribution of mean sperm counts (Table 3). Mean sperm counts were normal in normal and cases with testicular microlithiasis. In other major cases, sperm counts were below normal. My study correlated with the study done

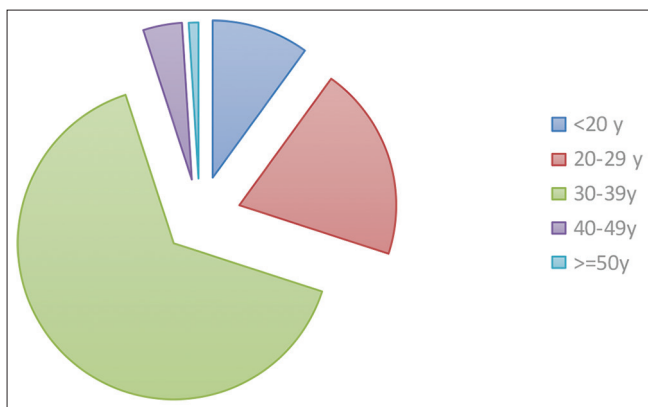


Fig. 1: Age distribution

Table 1: Relation with grades of varicocele with mean sperm count/ejaculate

Grade	Cases	Mean sperm count/ejaculate (million/mL of sperm)
1	20	33.67±14.80
2	15	30.77±16.90
3	10	30.98±10.23
4	4	20.12±6.57
5	1	15.23+/- 8.12

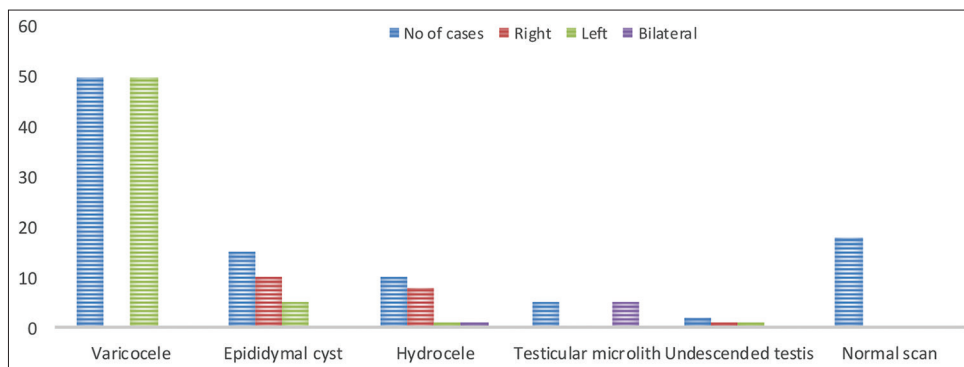


Fig. 2: Distribution based on scrotal ultrasound findings

Table 2: Distribution based on clinical findings

S. No.	Clinical Finding	Distribution				% of cases			
		Total	Rt side	Lt side	Bilateral	Total	Rt side	Lt side	Bilateral
1.	Varicocele	40	0	40	0	40	0	40	0
2.	Epididymal cyst/spermatocele	3	2	1	0	3	2	1	0
3.	Hydrocele	10	8	1	1	10	8	1	1
4.	Absent unilateral testis	2	1	1	0	2	1	1	0
5.	Clinically insignificant	45				45			

Table 3: Relationship between sonographically detected etiologies with mean sperm count

Etiology	Cases	Mean sperm count/ ejaculate (million/mL)
Varicocele	50	30.3±12.6
Hydrocele	10	28.78±2.9
Epididymal cyst/spermatocele	15	29.56±17.89
Undescended testis	2	12.19±12.76
Testicular microlithiasis	5	39.56±18.98
Normal scan	18	40.65±6.78

Table 4: Comparison of clinical and scrotal ultrasound findings

Findings	Clinical (%)	Ultrasound (%)
Varicocele	40 (40)	50 (50)
Epididymal cyst/spermatocele	3 (3)	15 (15)
Hydrocele	10 (10)	10 (10)
Undescended testis	2 (2)	2 (2)
Testicular microlithiasis	0 (0)	5 (5)
Normal/insignificant	45 (45)	18 (18)
Total	100 (100)	100 (100)
χ^2	57.10	
p-value	0.0001 – Extremely statistically significant	
r value	0.7304 – Moderately positive correlation	

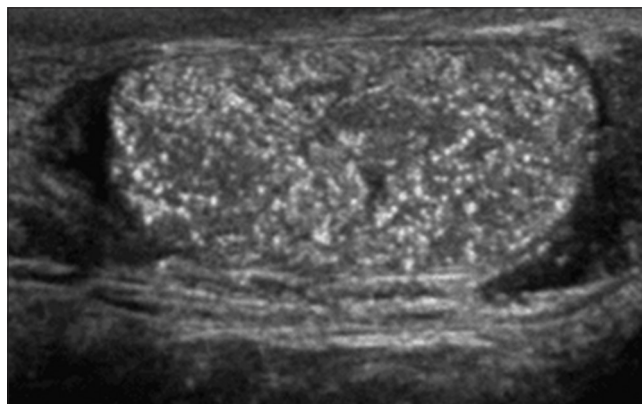


Fig. 5: Case of testicular microlithiasis

by Catanzariti *et al.* [10] which showed that testicular microlithiasis did not affect sperm parameters. There was a definite relationship between grades of varicocele and mean sperm counts. Patients that had lower grades of varicocele have a near normal sperm counts and those patients that had higher grades of varicocele were having low sperm counts.

Our study showed that clinical finding has moderately positive correlation with scrotal sonography findings. p value of 0.0001 shows extremely statistically significant study (Table 4).

CONCLUSION

This prospective cross-sectional study emphasizes scrotal ultrasound with Doppler as very cost-effective imaging investigation for diagnosing scrotal pathologies responsible for causing male infertility. A systemic, logical, and thorough evaluation of infertile men is mandatory to identify patients with potentially correctable defects. Scrotal ultrasound can detect abnormalities in mediastinum testis, epididymis, and proximal vas deferens. It can also show secondary changes due to obstructive abnormalities in distal genital duct system. Scrotal ultrasound is non-invasive and allows multiplanar planes for evaluation. As varicocele is leading cause, all suspected individuals should undergo color Doppler enables scrotal sonography.

Limitations

1. Transrectal ultrasound (TRUS) is not done in any patients in my study as there is non-availability of probe in my department. TRUS is essential for detecting central sources for sperm obstruction. Hence, many more etiologies are not found in our study
2. Small sample size
3. Surgical findings are not included so sensitivity and other diagnostic accuracy parameters are not evaluated.

AUTHORS' CONTRIBUTIONS

Dr. Prasun Das did all relevant works necessary for manuscript writing.

CONFLICTS OF INTEREST

Nil.

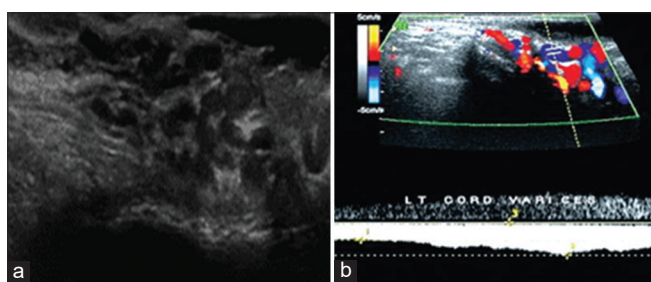


Fig. 3: (a and b) shows case of varicocele with color and spectral Doppler findings

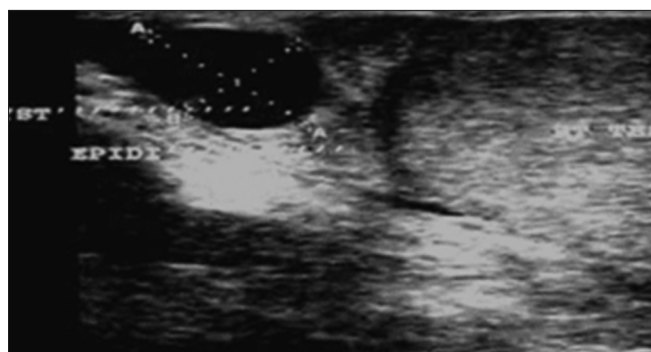

Fig. 4: Case of epididymal cyst

AUTHOR'S FUNDING

Nil.

REFERENCES

1. Glazer CH, Eisenberg ML, Tøttenborg SS, Giwercman A, Flachs EM, Bräuner EV, *et al.* Male factor infertility and risk of death: A nationwide record-linkage study. *Hum Reprod.* 2019;34(11):2266-73. doi: 10.1093/humrep/dez189, PMID 31725880
2. Agarwal A, Baskaran S, Parekh N, Cho CL, Henkel R, Vij S, *et al.* Male infertility. *Lancet.* 2021;397(10271):319-33. doi: 10.1016/S0140-6736(20)32667-2, PMID 33308486
3. Ammar T, Sidhu PS, Wilkins CJ. Male infertility: The role of imaging in diagnosis and management. *Br J Radiol.* 2012 Nov;85(Spec Iss 1):S59-68. doi: 10.1259/bjr/31818161, PMID 22763036
4. Kaushal R, Gurnani N, Kumar M, Dada R, Kumar R. Male infertility in India: Demographics, aetiology and outcomes of standard clinical practice. *Natl Med J India.* 2020;33(6):340-3. doi: 10.4103/0970-258X.321136, PMID 34341210
5. Mohi JK, Mittal MS, Kaur NK, Kaur A, Garg D. Role of trans rectal and scrotal ultra sonography in male infertility. *Int J Med Res Rev.* 2018;6(2):78-84. doi: 10.17511/ijmrr
6. Raj V. Role of ultrasound in male infertility. *Sch J Appl Med Sci.* Apr 2018;6(4):1782-95.
7. Pierik FH, Dohle GR, van Muiswinkel JM, Vreeburg JT, Weber RF. Is routine scrotal ultrasound advantageous in infertile men? *J Urol.* 1999;162(5):1618-20. doi: 10.1016/S0022-5347(05)68180-3, PMID 10524881
8. Ibrahim M, Tabari A, Igashi J, Lawal S, Ahmed M. Scrotal Doppler ultrasound evaluation in Zaria, Nigeria. *Niger J Basic Clin Sci.* 2016;13(2):89. doi: 10.4103/0331-8540.187356
9. Sakamoto H, Saito K, Shichizyo T, Ishikawa K, Igarashi A, Yoshida H. Color Doppler ultra sonography as a routine clinical examination in male infertility. *Int J Urol.* 2006 Aug;13(8):1073-8. doi: 10.1111/j.1442-2042.2006.01499.x, PMID 16903932
10. Catanzariti F, Cantoro U, Lacetera V, Muzzonigro G, Polito M. Testicular microlithiasis and dyspermia: Is there any correlation?. *Arch Ital Urol Androl.* 2014 Mar 28;86(1):20-2. doi: 10.4081/aiua.2014.1.20, PMID 24704926