

## EFFECTIVENESS OF CHITOSAN-BASED 0.5% TETRACYCLINE GEL AND FREEZE-DRIED PLATELET-RICH PLASMA ON POST-PERIODONTAL SURGERY HEALING: CLINICAL AND IMMUNOHISTOCHEMICAL EVALUATION

RIO SIMANJUNTAK<sup>1</sup>, PITU WULANDARI<sup>2\*</sup>, DENNY SATRIA<sup>3</sup>, KWARTARINI MURDIASTUTI<sup>4</sup>, ARMIA SYAHPUTRA<sup>2</sup>

<sup>1</sup>Resident of Periodontology, Faculty of Dentistry, Universitas Sumatera Utara, Medan, Indonesia. <sup>2</sup>Department of Periodontology, Faculty of Dentistry, Universitas Sumatera Utara, Medan, Indonesia. <sup>3</sup>Department of Pharmaceutical Biology, Faculty of Pharmacy, Universitas Sumatera Utara, Medan, Indonesia. <sup>4</sup>Department of Periodontology, Faculty of Dentistry, Universitas Gadjah Mada, Yogyakarta, Indonesia  
\*Corresponding author: Pitu Wulandari; \*Email: pitu.wulandari@usu.ac.id

Received: 25 Jan 2024, Revised and Accepted: 08 Apr 2024

### ABSTRACT

**Objective:** Periodontal treatment widely uses tetracycline as a local antibiotic because it has broad-spectrum antibacterial and anticollagenase properties. Chitosan-based 0.5% tetracycline gel, there was an increase in the performance of tetracycline because chitosan released the drug locally, was slower, controlled, lasted longer, had better stability and lower toxicity. Periodontal treatment is currently trending using Platelet-Rich Plasma (PRP) because of its properties, which release many growth factors. To facilitate clinical administration, PRP was developed by the freeze-drying process to become allogeneic Freeze Dried PRP (FD-PRP) obtained from the blood bank. Combination can help accelerate the healing of periodontal surgical wounds. To evaluate the effectiveness of administration of chitosan-based 0.5% tetracycline gel and FD-PRP.

**Methods:** Laboratory experimental study with posttest-only control group design on 30 Wistars-induced periodontitis. The sample was divided into 5 groups: negative and positive control group and 3 periodontal surgical intervention groups accompanied by drug administration. The examination of clinical parameters such as Bleeding on Probing (BoP) and Pocket Depth (PD) as well as immunohistochemical parameters such as fibroblast growth factor-2 (FGF-2) were evaluated on days 3 and 14.

**Results:** This study showed a significant decrease in BoP on day 3 ( $p=0.022$ ) and 14 ( $p=0.009$ ), decrease in PD on day 14 ( $p=0.007$ ) and a significant increase in FGF-2 on day 3 ( $p=0.024$ ) and decrease on day 14 ( $p=0.017$ ).

**Conclusion:** Administration of chitosan-based 0.5% tetracycline gel and FD-PRP were effective in periodontal surgical wound healing because it reduced BoP and PD and increased fibroblast cell proliferation through increasing FGF-2 expression.

**Keywords:** Chitosan, PRP, Periodontitis, Tetracycline, Wound healing

© 2024 The Authors. Published by Innovare Academic Sciences Pvt Ltd. This is an open access article under the CC BY license (<https://creativecommons.org/licenses/by/4.0/>) DOI: <https://dx.doi.org/10.22159/ijap.2024.v16s2.13> Journal homepage: <https://innovareacademics.in/journals/index.php/ijap>

### INTRODUCTION

Periodontitis is a chronic inflammatory condition that develops, causing tissue damage due to prolonged inflammation and disruption of homeostasis in interaction between microorganisms and the host [1, 2]. Putative pathogenic periodontal microorganisms are responsible for gingival tissue damage and disease development [3]. Periodontal treatment consists of instructions on oral hygiene, removing microorganisms and calculus with or without supporting treatment such as additional antimicrobial administration and with or without surgical treatment [1, 4].

Healing is an inflammatory response phase related to new physiological and anatomical relationships in the disturbed body elements [5]. Cell and biochemical events in it are divided into several stages: the hemostasis phase, which occurs immediately after injury and inflammation simultaneously lasts for 3 d; the proliferation phase involves the formation of connective tissue, which lasts for days or weeks and the remodeling phase in the form of collagen formation with complete wound closure [6, 7].

The Platelet-Rich Plasma (PRP) concept was initially used as a transfusion product, then developed in other health fields and recently, its application has increased in the field of tissue regeneration and healing [8]. The type of PRP used is fresh autologous because of its guaranteed safety when applied to severe medical conditions. However, clinically it still has weaknesses in terms of products, dosages, treatment protocols and medical facilities [9]. The next development is FD-PRP through an autologous and allogeneic lyophilization process using the blood of healthy people who have passed screening. It can be stored at room temperature for several months is easy to shape for reuse according

to medical demands [8, 9]. In animal studies using freeze-dried PRP (FD-PRP), promising results were found because there was a significant increase in the percentage of blood vessels and the number of myofibroblasts. This clinical trials because FD-PRP is a beneficial option for patients [10]. Other studies on test animals also reveal the limitations of PRP; the blood must be taken immediately before surgery and must be activated during surgery to maintain efficacy and invasiveness, so PRP needs to be isolated and preserved before surgery [11].

Fibroblasts appear on days 2-3 after injuries along with the formation of new capillaries, which provide an adequate supply of nutrients for cell proliferation. Fibroblast proliferation and the formation of new capillaries are triggered by growth factors, one of which is FGF-2 expression which increases immediately after injury and reaches a peak on 5-8 d. Fibroblasts migrate towards wound tissue and reach maximum numbers on days 7-14 [12]. Apart from playing a direct role in wound healing, FGF also acts indirectly to support epithelialization by stimulating the release of Transforming Growth Factor- $\alpha$  (TGF- $\alpha$ ) and is jointly active with Vascular Endothelial Growth Factor (VEGF) during the proliferation phase. The growth factor FGF stimulates fibroblast proliferation collagen accumulation and accelerates granulation tissue formation [13, 14].

Tetracyclines are popular for their broad-spectrum antimicrobial activity and low toxicity. Locally, tetracycline is bacteriostatic by suppressing pathogenic bacteria, which are concentrated in periodontal pockets and are strongly adsorbed onto the tooth surface so that it maintains antimicrobial activity and is able to inhibit collagenase in periodontal disease [15]. This has been confirmed by Susanto *et al.* who examined the effectiveness of chitosan-based tetracycline gel on periodontal pathogenic:

*Porphyromonas gingivalis*, *Agregatibacter actinomycetemcomitans* and *Fusobacterium nucleatum* [16]. Chitosan-based tetracycline gel has shown high viability and is non-toxic to fibroblast cells in accordance with research by Andrew et al. [17].

This study aims to evaluate the effectiveness of the application of chitosan-based 0.5% tetracycline gel, FD-PRP, and its combination on clinical (BoP and PD) and immunohistochemical parameters (FGF-2 expression) in a rat periodontitis model on day 3 and 14.

## MATERIALS AND METHODS

### Method

This research is a laboratory experimental study with a posttest-only control group design. The research sample was 30 adult male white Wistars aged 8-12 w, bodyweight 200-250 grams, had mandibular central incisors and a healthy systemic condition using the Federer formula. Sample collection and clinical parameter measurements were carried out at the Animal House, Faculty of Mathematics and Natural Sciences, Universitas Sumatera Utara. The letter of recommendation for animal research ethical approval No. 0307/KEPH-FMIPA/2021.

Acclimatization was carried out one week before the experiment started. Experimental animals were placed in each wire cage in a room with controlled temperature and humidity ( $23\pm 1$  °C and relative humidity  $60\pm 5$  %), under a 12 h light/dark cycle, with standard rat food and water provided [18]. Experimental animals were monitored routinely, including food and drink intake, urine, body weight and behavior of experimental animals as well as cleaning the cage so that it remains dry.

*P. gingivalis* ATCC@3327 bacteria were cultured in 5% Brucella bloodships primary culture medium with a 4 quadrant strick, then

incubated for 48-72 h in an anaerobic atmosphere at a temperature of 37 °C in the Clinical Microbiology Laboratory, Hospital of Universitas Sumatera Utara.

The procedure for creating the Wistars periodontitis model begins with administering general anesthesia intramuscularly using a solution of Ketamine 10% and Xylazine 2 % (2: 1), 0.12 ml/100 grams of body weight to obtain a sedation effect. The experimental animal was placed on a table to gain access to the mouth open. The ligature is inserted into the gingival sulcus of the lower incisor, forming a fig. "8" using sterile, non-resorbable silk thread combined with a single wire. Experimental animals were given a high carbohydrate diet and one week later, *P. gingivalis* were induced in the gingival sulcus. Microbiological examination was carried out on the 10th day by swabbing the sulcus area to ensure that the rats had been infected with *P. gingivalis*. After being declared infected, the high carbohydrate diet is stopped, the ligature is removed and the experimental animal is ready to be treated. Observations were carried out for 14 d [19-21].

Chitosan-based 0.5% tetracycline gel is made with a composition consisting of 2 grams of chitosan, 0.5 grams of tetracycline and 1 % lactic acid. All tools used were sterilized in the oven at 170 oC for 1 hour. The manufacturing process is carried out aseptically in a laminar airflow cabinet. A total of 2 grams of chitosan was put into the stamper, added with 1% lactic acid solution which had been diluted to 50 ml and stirred slowly until it formed a 4% chitosan hydrogel. Then, 0.5 gram of tetracycline was added and stirred slowly until homogenous and chitosan-based tetracycline gel 0.5% was formed [16]. In the second preparation, 1.5 grams of FD-PRP was added and stirred slowly until homogeneous and chitosan-based FD-PRP gel was formed [22]. In the third preparation, 0.5 gram tetracycline and 1.5 gram FD-PRP were added and stirred slowly until homogeneous and a combination of chitosan-based 0.5% tetracycline gel and FD-PRP was formed (fig. 1).



**Fig. 1: Tetracycline raw material was obtained from Hubei ChenXun Co., Ltd. (left), FD-PRP was obtained from the biotechnology laboratory, Faculty of Dentistry Universitas Gadjah Mada (middle) and chitosan was obtained from Integrated Laboratory, Faculty of Pharmacy Universitas Sumatera Utara (right)**

Before treatment, flap surgery was carried out on experimental animals using the modified Widman flap method and then treatment was given to rats according to groups, namely one group without treatment, one group flap surgery only and three groups with flap surgery treatment accompanied by administration chitosan-based tetracycline gel 0, 5%, FD-PRP and combination.

After completion of the experiment, animals were anesthetized with ether by inhalation and euthanized by cervical dislocations. The experimental protocol was carried out in accordance with laws regarding animal welfare and ethics in experimental animals. Lower jaw extremity samples were stored in 10% formalin for 2-4 h. Then, fixation was carried out for histopathological examination using the

hematoxylin-eosin staining methods. Then, staining was carried out using the immunohistochemical method with Rabbit Anti-FGF-2 Polyclonal Antibody (Bioenzy) to the manufacturer's protocol. Assessments of FGF-2 expression were seen in five fields of view assisted by two anatomical pathology specialists using a binocular microscope with 400x magnification and the help of an image processing software program on 3 and 14 d.

## RESULTS

In assessing the mean BoP on days 3 and 14, significant differences ( $p < 0.05$ ) were seen between all groups. This shows that the treatment significantly reduced the average BoP on days 3 and 14 (table 1).

**Table 1: Differences in mean BoP between groups on days 3 and 14**

Groups	Bleeding on probing ( $\bar{x}\pm SD$ )			
	Day 3	p-value	Day 14	p-value
Negative control	1.000±0.000	0.022 <sup>a*</sup>	1.000±0.000	0.009 <sup>b*</sup>
Positive control	1.000±0.000		1.000±0.000	
Tetracycline	0.330±0.577		0.000±0.000	
FD-PRP	0.330±0.577		0.000±0.000	
Tetracycline and FD-PRP	0.330±0.577		0.000±0.000	

\*Significance  $p < 0.05$ , <sup>a</sup>Kruskal-Wallis on day 3, <sup>b</sup>Kruskal-Wallis on day 14.

Evaluation of PD on day 3, it was seen that there was no significant difference ( $p > 0.05$ ) between all groups. This shows that the treatment did not significantly reduce the average PD on day 3. In

contrast, on day 14 there was a significant difference ( $p < 0.05$ ) between all groups. This shows that the treatment significantly reduced the average PD on day 14 (table 2).

**Table 2: Differences in mean PD between groups on days 3 and 14**

Groups	Pocket depth ( $\bar{x} \pm SD$ )			
	Day 3	p-value	Day 14	p-value
Negative control	1.000±0.000	0.183 <sup>a</sup>	1.000±0.000	0.007 <sup>b*</sup>
Positive control	1.000±0.000		1.000±0.000	
Tetracycline	0.333±0.577		0.000±0.000	
FD-PRP	0.333±0.577		0.000±0.000	
Tetracycline and FD-PRP	0.333±0.577		0.000±0.000	

\*Significance  $p < 0.05$ , <sup>a</sup>Kruskal-Wallis day 3, \*Significance  $p < 0.05$ , <sup>b</sup>Kruskal-Wallis day 14.

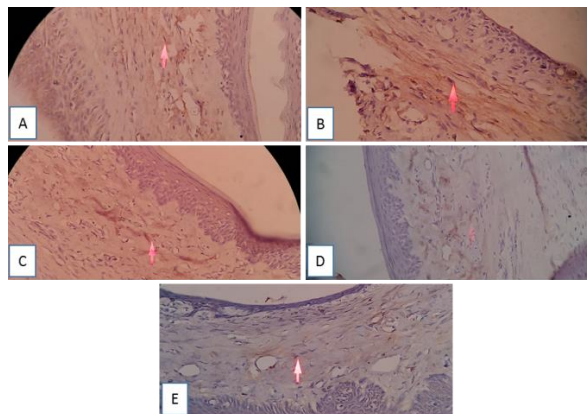
Based on the results of immunohistochemical on days 3 and 14, there was a significant difference in mean FGF-2 expression ( $p < 0.05$ ) between all groups. This shows that treatment significantly increased

the average expression of FGF-2 on days 3 and 14 (table 3). The immunohistochemical images for each group on days 3 and 14 are presented in fig. 2 and 3.

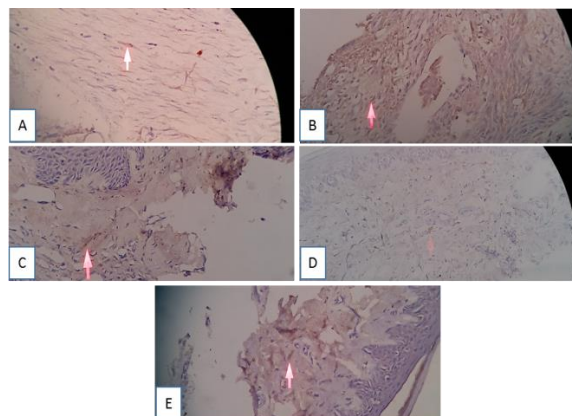
**Table 3: Differences in mean FGF-2 expression between groups on days 3 and 14**

Groups	FGF-2 expression ( $\bar{x} \pm SD$ )			
	Day 3	p-value	Day 14	p-value
Negative control	3.000±0.000	0.024 <sup>a*</sup>	3.000±0.000	0.017 <sup>b*</sup>
Positive control	3.670±0.577		4.000±0.000	
Tetracycline	4.000±0.000		2.670±0.577	
FD-PRP	3.000±0.000		3.000±0.000	
Tetracycline and FD-PRP	3.000±0.000		3.000±0.000	

\*Significance  $p < 0.05$ , <sup>a</sup>Kruskal-Wallis on day 3, <sup>b</sup>Kruskal-Wallis on day 14.



**Fig. 2: Immunohistochemical features on day 3. A. Negative control, B. Positive control, C. Tetracycline, D. FD-PRP, E. Combination (400x magnification)**



**Fig. 3: Immunohistochemical features on day 14. A. Negative control, B. Positive control, C. Tetracycline, D. FD-PRP, E. Combination (400x magnification)**

## DISCUSSION

The main strategy for periodontal treatment is mechanical debridement with scaling root planing (SRP) and periodontal surgery to remove biofilm, including all bacteria at the site of infection [23]. Several supporting periodontal treatments have been suggested, such as local delivery drugs, systemic antibiotics and systemic modulating agents to improve treatment results [24]. Stages of the wound healing process includes immediate hemostasis, acute inflammation, proliferation and maturation [25]. The proliferation stage attempts to reduce the area of tissue injury by binding to myofibroblast and fibroplasia. At this stage, the re-epithelialization process can still be observed [6]. The main activity at the proliferation stage is the process of forming new blood vessels, known as angiogenesis [6, 25].

Research by Kobayashi *et al.* have explored the suitability of biocompatible materials in regenerative treatments. New strategies for the application of platelet concentrates for tissue engineering selection of recent advances and new protocols such as lyophilized platelet concentrates and combinations of platelet concentrates with biomaterials, stem cells or drugs, all of which aim to improve wound healing outcomes [26].

Research conducted on a rat periodontitis model to assess the effectiveness of chitosan-based 0.5% tetracycline gel, FD-PRP and their combination given after periodontal surgery showed a significant reduction in BoP percentage on days 3 and 14 (table 1). This means that the administration of tetracycline and FD-PRP has an effect on the process of reducing and even eliminating tissue inflammation due to improved revascularization. This is in accordance with the research of Ervina *et al.*, SRP therapy with subgingival application of 0.7% tetracycline-based chitosan hydrogel for 7 d gave better results in reducing the papillary bleeding index [27]. This is also in accordance with the research of Mohammadi *et al.*, PRP with chitosan has a beneficial effect on wound repaired and is recommended for the treatment of various types of wounds; time has a significant effect on wound contraction [28]. The American Academy of Periodontology 2021 explained that BoP is a diagnostic tool to evaluate periodontal disease activity where the absence of BoP is very specific indicates a healthy periodontal and the continued absence of BoP during the maintenance phase is an indicator of stable periodontal health [29].

The significant decrease in mean PD on day 14 (table 2) indicates wound repair, especially in the gingival epithelium. This is in accordance with Matesanz-Perez *et al.* in a meta-analysis of five studies evaluating the effectiveness of tetracycline where the results showed a change in the mean value of PD [30]. The results of research by Sutayasa, *et al.* showed that surgical flap treatment with topical administration of tetracycline HCl 25 mg gave better results in reducing PD and gingival inflammation in chronic periodontitis patients. Topical antibiotics are effective because they reach the pocket floor and can persist for a long time in the periodontal tissue [31].

Periodontitis is a chronic inflammatory process that starts from gingivitis to damage to the alveolar bone and gingival attachment. Along the way, periodontal pockets are formed, namely subgingival filled with calculus deposits, bacterial plaque, and granulation tissue and lined with nonkeratinized inflammatory epithelium. The depth of the pocket varies depending on the duration of the disease and the location of the lesion. The size influences the choice of periodontitis treatment performed, mainly based on the use of mechanical therapy for pocket cleaning accompanied by topical anti-inflammatory and antibacterial drugs administered directly into the periodontal pocket [32]. The reduction in gingival inflammation and PD in this study can be attributed to the effectiveness of tetracycline and FD-PRP inhibits the growth of pathogenic bacteria. Chitosan also has bactericidal or bacteriostatic properties, thereby accelerating gingival epithelial repair and revascularization through angiogenesis activity. This is in accordance with research by He, *et al.* showed a close correlation between the relative expression of P. gingivalis and PD values where elimination of these pathogens can prevent the development of periodontitis [33].

Administrations of the chitosan-based 0.5% tetracycline gel to

periodontitis model showed an increase in mean FGF-2 expression on day 3 and a decrease on day 14 (table 3). In this study, the higher level of FGF-2 on day 3 was caused by FGF-2 playing a role in inducing the angiogenesis process and being involved in signal transmission between the epithelium and connective tissue [34]. The lower level of FGF-2 on day 14 was thought to occur because tissue improvements have occurred, as can be seen from the decrease in BoP and PD. The results of research by Ervina *et al.*, in a rat periodontitis model showed that the number of fibroblast cells in the periodontal ligament appeared to be greater in the group given a combination of SRP therapy accompanied by the application of 0.7% tetracycline-based on chitosan hydrogel for 7 d compared to the control group [27]. An increase in the number of fibroblast cells indicates the regeneration process induced by FGF-2 in the early phase of cell proliferation. Fibrin as an important blood component, is responsible for hemostasis because it is the first scaffold that cells encounter during the wound healing process. This was proven in studies where applying platelet-rich fibrin into periodontal infrabony resulted in reduced periodontal pocket depth and increased clinical improvement [35].

Repair of defects in the fibrous connective tissue of the periodontal ligament and bone with the delivery of growth factors encounters difficulties related to the presence of bacteria that naturally reside in the oral cavity. In many cases, the current treatment of periodontal bone defects also does not rest the normal function of tooth-supporting structures so it is difficult to regenerate functional structures properly [36,37]. Biocompatible microparticles in the management of periodontal regeneration are able to function as a controlled drug delivery system that can release growth factors to promote tissue regeneration. Periodontal tissue regeneration is one biomedical field that can benefit from the specific properties and versatility of microparticle delivery systems [36, 38].

A recently attractive strategy to promote tissue regeneration is to amplify or target cells and signaling factors that promote periodontal cell proliferation, migration, and differentiation. Soluble factors stored in the extracellular matrix of periodontal ligament, cementum, and bone are released during periodontal wound healing. Growth factors mobilize and promote the proliferation and differentiation of host cell populations in the periodontal ligament and bone. Compounds and small molecules of drugs can target key cells or pathways to promote healing. Soluble factors released during the early stages of wound healing, such as platelet-derived growth factor (PDGF), TGF- $\beta$ , fibroblast growth factor (FGF), epidermal growth factor (EGF), and insulin growth factor (IGF), is thought to induce periodontal ligament cell migration, proliferation, and extracellular matrix protein synthesis [39]. In mature periodontal tissue, fibroblasts and osteoblasts express the TGF- $\beta$  receptor. PDGF chains were also expressed during initial wound healing of gingival connective tissue and were reduced as granulation tissue replaced the fibrin clot at 7 d. Basic FGF (bFGF or FGF-2) is secreted by periodontal ligament cells and endothelial cells in both healthy and diseased periodontal ligament tissue, but this expression may decrease with age [40, 41].

Nagayasu-Tanaka's research on beagle dogs to evaluate the mechanism of FGF-2 in periodontal regeneration showed the regeneration process was the same in control and FGF-2 groups. However, compared to the control group, the mass of fibroblastic cell tissue formed was wider throughout the tooth root surface in the FGF-2 group and the height of connective tissue formed increased more significantly with the administration of FGF-2. The facilitation mechanisms of FGF-2 in periodontal regeneration demonstrated *in vivo* include (1) accelerating and increasing the proliferation of fibroblastic cells originating from the bone marrow and periodontal ligament for the formation of new tissue, (2) increasing angiogenesis, and (3) triggering expression of bone morphogenetic protein-2 (BMP-2) to facilitate osteoblastic differentiation and bone formation [41]. This shows that during the early stages of periodontal tissue regeneration, FGF-2 increases the number of fibroblastic cells, supports angiogenesis, stimulates the growth of chondrocytes and osteoblasts and collagenase expression [41, 42].

## CONCLUSION

Administration of chitosan-based 0.5% tetracycline gel and FD-PRP

after periodontal surgery can reduce BoP and PD and significantly increase FGF-2 expression on days 3 and 14.

#### ACKNOWLEDGEMENT

The authors thank to Faculty of Dentistry, Faculty of Mathematics and Natural Science, Faculty of Pharmacy Universitas Sumatera Utara and Faculty of Dentistry Universitas Gadjah Mada.

#### FUNDING

Nil

#### AUTHORS CONTRIBUTIONS

All the authors have contributed equally

#### CONFLICT OF INTERESTS

The authors certify that they have no commercial or associative interest representing a conflict of interest in connection with the manuscript.

#### REFERENCES

- Newman MG, Takei HH, Klokkevold PR, Carranza FA. Clinical periodontology. 13<sup>th</sup> ed. Amsterdam: Elsevier; 2019: 55-79, 90-111, 507-10.
- Charalambidou G, Kofidou E, Papaioannou N, Karampatakis V, Komnenou A. The effect of intrastromal PRP and oral doxycycline in corneal wound healing after alkali burn. *J Hellenic Vet Med Soc.* 2018;69(4):1213-25. doi: 10.12681/jhvms.16119.
- Dahlen G, Basic A, Bylund J. Importance of virulence factors for the persistence of oral bacteria in the inflamed gingival crevice and in the pathogenesis of periodontal disease. *J Clin Med.* 2019;8(9):1339-58. doi: 10.3390/jcm8091339, PMID 31470579.
- Sanz M, Tonetti M. Periodontitis new classification of periodontal and peri-implant diseases. *Perio Clin.* 2019;1(15):18-24.
- Bathla S, Bathla M. Periodontics revisited. New Delhi: Jaypee Brothers; 2011. p. 129-36, 187-90.
- Gonzalez AC, Costa TF, Andrade ZA, Medrado AR. Wound healing-a literature review. *An Bras Dermatol.* 2016;91(5):614-20. doi: 10.1590/abd1806-4841.20164741, PMID 27828635.
- Alven S, Aderibigbe BA. Chitosan and cellulose-based hydrogels for wound management. *Int J Mol Sci.* 2020;21(24):1-30. doi: 10.3390/ijms21249656, PMID 33352826.
- Alves R, Grimalt R. A review of platelet-rich plasma: history, biology, mechanism of action, and classification. *Skin Appendage Disord.* 2018;4(1):18-24. doi: 10.1159/000477353, PMID 29457008.
- Andia I, Perez Valle A, Del Amo C, Maffulli N. Freeze-drying of platelet-rich plasma: the quest for standardization. *Int J Mol Sci.* 2020;21(18):1-18. doi: 10.3390/ijms21186904, PMID 32962283.
- Price Evans A. Introducing volume 14 of regenerative medicine. *Regen Med.* 2019;14(1):1-5. doi: 10.2217/rme-2018-0167, PMID 30570390.
- Shiga Y, Kubota G, Orita S, Inage K, Kamoda H, Yamashita M. Freeze-dried human platelet-rich plasma retains activation and growth factor expression after an eight-week preservation period. *Asian Spine J.* 2017;11(3):329-36. doi: 10.4184/asj.2017.11.3.329, PMID 28670400.
- Oentaryo G, Istiati I, Soesilawati P. Acceleration of fibroblast number and FGF-2 expression using channa striata extract induction during wound healing process: *in vivo* studies in wistar rats. *Dent J (Majalah Kedokteran Gigi).* 2016;49(3):125-32. doi: 10.20473/j.djmk.v49.i3.p125-32.
- Chicharro Alcantara D, Rubio Zaragoza M, Damia Gimenez E, Carrillo Poveda JM, Cuervo Serrato B, Pelaez Gorrea P. Platelet-rich plasma: new insights for cutaneous wound healing management. *J Funct Biomater.* 2018;9(1):1-20. doi: 10.3390/jfb9010010, PMID 29346333.
- Yun YR, Won JE, Jeon E, Lee S, Kang W, Jo H. Fibroblast growth factors: biology, function, and application for tissue regeneration. *J Tissue Eng.* 2010;2010:218142. doi: 10.4061/2010/218142, PMID 21350642.
- Shetty A, Bhandary R, Thomas B. Highlights on role of antibiotics in periodontics. *Int J Dentistry Res.* 2016;1(1):24-7. doi: 10.31254/dentistry.2016.1105.
- Susanto C, Ervina I, Agusnar H. *In vitro* evaluation of antimicrobial effectiveness chitosan-based tetracycline gel on some pathogenic periodontal bacteria. *Int J Appl Dent Sci.* 2017;3(2):71-6.
- Andrew A, Ervina I, Agusnar H. *In vitro* chitosan hydrogel-based tetracycline cytotoxicity test on fibroblast viability. *Adv Health Sci Res.* 2018;4:266-72. doi: 10.2991/idsm-17.2018.36.
- Oz HS, Puleo DA. Animal models for periodontal disease. *J Biomed Biotechnol.* 2011;2011:754857. doi: 10.1155/2011/754857, PMID 21331345.
- Guvva S, Patil MB, Mehta DS. Rat as laboratory animal model in periodontology. *Int J Oral Health Sci.* 2017;7(2):68-75. doi: 10.4103/ijohs.ijohs\_47\_17.
- Struillou X, Boutigny H, Soueidan A, Layrolle P. Experimental animal models in periodontology: a review. *Open Dent J.* 2010;4:37-47. doi: 10.2174/1874210601004010037, PMID 20556202.
- Ionel A, Lucaci O, Moga M, Buhatel D, Ilea A, Tabaran F. Periodontal disease induced in wistar rats—experimental study. *HVM Bioflux.* 2015;7(2):90-5.
- Maryani I, Rochmah YS, Parmana AD. Analisa gel kombinasi platelet rich plasma dan chitosan terhadap peningkatan jumlah osteoblas sebagai bone regeneration pada luka pasca ekstraksi gigi tikus wistar. *ODONTO: Dental Journal.* 2018;5(2):89-96. doi: 10.30659/odj.5.2.89-96.
- Yang LC, Hu SW, Yan M, Yang JJ, Tsou SH, Lin YY. Antimicrobial activity of platelet-rich plasma and other plasma preparations against periodontal pathogens. *J Periodontol.* 2015;86(2):310-8. doi: 10.1902/jop.2014.140373, PMID 25345340.
- Kinane DF, Stathopoulou PG, Papapanou PN. Periodontal diseases. *Nat Rev Dis Primers.* 2017;3:17038. doi: 10.1038/nrdp.2017.38, PMID 28805207.
- Veith AP, Henderson K, Spencer A, Sligar AD, Baker AB. Therapeutic strategies for enhancing angiogenesis in wound healing. *Adv Drug Deliv Rev.* 2019 Jun;146:97-125. doi: 10.1016/j.addr.2018.09.010, PMID 30267742.
- Ding ZY, Tan Y, Peng Q, Zuo J, Li N. Novel applications of platelet concentrates in tissue regeneration (review). *Exp Ther Med.* 2021;21(3):226. doi: 10.3892/etm.2021.9657, PMID 33603835.
- Ervina I, Wilson AWD, Amalia M, Syahputra A, Nasution AH. The role of scaling-root planing with a subgingival application of tetracycline 0,7 % based chitosan hydrogel in periodontitis rats' model (Evaluation of clinical parameters and fibroblast cell counts on periodontal ligaments). *Nat Volatiles Essent Oils.* 2021;8(4):2315-24.
- Mohammadi R, Mehrtash M, Hassani N, Hassanpour A. Effect of platelet-rich plasma combined with chitosan biodegradable film on full-thickness wound healing in rat model. *Bull Emerg Trauma.* 2016;4(1):29-37. PMID 27162924.
- Dukka H, Saleh MH, Ravida A, Greenwell H, Wang HL. Is bleeding on probing a reliable clinical indicator of peri-implant diseases? *J Periodontol.* 2021;92(12):1669-74. doi: 10.1002/JPER.20-0890, PMID 33829501.
- Matesanz Perez P, Garcia Gargallo M, Figuero E, Bascones Martinez A, Sanz M, Herrera D. A systematic review on the effects of local antimicrobials as adjuncts to subgingival debridement, compared with subgingival debridement alone, in the treatment of chronic periodontitis. *J Clin Periodontol.* 2013;40(3):227-41. doi: 10.1111/jcpe.12026, PMID 23320860.
- Sutamaya AG, Hendiani I, Susanto A. Clinical evaluation of adjunctive topical therapy of tetracycline HCl 25 mg in the surgical periodontal flap. *PJoD.* 2016;28(2):121-5.
- Kida D, Zakrzewska A, Zborowski J, Szulc M, Karolewicz B. Polymer-based carriers in dental local healing-review and future challenges. *Materials (Basel).* 2021;14(14):3948. doi: 10.3390/ma14143948, PMID 34300865.
- He J, Da L, Pan Y, Tan X, Li Z, Luo F. Association between quantitative analyses of periodontal pathogens and the depth of periodontal pockets. *Biotechnol Biotechnol Equip.* 2020;34(1):515-21. doi: 10.1080/13102818.2020.1764387.
- Nayak S, Goel MM, Makker A, Bhatia V, Chandra S, Kumar S. Fibroblast growth factor (FGF-2) and its receptors FGFR-2 and

- FGFR-3 may be putative biomarkers of malignant transformation of potentially malignant oral lesions into oral squamous cell carcinoma. *Plos One*. 2015;10(10):e0138801. doi: 10.1371/journal.pone.0138801, PMID 26465941.
35. Maeda H, Tomokiyo A, Wada N, Koori K, Kawachi G, Akamine A. Regeneration of the periodontium for the preservation of the damaged tooth. *Histol Histopathol*. 2014;29(10):1249-62. doi: 10.14670/HH-29.1249, PMID 24777740.
36. Alvarez AL, Espinar FO, Mendez JB. The application of microencapsulation techniques in the treatment of endodontic and periodontal diseases. *Pharmaceutics*. 2011;3(3):538-71. doi: 10.3390/pharmaceutics3030538, PMID 24310596.
37. Kononen E, Gursoy M, Gursoy UK. Periodontitis: a multifaceted disease of tooth-supporting tissues. *J Clin Med*. 2019;8(8):1-12. doi: 10.3390/jcm8081135, PMID 31370168.
38. Garzon H, Suarez LJ, Munoz S, Cardona J, Fontalvo M, Alfonso Rodriguez CA. Biomaterials used for periodontal disease treatment: focusing on immunomodulatory properties. *Int J Biomater*. 2022;2022:7693793. doi: 10.1155/2022/7693793, PMID 35528847.
39. Fraser D, Caton J, Benoit DS. Periodontal wound healing and regeneration: insights for engineering new therapeutic approaches. *Front Dent Med*. 2022;3:1-24. doi: 10.3389/fdmed.2022.815810.
40. Smith PC, Martínez C, Martínez J, McCulloch CA. Role of fibroblast populations in periodontal wound healing and tissue remodeling. *Front Physiol*. 2019;10(270):270. doi: 10.3389/fphys.2019.00270, PMID 31068825.
41. Nagayasu Tanaka T, Anzai J, Takaki S, Shiraishi N, Terashima A, Asano T. Action mechanism of fibroblast growth factor-2 (FGF-2) in the promotion of periodontal regeneration in beagle dogs. *Plos One*. 2015;10(6):1-19. doi: 10.1371/journal.pone.0131870.
42. Zhang Y, Wang ZL, Deng ZP, Wang ZL, Song F, Zhu LL. Emerging delivery strategies of platelet-rich plasma with hydrogels for wound healing. *Adv Polym Technol*. 2022;2022:1-11. doi: 10.1155/2022/5446291.