

FIBROBLAST ACTIVITY AFTER APPLICATION OF 3% BINAHONG LEAVES EXTRACT GEL IN POST-EXTRACTION SOCKETS OF WISTAR RATS (*RATTUS NOVERGICUS*)

OLIVIA AVRIYANTI HANAFIAH^{1*}, DENNY SATRIA², POPPY NOVIA INDRIANI³, AFIFAH AYUNI HG⁴, RAHMAH³,
RIANDA LUBIS³

¹Department of Oral and Maxillofacial Surgery, Faculty of Dentistry, Medan, University of North Sumatera, Indonesia. ²Department of Pharmaceutical Biology, Faculty of Pharmacy, Medan, University of North Sumatera, Indonesia. ³Faculty of Dentistry, Medan, University of North Sumatera, Indonesia. ⁴Master's Program in Dental Science, Faculty of Dentistry, Medan, and University of North Sumatera, Indonesia

*Corresponding author: Olivia Avriyanti Hanafiah; *Email: olivia.hanafiah@usu.ac.id

Received: 27 Apr 2024, Revised and Accepted: 15 Jul 2024

ABSTRACT

Objective: To observe the effect of 3% binahong leaves extract gel on wound healing of socket post tooth extraction.

Methods: Twenty-four wistar strain white rats (*Rattus novergicus*) were used in this experimental laboratory work, and the 3% extract gel of binahong plants was created from scratch in the Pharmacognition Laboratory. A 3% gel made from the extract of binahong leaves was made in the Pharmacognition Laboratory of the Faculty of Pharmacy, Universitas Sumatera Utara, Medan. The gel was applied twice a day, in the morning and the evening, to the socket wounds using a bent needle irrigation tip. Each rat were subjected to dental extraction of the mandibular left incisor and divided into three different groups; the negative control group, positive control group, and the treatment group with each of the socket group observed every three and seven days and the cells were colored using Hematoxilin-Eosin method. Following data collection, the SPSS Statistics program was used to analyze the data.

Results: Clinically, socket wounds were visibly smaller, whereas microscopically, the distance of the wound edges greatly reduced in both groups. Histologically fibroblast proliferation increased after application of binahong extract, but there was no significant difference on the 3rd and 7th d after extraction.

Conclusion: Application of *binahong* leaf extract gel in the socket following tooth extraction, the binahong 3% extract gel contributes to the acceleration of fibroblast proliferation.

Keywords: Binahong leaves extract, Fibroblast, Socket wound healing

© 2024 The Authors. Published by Innovare Academic Sciences Pvt Ltd. This is an open access article under the CC BY license (<https://creativecommons.org/licenses/by/4.0/>) DOI: <https://dx.doi.org/10.22159/ijap.2024.v16s4.09> Journal homepage: <https://innovareacademics.in/journals/index.php/ijap>

INTRODUCTION

Tooth extractions result in damage to both soft and hard structures, which can cause discomfort, edema, and bleeding [1, 2]. Teeth extractions are medical procedures used to remove teeth from the alveolar process. When the pressure inside blood vessels is higher than the pressure outside, bleeding happens [1]. The most successful tooth extractions are those that leave the wound completely healed and involve the least amount of damage or discomfort [3]. Wound healing is an innate physiological response to injury, even though complex biological factors play a part. The phases of bone formation, tissue remodeling, hemostasis, inflammation, and proliferation are all part of the healing process for post-extraction wounds, which follows the same principles as other tissue wounds [4-6].

Medication can hasten the healing of wounds left behind after extraction and lower the risk of problems. Oral surgeons typically prescribe non-steroidal anti-inflammatory drugs (NSAIDs) to relieve inflammation and postoperative discomfort; nevertheless, NSAID use has a number of side effects, including gastrointestinal and haematological issues, renal changes, and mucosal and skin sensitivities. Herbal compounds are beginning to replace pharmaceutical medications because of their low side effects [7, 8].

Anredera cordifolia, sometimes referred to as "binahong" in Chinese medicine, possesses antibacterial, anti-inflammatory, and antioxidant qualities that make it useful in treating a variety of diseases [9, 10]. Binahong has velvety, cylindrical stems that grow creepingly to a maximum length of five meters. The leaves are heart-shaped and solitary, with short stalks that are arranged sporadically. The length of the leaves is 5-10 cm, and their breadth is 3-7 cm. As a member of the Basellaceae family, the binahong plant (*Anredera cordifolia*) is a medicinal plant with tremendous promise for further

study because there is still much about it that has to be discovered as a phytopharmaceutical ingredient [11]. One part of this plant that can be utilized is the leaves. This is because the secondary metabolites in binahong leaves contain proteins, alkaloids, polyphenols, triterpenoids, flavonoids, essential oils, and saponins in addition to ascorbic acid [8, 9].

Binahong leaves contain three main types of secondary metabolites: flavonoids, tannins, and saponins. Apart from its antimicrobial characteristics, saponin accelerates the proliferation of fibroblasts [13]. Tannins are antioxidants that aid in the healing of socket wound [14]. Flavonoids have anti-inflammatory qualities because they stop arachidonic acid and other inflammatory mediators from being converted into prostaglandins [2]. Together with other substances referred to as ursolic acid, quercetin and kaempferol, two flavonoid components that are members of the triterpenoid group, possess antibacterial qualities that facilitate the quicker healing of socket wounds [15].

The authors are intrigued by these descriptions and are considering conducting research on the impact of 3% binahong leaf extract gel on socket wounds, both clinically and microscopically.

MATERIALS AND METHODS

Ethical considerations

All experimental procedures in this study were conducted following the guidelines of the Institutional Animal Care and Use Committee (ARRIVE) 2.0. Ethical clearance has been approved by the Research Ethics Committee of the Department of Biology, Faculty of Mathematics and Natural Sciences, Universitas Sumatera Utara, Medan, North Sumatera, Indonesia, with reference number: 0189/KEPH-FMIPA/2019.

Animals

Sample size

The sample size in this study was calculated based on previous research of a similar nature. The minimum sample size obtained from the calculations was three animals and the final sample size was adjusted to four animals per group (with a total of 6 groups) or 24 animals in total. There was a 10% addition from the minimum sample size to anticipate sample exclusion during the experiment.

Rats

Eligible subjects had to meet specific inclusion criteria: male wistar rats, approximately three months old, weighing between 200 and 250 gs, in good health, exhibiting active movement, having intact fur, and no injuries to the body or oral cavity. Exclusion criteria included the presence of systemic diseases or abnormalities, as well as prior participation in research studies. Before administering the treatment, the rats were acclimatized for seven days to assure that the rats could adapt to their surroundings and were allowed ad libitum feeding and drinking.

Tooth extraction

Experimental animals that fulfilled the sample criteria underwent a one-week acclimatization period before being administered general anesthesia via intraperitoneal injection of 25 mg/kg BW ketamine hydrochloride and 10 mg/kg BW xylazine chloride. The mandibular left incisor tooth was then extracted using an artery clamp, and the area was then irrigated with aquadest to remove remaining debris in the socket. The extraction was performed by the same veterinarian who was blinded to the group allocation.

Preparation of binahong 3% extract gel

The Binahong leaf extract used in this study was obtained from the Pharmacognosy Laboratory of the Faculty of Pharmacy at Universitas Sumatera Utara in Medan, North Sumatra, Indonesia. A total of 400 gs of fully opened Binahong leaves, aged about 12 w, were selected and collected from Simpang Perdagangan village in the Tigabinanga district of Karo regency, North Sumatra, Indonesia, in April 2017. The extraction of Binahong leaves was performed using the maceration method with 80% ethanol (Smart Lab Indonesia) as the solvent. After this period, the ethanol solvent was replaced with fresh solvent, and the leaves were soaked for an additional two days. The final step involved filtering the mixture and using a water bath to evaporate the solvent until the extract was dried. A 3% gel made from the extract of binahong leaves was made in the Pharmacognosy Laboratory of the Faculty of Pharmacy, Universitas Sumatera Utara, Medan. The ingredients included carbopol material, TEA (triethanolamine), HPMC (hydroxypropyl methylcellulose), glycerin, nipagin (methylparaben) and nipasol (propylparaben), extract of binahong leaves, and aquadest. In order to create the basic gel, 10 ml of hot distilled water, 0.125 g of carbopol (Merck, Germany), and a pestle were used to combine the ingredients. After that, 2 g of glycerin (Merck, Germany) and 1.5 g of triethanolamine (TEA) (Merck, Germany) were added, and the mixture was agitated until it was homogenous. 10 ml of distilled water, 0.125 g of hydroxypropyl methylcellulose (HPMC) (Merck, Germany), nipagin 30 (Merck, Germany), and nipasol (Merck, Germany) were combined and mixed until a homogenous mixture was achieved in a second mortar. After adding the second mortar mixture to the first mortar and stirring it until it became uniform, the mixture was sealed. 0.6 g of Binahong leaf extract was added to the basic gel and mixed until the mixture was homogeneous to create 20 g of 3% Binahong leaf extract gel. To maintain its freshness, the gel was replicated every three to four days [16].

Application of gels

Twenty-four rats under normal socket conditions it was divided into six groups, each group consisted of four white rats. Group A was a group of rats that were not treated initially and excised on the third day. Group B was a group of rats that were given basic gel and excised on the third day. Group C was a group of rats that were given 3% binahong leaves extract gel and was excised on the third day. Group D was a group of rats that were not given

treated initially and excised on the seventh day. Group E was a group of rats that were given basic gel and excised on the seventh day. Group F was group of rats that were given 3% binahong leaves extract gel and excised on the seventh day. After that, applications were made twice a day in the morning at 8.00 a. m.-10.00 a. m. and in the afternoon at 4.00 p. m.-6.00 p. m to the socket wounds using a bent needle irrigation tip (Ivoclar Vivadent, Ø: 1,2 mm, Liechtenstein) until the gel-covered the entire wound surface to make sure that the gel would be directly in contact with the wound [14].

Clinical measurement of wound closure

After a tooth is extracted, the socket wound shrinks in size as a result of the soft tissue healing process. This may be seen physically, and the breadth of the socket wound can be measured beginning on the day it occurred. Caliper measurements taken to determine the socket wound closure's size [6].

Histopathological analysis

After reaching the 3rd day (group A,B,C), and the 7th d (group D,E,F) post-extraction, the rats from the respective groups were sacrificed by cervical dislocation. It refers to a technique used in physical euthanasia of small animals by applying pressure to the neck and dislocating the spinal column from the skull or brain [20]. The mandible of the rats was separated from the skull, and the socket wound tissue was excised. The fresh tissue was then fixed in a 10% Buffered Neutral Formalin (BNF) solution (Milestone Medical, Italy) with a pH of 6.8-7.0, using a tissue-to-BNF solution ratio of 1:10. After that, the rat's jaw tissue was sliced to a thickness of around 4 mm in order to dehydrate it. Subsequently, a vacuum machine was used to extract the air from the tissue. The tissue was printed, filled with paraffin, and then frozen as part of the following procedure termed embedding [17]. The tissue slices were then mounted on clean glass slides, labeled, and placed in an incubator at 37 °C to dry overnight. The slides were stained with haematoxylin-eosin (Merck, Germany) to visualize fibroblasts under a microscope. The stained tissue slides were examined under an electric microscope (Primo Star, Carl Zeiss, Germany) at 400x magnification across 10 viewing fields. Fibroblasts, identified under the microscope, appear spindle-shaped with an ovoid nucleus and are typically found in connective tissue.

Statistical analysis

Using the Armonk, New York-based SPSS Statistics version 20 application, clinical and microscopical wound closure data processing was carried out by using the one-way analysis of variance (ANOVA) test and Least Significant Difference (LSD) test because the data was normally distributed, and Pearson test to see the correlation between clinical wound closure and fibroblast proliferation.

RESULTS AND DISCUSSION

Clinical imaging: groups A, B, C, D, E F

On the third day, clinical differences were seen across groups A, B, and C. In contrast to groups A and B, which seemed to still be wet and crimson, group C's wounds were smaller, drier, and the same color as the surrounding tissues. It was demonstrated by the clinical evaluation of the post-extraction socket that there were no signs of irritation or inflammation following the use of 3% gel-containing binahong leaf extract. Fig. 1 and fig. 2 illustrates that the postextraction socket clinical circumstances in the binahong group were superior to those in the control group with regard to hemorrhage and surrounding tissue color and consistency.

Clinical healing of typical socket wounds revealed a difference between wounds in groups D, E, and F on the seventh day. Groups D and E seemed to have dry surfaces but were still reddish, whereas group F seemed to be smaller and drier.

Table 1 shows clinical wound closure data on day 3, normality and homogeneity tests show that the data was normally distributed and homogeneous, hence one-way ANOVA and posthoc LSD tests were used.

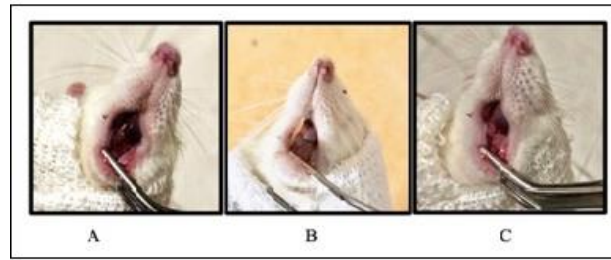


Fig. 1: The clinically wound closure on the third day

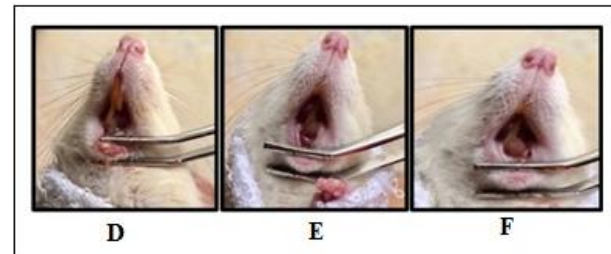

Fig. 2: The clinically wound closure on the seventh day

Table 1: Clinical wound closure

Day	Group	Mean±SD	P-value	Control	Basic gel	Binahong
3	Control (A)	2.03±0.16	0.553 ^a	0.665 ^b	p=0.665 ^b	p=0.519 ^b
3	Basic gel (B)	2.09±0.24				
3	Binahong (C)	1.94±0.06				
7	Control (D)	1.06±0.014	0.000* ^a	1.000 ^b	p=1.000 ^b	p=0.000* ^b
7	Basic gel (E)	1.06±0.06				
7	Binahong (F)	0.28±0.005				

*aOneway ANOVA test: p<0,05 Significant, ^bPost Hoc LSD test, p<0,05 Significant

According to table 1, group C had the best average clinical wound closure results on the third day, measuring 1.94±0.06 mm, followed by group A at 2.03±0.16 mm and group B at 2.09±0.24 mm. According to the findings, the third-day clinical wound healing acceleration is impacted by the 3% binahong leaf extract gel. On the seventh day, group F had the best clinical wound closure results, measuring 0.28±0.005 mm, group E had 1.06±0.06 mm, and group D had 1.06±0.014 mm.

The results showed that there was a significant difference in the mean clinical wound socket closure between the control and binahong groups on the 7th d after extraction, while the binahong group showed lower mean values than the control group. This

shows that the wound healing process in the binahong group was better than the control group, which was indicated by the size of the clinical wound shrinking faster. As well as its anti-inflammatory effect, binahong leaf gel can also increase the expression of various growth factors involved in wound healing, increase the proliferation and migration of fibroblasts and have an antibacterial effect. This indicates that the clinical wound healing was accelerated by the 3% binahong leaf extract gel.

Table 2 shows the average fibroblast proliferation data on the third and seventh days. The data was normally distributed and homogeneous, hence the oneway ANOVA and posthoc LSD tests were used in all groups.

Table 2: Microscopic wound closure

Day	Group	Mean±SD	P-value	Control	Basic gel	Binahong
3	Control (A)	173.28±47.50	0.137 ^a	0.473 ^b	p=0.473 ^b	p=0.056 ^b
3	Basic gel (B)	192.35±16.75				
3	Binahong (C)	229.75±20.81				
7	Control (D)	190.48±34.36	0.036* ^a	0.944 ^b	p=0.944 ^b	p=0.022 ^b
7	Basic gel (E)	194.00±31.19				
7	Binahong (F)	325.06±92.52				

*aOneway ANOVA test: p<0,05 Significant; ^bPost Hoc LSD test: p<0,05 Significant

The results showed that there was no significant difference in both the mean of clinical wound closure (table 1) and fibroblast proliferation (table 2) datas between the control and binahong groups on the 3rd d after extraction, even though the binahong group showed higher mean fibroblast proliferation than the control group. The bivariate test is not always significant, even though the mean is

different. The result is not significant if the mean is too close, indicating that while the overall effect is the same, the mean results outcomes vary.

The third-day average of the fibroblast proliferation data showed that group C had the highest average at 229.75±20.81 pixels, followed by group B at 192.35±16.75 pixels and group A at

173.28±47.50 pixels. The seventh-day average of the fibroblast proliferation showed that group F had the highest average at 325.06±92.52 pixels, followed by group E at 194.00±31.19 pixels and group D at 190.48±34.36 pixels. This indicates that the largest increase in fibroblast proliferation on the seventh day was microscopically influenced by the 3% binahong leaves extract gel. The fibroblast proliferation increases from 3rd to 7th d. One of the constituents found in binahong leaf extract, saponins, has the ability to influence TGF-β1 production and activation as well as alter TGF-β1 and TGF-β2 receptors on fibroblasts. This is a crucial

step in the remodeling phase for the synthesis of matrix collagen. By controlling VEGF, saponins, as angiogenic drugs, can enhance endothelial cells' mitogenic activity during the proliferative phase of blood vessel creation. For this reason, binahong is thought to have the ability to hasten the healing of wounds [18].

Table 3, 4, and 5 show the correlation between clinical wound closure and fibroblast proliferation data on the third day, seventh day, and in total. The data was analysed using pearson correlation test.

Table 3: Correlation test between clinical wound closure and fibroblast proliferation on third day

Group	Pearson correlation	P-value
Clinical wound closure	-0.726	0.008
Fibroblast proliferation		

*Pearson Correlation Test; Correlation is significant at the 0.01 level (2-tailed), Pearson correlation score: 0.00 until 0.20 = no correlation, 0.21 until 0.40 = weak correlation, 0.41 until 0.60 = moderate correlation, 0.61 until 0.80 = strong correlation, 0.81 until 1.00 = perfect correlation

Table 4: Correlation test between clinical wound closure and fibroblast proliferation on seventh day

Group	Pearson correlation	P-value
Clinical wound closure	-0.796	0.002
Fibroblast proliferation		

*Pearson Correlation Test; Correlation is significant at the 0.01 level (2-tailed), Pearson correlation score: 0.00 s/d 0.20 = no correlation, 0.21 s/d 0.40 = weak correlation, 0.41 s/d 0.60 = moderate correlation, 0.61 s/d 0.80 = strong correlation, 0.81 s/d 1.00 = perfect correlation

Table 5: Correlation test between clinical wound closure and fibroblast proliferation in total

Group	Pearson correlation	P-value
Clinical wound closure in total	-0.575	0.003
Fibroblast proliferation in total		

*Pearson Correlation Test; Correlation is significant at the 0.01 level (2-tailed), Pearson correlation score: 0.00 s/d 0.20 = no correlation, 0.21 s/d 0.40 = weak correlation, 0.41 s/d 0.60 = moderate correlation, 0.61 s/d 0.80 = strong correlation, 0.81 s/d 1.00 = perfect correlation

Based on the correlation test, it is known that the wound closure on day 3 is related to fibroblast proliferation ($p=0.008$) with a strong degree of correlation and a negative relationship; the wound closure on day 7 is related to fibroblast proliferation ($p=0.002$) with a strong degree of correlation and a negative

relationship; while the wound closure in total is related to fibroblast proliferation ($p=0.003$) with a moderate degree of correlation and a negative relationship, it all means that the lower the wound diameter, the higher the fibroblasts proliferation, and vice versa.

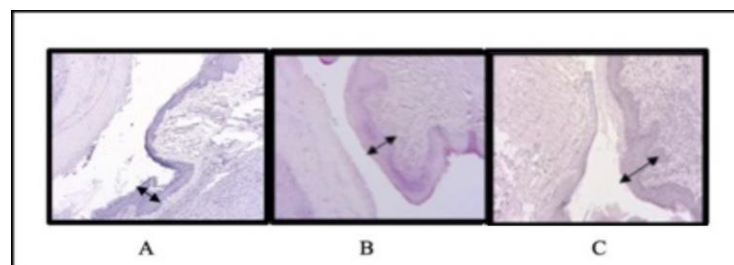


Fig. 3: Microscopically wound closure on third day

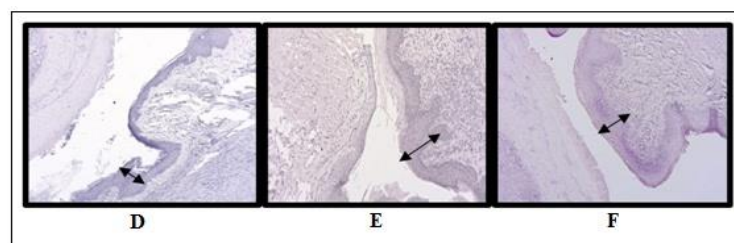


Fig. 4: Microscopically wound closure on seventh day

Herbal medicine has become more popular as an alternative since it has fewer negative effects. The optimal concentration of binahong gel, according to Hanafiah OA research, is 3% because it efficiently encourages wound closure and the growth of new fibroblasts [22].

Fibroblasts are one type of stromal cell that is present in connective tissue. An oval or rounded nucleus resembling a star can be seen in active fibroblast imaging. Inactive fibroblasts also have morphological changes and are elongated cells with small, flat, or wavy nuclei surrounding collagen fibers [24, 25].

On the third and seventh days, groups A, B, C, D, E, and F were observed. The rat's jaw structure made extraction difficult, which resulted in damage that released tissue activator, which in turn released kininogenase and bradykinin enzymes, all of which are involved in the production of pain [6, 9]. White rats are used in this study because they are less expensive, more readily available, and more active than any other strain. There was a significant result for the fibroblast distance variable between A, B, and C, as well as the clinical wound closure variable. The socket wound test in A was not any different from that in B. This was due to the absence of secondary metabolite chemicals in group B, which have the ability to mend wounds. The ingredients of basic gel are carbopol, TEA (triethanolamine), HPMC (hydroxypropyl methylcellulose), glycerin as a sweetener, nipagin (methylparaben) and nipasol (propylparaben) as preservatives, and aquadest. In order to obtain a stable and standardized gel, the gel content passed the tests for viscosity, pH, organoleptic, and specific gravity [23, 24]. This may happen as a result of the extract of binahong leaves' secondary metabolites, which include tannins, flavonoids, and saponins [11].

As active agents that increase membrane permeability, saponins bind lipids to bacterial cells and cause the loss of essential components needed by bacteria, which ultimately results in bacterial cell death [25]. Saponins are one type of antibacterial compounds. Additionally, saponins can increase monocyte proliferation, which increases the number of macrophages [12].

Flavonoids act as anti-inflammatory medications by stopping arachidonic acid and other inflammatory mediators from converting to prostaglandins. The flavonoid component that matters most in this case is quercetin [26]. Monocytes settle in after neutrophils move during the inflammatory phase and arrive at the injured area. When monocytes proliferate, more macrophages are produced. These macrophages emit growth factors that can attract fibroblasts to the wound site, produce collagen, and encourage the formation of capillary arteries, so extending the distance between fibroblasts [27].

The flavonoids and saponins included in binahong leaf extract function as building blocks for inflammatory mediators. Inflammatory mediators have chemotactic properties that draw white blood cells to the site of the wound. In addition to phagocytosing bacteria and damaged tissue, cells like macrophages are involved in the production of growth factors that prompt keratinocytes to begin the process of re-epithelialization. Because epithelial cells differentiate and stratify, it was observed in the designated group in this investigation. When compared to the group that did not receive binahong leaf extract, the space between the wound edges shrank, indicating a better wound healing process with binahong leaf extract [28, 29].

Additionally, flavonoids possess antibacterial qualities. In addition to their antioxidant properties, tannins have the ability to produce hydrogen, serve as reductor, and absorb oxygen, all of which help speed up the healing of wounds-even those that are infected [30]. Tannins facilitate faster bleeding cessation via a number of biological mechanisms. Additionally, they facilitate wound healing by increasing the formation of blood capillaries and fibroblasts, which speeds up the closure of wounds. This suggests that by accelerating fibroblast multiplication, the tannins in binahong leaves also aid in the clinical wound healing process [1, 13].

CONCLUSION

Application of binahong 3% extract gel on socket wound decreases value of the socket wound closure and the increases fibroblast proliferation. These are signs that the fibroblast proliferation after

tooth extraction is being accelerated by the binahong 3% extract gel and the healing of socket wound post tooth extraction is better compared to control group.

ACKNOWLEDGEMENT

The author expresses gratitude to all those who contributed to this study, including Pharmacy Laboratory of the Faculty of Pharmacy, University of North Sumatera, the Biology Laboratory of the Faculty of Mathematics and Natural Sciences, University of North Sumatera, the Pharmacology and Herbal Laboratory, and the Pathology Laboratory of the Medan Veterinary Center, and everyone else.

FUNDING

Nil

AUTHORS CONTRIBUTIONS

Conceptualization: OAH, DS, PNI; table Work: OAH, DS, PNI; Supervision: OAH, DS; Revisions: OAH, DS, AAH, R, RL; Writing and Editing: OAH, DS, AAH, R; Proofreading: OAH, DS.

CONFLICT OF INTERESTS

Declared none

REFERENCES

1. Haris BM, Hasan H. Effectiveness of binahong leaves extract, soursop leaves extract and combination of binahong leaves and soursop leaves extract on hemostasis in cuts of mice. *J Dentomaxillofac Sci.* 2017;2(3):176-8. doi: [10.15562/jdmfs.v2i3.655](https://doi.org/10.15562/jdmfs.v2i3.655).
2. Ruellas A, Romano F, Pithon M. Tooth extraction in orthodontics: an evaluation of diagnostic elements. *Dent Press J Orthod.* 2010;15(3):135.
3. Guo S, DiPietro LA. Factors affecting wound healing. *J Dent Res.* 2010;89(3):219-29. doi: [10.1177/0022034509359125](https://doi.org/10.1177/0022034509359125), PMID 20139336.
4. Larjava H. Oral wound healing: cell biology and clinical management. 1st ed John Wiley and Sons: Inc; 2012. p. 1-4.
5. Velnar T, Bailey T, Smrkolj V. The wound healing process: an overview of the cellular and molecular mechanisms. *J Int Med Res.* 2009;37(5):1528-42. doi: [10.1177/147323000903700531](https://doi.org/10.1177/147323000903700531), PMID 19930861.
6. Preetha S. An overview of wound socket and its management. *J Dent Med Sci.* 2014;13(5):32-5.
7. Herrera Briones FJ, Prados Sanchez E, Reyes Botella C, Vallecillo Capilla M. Update on the use of corticosteroids in third molar surgery: systematic review of the literature. *Oral Surg Oral Med Oral Pathol Oral Radiol.* 2013;116(5):e342-51. doi: [10.1016/j.oooo.2012.02.027](https://doi.org/10.1016/j.oooo.2012.02.027), PMID 22902498.
8. Hernandez Viana S, Silva Gomez N, Galvis Pareja DA, Martinez Pabon MC. The use of analgesics and antiinflammatories in an oral surgery service in Medellín, Colombia, 2013-2015. *Rev Fac Odontol.* 2019;30(2):154-68.
9. Manoi F. Binahong (*Anredera cordifolia*) as medicine. *Warta magazine vol. 15, agricultural Research and Development Agency.* Vol. 22; 2009.
10. Smith GV, Lawson BE, Turnbull I, Downey PO. The biology of Australian weeds 46. *Anredera cordifolia* (Ten.) steenis. *Plant Prot Q.* 2007;22(1):2-10.
11. Haris BM, Hasan H. Effectiveness of binahong leaves extract, soursop leaves extract and combination of binahong leaves and soursop leaves extract on hemostasis in cuts of rats. *J Dentomaxillofac Sci.* 2007;2(3):176-9.
12. Wijayanti K, Esti RH. Effectiveness of binahong decoction water (*Anredera cordifolia* (ten) steenis) for perineal wound healing at home delivery aesyra grabag Magelang, Indonesia. *Int J Res Med Sci.* 2017;5(5):1973. doi: [10.18203/2320-6012.ijrms20171827](https://doi.org/10.18203/2320-6012.ijrms20171827).
13. Yuslianti ER, Sabirin IP, B Sutjiat A. Effectiveness of noni (*Morinda citrifolia* L.) leaves extract gel as standardized traditional medicine to accelerate oral mucosa wound healing on wistar rats. *Res J Med Plants.* 2014;8(4):156-66. doi: [10.3923/rjmp.2014.156.166](https://doi.org/10.3923/rjmp.2014.156.166).
14. Hanafiah OA, Trimurni A, Ilyas S. Formulation and evaluation of binahong leaves extract gel on wound healing of the palatal mucosa. *J Biomimetics Biomater Biomed Eng.* 2020;48:85-91.

15. Chan JK. The wonderful colors of the hematoxylin-eosin stain in diagnostic surgical pathology. *Int J Surg Pathol.* 2014;22(1):12-32. doi: [10.1177/1066896913517939](https://doi.org/10.1177/1066896913517939), PMID 24406626.
16. Kumar S, Pandey AK. Chemistry and biological activities of flavonoids: an overview. *Scientific World Journal.* 2013;2013:162750. doi: [10.1155/2013/162750](https://doi.org/10.1155/2013/162750), PMID 24470791.
17. AVMA Panel on Euthanasia. American Veterinary Medical Association. 2000 report of the AVMA panel on euthanasia. *J Am Vet Med Assoc.* 2001;218(5):669-96. doi: [10.2460/javma.2001.218.669](https://doi.org/10.2460/javma.2001.218.669), PMID 11280396.
18. Gurcharan Singh GK, Utami NV, Usman HA. Effect of topical application of binahong [*Anredera cordifolia* (Ten.) steenis] leaf paste in wound healing process in mice. *Althea Med J.* 2014;1(1):6-11. doi: [10.15850/amj.v1n1.289](https://doi.org/10.15850/amj.v1n1.289).
19. Enny TS. Euthanasia: an ethical review in animals. Grad Sch IPB, Bogor. 2004.
20. Rodrigues MT, Cardoso CL, Carvalho PS, Cestari TM, Feres M, Garlet GP. Experimental alveolitis in rats: microbiological, acute phase response and histometric characterization of delayed alveolar healing. *J Appl Oral Sci.* 2011;19(3):260-8. doi: [10.1590/s1678-77572011000300015](https://doi.org/10.1590/s1678-77572011000300015), PMID 21625744.
21. Hanafiah OA, Hanafiah DS, Bayu ES, Ilyas S, Nainggolan M, Syamsudin E. Quantity differences of secondary metabolites (saponins, tannins, and flavonoids) from binahong plant extract (*Anredera cordifolia* (Ten.) Steenis) treated and untreated with colchicines that play a role in wound healing. *World J Dent.* 2017;8(4):296-9. doi: [10.5005/jp-journals-10015-1453](https://doi.org/10.5005/jp-journals-10015-1453).
22. Cardiff RD, Miller CH, Munn RJ. Manual hematoxylin and eosin staining of mouse tissue sections. *Cold Spring Harb Protoc.* 2014;6:655-8.
23. Ravikanth M, Soujanya P, Manjunath K, Saraswathi TR, Ramachandran CR. Heterogeneity of fibroblasts. *J Oral Maxillofac Pathol.* 2011;15(2):247-50. doi: [10.4103/0973-029X.84516](https://doi.org/10.4103/0973-029X.84516), PMID 22529592.
24. V Sandhu SV, Gupta S, Bansal H, Singla K. Collagen in health and disease. *J Orofac Res.* 2012;2(3):153-9. doi: [10.5005/jp-journals-10026-1032](https://doi.org/10.5005/jp-journals-10026-1032).
25. Norton JA, Barie PS, Bollinger R. Surgery: basic science and clinical evidence. 2nd ed. New York: Springer Science and Business Media; 2008. p. 191-7.
26. Yuliani SH, Fudholi A, Pramono S, Marchaban. The effect of formula to physical properties of wound healing gel of ethanolix extract of binahong (*Anredera cordifolia* (Ten.) Steenis). *Int J Pharm Sci Res.* 2012;3(11):4254-9. doi: [10.13040/IJPSR.0975-8232.3\(11\).4254-9](https://doi.org/10.13040/IJPSR.0975-8232.3(11).4254-9)
27. Kolokythas A, Olech E, Miloro M. Alveolar osteitis: a comprehensive review of concepts and controversies. *Int J Dent.* 2010;2010:249073. doi: [10.1155/2010/249073](https://doi.org/10.1155/2010/249073), PMID 20652078.
28. Kurniawan B, Carolia N, Pheilia A. The effectiveness of binahong leaf extract (*Anredera cordifolia* (Ten.) Steenis) and mefenamic acid as anti inflammation to white male rat induced by karagenin. *Juke Unila.* 2014;4(8):151-7.
29. Hanafiah OA, Abidin T, Ilyas S, Nainggolan M, Syamsudin E. Wound healing activity of binahong (*Anredera cordifolia* (Ten.) Steenis) leaves extract towards NIH-3T3 fibroblast cells. *J Int Dent Med Res.* 2019;12(3):854-8.
30. Savoia D. Plant-derived antimicrobial compounds: alternatives to antibiotics. *Future Microbiol.* 2012;7(8):979-90. doi: [10.2217/fmb.12.68](https://doi.org/10.2217/fmb.12.68), PMID 22913356.