

ANTHROPOMETRIC STUDY OF LEFT EXTERNAL EAR: A CROSS-SECTIONAL STUDY IN MEDICAL STUDENTS OF UDAIPUR, RAJASTHAN

BHAVANA SHRIVASTAVA¹, SUNITA ACHARYA², VAISHALY KISHORE BHARAMBE³, BHUPESH MEDATWAL^{4*}

^{1,2,3}Department of Anatomy, Pacific Institute of Medical Sciences, Sai Tirupati University, Udaipur, Rajasthan, India, ⁴Department of Biochemistry, Pacific Medical College and Hospital, Udaipur, Rajasthan.

*Corresponding author: Bhupesh Medatwal; *Email: medatwalbhupesh@gmail.com

Received: 09 Apr 2024, Revised and Accepted: 01 Jun 2024

ABSTRACT

Objective: The human ears are specific to an individual because the auricle is also a distinctive feature of a person like other identification features so it is used in various areas of science like forensic medicine, anthropology, and biology. The ear lobule is the last part of the auricle to develop.

Methods: This study was carried out among 100 students (50 Male and 50 Female) with age range from 18 to 25 years. The study was conducted in the Department of Anatomy, Pacific Institute of Medical Sciences, Udaipur, Rajasthan, India.

Results: Total ear length and ear width were significantly higher in male than female (p value < 0.0001) in this study. Lobule length and lobule width of left ear were compared by independent t-test, it was found nonsignificant (p value 0.5706) and significantly higher in male than female (p 0.0017) respectively. The mean value of lobule index of left ear was found significant with higher value in male while the mean value of ear index of left ear was found nonsignificant.

Conclusion: Results according to genders who participated in the study where all dimensions (total ear length, ear width, lobule width and lobule index) were higher in male as compared to the female subjects. Although there was no significant difference observed in lobule length and ear index of left ear of male and female subjects.

Keywords: Auricle, Ear lobule, Ear index, lobule index, Vernier caliper, Anthropometry

© 2024 The Authors. Published by Innovare Academic Sciences Pvt Ltd. This is an open access article under the CC BY license (<https://creativecommons.org/licenses/by/4.0/>) DOI: <https://dx.doi.org/10.22159/ijcpr.2024v16i4.5052> Journal homepage: <https://innovareacademics.in/journals/index.php/ijcpr>

INTRODUCTION

The ear is an essential feature of the face, and any information regarding the age or the sex of the individual can be conveyed through it [1]. The morphometrical study of the auricle is used in various areas of science like forensic medicine, anthropology, and biology as it is a very distinct feature of the human body and might be helpful for identification purposes [2]. The Auricle in humans is a very unique and defining feature of the face as it appears to be symmetrical and might illustrate traits like age or gender [3]. The shape and size of each auricle are specific and vary between each individual, and this variation helps us distinguish each other. The auricle is so highly variable that even in a single individual the two ears will not be identical [4]. The most important function of the auricle is to transmit the sound waves through the external acoustic meatus to the eardrum. Also considered as a cosmetic organ, it has more importance in the aesthetics and physiognomy of the face [5].

Like other features of the human body (such as iris, fingerprint, teeth imprints, footprints, vocal features, DNA typing of human tissue samples, prints, etc.), the auricle is also a distinctive feature of a person. The human ear possesses particular attributes that are specific to an individual because of changes in the morphology of the auricle. The morphology and morphometry of the auricle, along with other identifying features, could be used to identify corpses that were mangled and disfigured [6]. Recently it was discovered that imprints of the ear, just like the auricle, are also a unique personal characteristic [7, 8].

The ear lobule is the last part of the auricle to develop [9]. Ear lobe elongation is associated with the natural aging process [10]. The lobule is absent or rudimentary in Anthropoids and best developed in civilized races. It is a new feature that apparently serves no useful function unless it is pierced for carrying ornaments, tobacco tins etc. [11].

The primary aim of this study was to analyze the various morphometric measurements like ear length, ear width, lobule length, lobule width, ear index and lobule index of the left ear of the

medical students in Udaipur region. These measurements were further compared between different genders (males and females).

MATERIALS AND METHODS

This study was carried out among 100 students (50 Male and 50 Female) with age range from 18 to 25 years. All participants were from Sai Tirupati University, Udaipur, Rajasthan. The study was conducted in the Department of Anatomy, Pacific Institute of Medical Sciences, Umarda, Udaipur, Rajasthan, India.

The nature of the research work was explained to the participating volunteers, and written consent was taken from each participant before initiating the study. The general information and the basic demographic profile of the participants were obtained with the help of a questionnaire.

Inclusion criteria:

- Subjects with age from 18 to 25 y
- Subjects who were ready to participate

Exclusion criteria:

- Subjects with trauma to the ear
- Had a surgery performed on the ear
- Developmental defect of pinna
- Congenital anomalies of ear
- Refuse to participate

The parameters were measured for this study were:

- Total ear length of left ear measured from the topmost part of the pinna to the lower point of lobule (A-B).
- Ear width of left ear measured from the root to the maximum convexity of the helix (C-D).

- Ear lobule length of left ear measured from the lower most point where the external ear is attached near the head to the caudal extension of the free margin of the ear lobe (E-F).
- Lobule width of left ear measured from the caudal most point where the ear lobule is attached near the head and to the outermost part of the ear lobule which has the maximum transverse width (G-H).

- Left ear index (calculated):

$$\text{Ear index} = \frac{\text{Ear width}}{\text{Total ear length}} \times 100$$

- Left lobule index (calculated):

$$\text{Lobule Index} = \frac{\text{Lobule width}}{\text{Lobule length}} \times 100$$

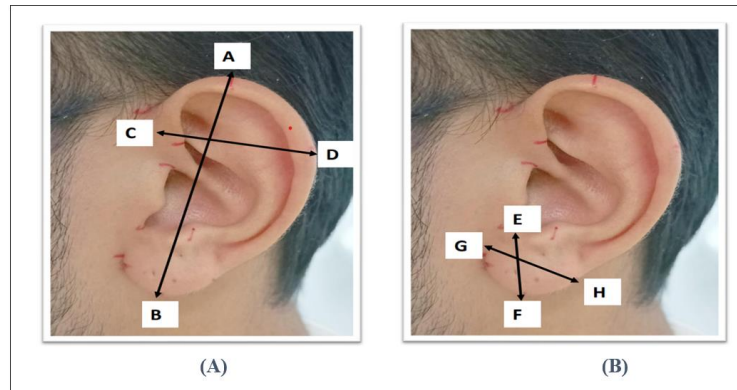


Fig. 1: External ear showing total ear length (A-B) and ear width (C-D) marking (A), External ear showing lobule length (E-F) and lobule width (G-H) marking (B)




Fig. 2: Showing measurements of (A) Total ear length, (B) Ear width

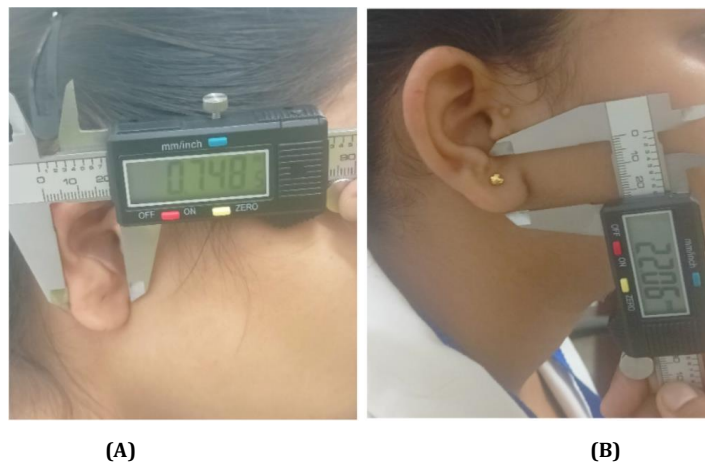

Fig. 3: Showing measurements of (A) lobule width (B) lobule length

The measurements were taken by using the digital caliper. In order to check the accuracy and reliability of the digital caliper, the observer took each measurement three times, and the two readings that are closer from the three were used. The data was entered into MS-Excel computer program. The statistical analysis for mean standard deviation of various parameters of the ear was calculated using SPSS (Statistical Product and Service Solution) software version 20.0. An independent t-test was applied for the evaluation of the differences between the male and female. A p-value of less than 0.05 was considered as statistically significant.

Observations

Total ear length of left ear, ear width of left ear, lobule length of left ear, lobule width of left ear, ear index and lobule index of left ear comparison between male and female subjects were showing in following table 1, table 2 and table 3.

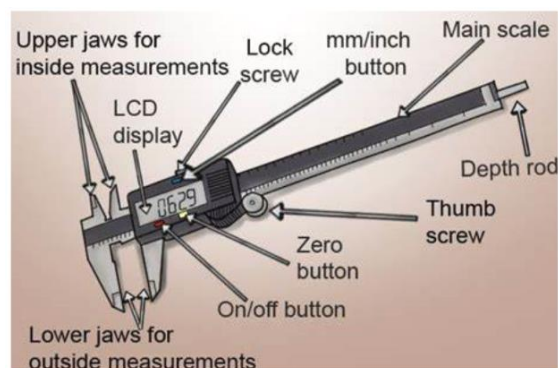


Fig. 4: Digital vernier caliper

Table 1: Shows mean values of left total ear length and ear width between male and female subjects using digital vernier caliper

Parameter (mm)	Male (mean±SD)	Female (mean±SD)	t value	p-value
Total ear length of left ear	62.22±3.91	58.13±3.28	5.6753	<0.0001
Ear width of left ear	31.60±2.06	29.49±1.76	5.5066	<0.0001

Table 2: Shows mean values of lobule length and lobule width of left ear between male and female subjects using digital vernier caliper

Parameter (mm)	Male (mean±SD)	Female (mean±SD)	t value	p-value
Ear lobule length of left ear	20.09±3.06	20.42±2.74	0.5690	0.5706
Ear lobule width of left ear	19.94±2.02	18.51±2.40	3.2234	0.0017

Table 3: Shows mean values of ear index and lobule index of left ear between male and female subjects

Parameter	Male(mean±SD)	Female(mean±SD)	t value	p-value
Left Ear index	50.90±3.63	50.79±3.08	0.1634	0.8706
Left lobule index	101.18±15.23	91.46±12.63	3.4738	0.0008

RESULTS AND DISCUSSION

Many studies have reported the fact that the ear measurements exhibit sexual dimorphism and the differences between the sexes are statistically significant, with a higher value in males [12].

The following results found from the study were:

The mean value of total ear length and ear width of left ear in female were found 58.13±3.28 mm and 29.49±1.76 mm, respectively. However, in males left total ear length and ear width were found 62.22±3.91 mm and 31.60±2.06 mm, respectively. Comparison of ear length and width were performed by independent t-test. Total ear length and ear width were significantly higher in male than female (p value<0.0001) in this study. Similar findings were observed in few studies (Shireen S *et al.* [12], Deopa D *et al.* [2] and D. Rani *et al.* [14]).

The mean value of lobule length and lobule width of left ear in female subjects were 20.42±2.74 mm and 18.51±2.40 mm, respectively. However, in male, lobule length and lobule width of left ear were 20.09±3.06 mm and 19.94±2.02 mm, respectively. Lobule length and lobule width of left ear were compared by independent t-test, it was found nonsignificant (p-value 0.5706) and significantly higher in male than female (p 0.0017), respectively. Verma P *et al.* reported significant difference for lobule length and lobule width on both side for both genders [13].

The mean value of ear index of left ear was 50.79±3.08 in female while 50.90±3.63 in males in this study. It was found nonsignificant (p 0.8706).

The mean value of lobule index of left ear 91.46±12.63 in female and 101.18±15.23 in male were found significant with higher value in male (p 0.0008).

Similar findings were observed by Prasad RJ *et al.* [15], while Ferrario VF *et al.* [16] found a significantly higher ear index in males than females. Verma P *et al.* reported that the ear index was more in

male on both sides whereas lobule index was more in female on both sides [13].

CONCLUSION

This study provides the mean values of total ear length, ear width, lobule length, lobule width, ear index and lobule index of left ear in medical students of Pacific Institute of Medical Sciences, Umarda, Udaipur, Rajasthan. Results according to genders who participated in the study where all dimensions (total ear length, ear width, lobule width and lobule index) were higher in male as compared to the female subjects. Although, there was no significant difference observed in lobule length and ear index of left ear of male and female subjects.

ACKNOWLEDGEMENT

We would like to express our heartfelt gratitude to staff and colleagues of department of Anatomy, Pacific Institute of Medical Sciences, Umarda, Udaipur for their help and support and all the male and female subjects who participated in this work.

FUNDING

No funding sources

AUTHORS CONTRIBUTIONS

All the authors have contributed equally

CONFLICT OF INTERESTS

Declared none

REFERENCES

1. Brucker MJ, Patel J, Sullivan PK, Department of Plastic Surgery, Brown Medical School and Rhode Island Hospital, Providence. A morphometric study of the external ear: age and sex-related differences. *Plast Reconstr Surg.* 2003 Aug 1;112(2):647-53. doi: 10.1097/01.PRS.0000070979.20679.1F, PMID 12900628.

2. Deopa D, Thakkar HK, Prakash C, Niranjana R, Barua MP. Anthropometric measurements of external ear of medical students in Uttarakhand Region. *J Anat Soc India*. 2013 Jun 1;62(1):79-83. doi: 10.1016/S0003-2778(13)80018-4.
3. Britto J, Panchal P, Prasad A, Kumari R, Kumari S. Photogrammetric morphometric analysis of auricle. *Int J Med Sci Public Health*. 2018 Jun 1;7(6):440-3. doi: 10.5455/ijmsph.2018.1130207032018.
4. Keith A. The significance of certain features and types of the External Ear. *Nature*. 1901;65(1671):16-21. doi: 10.1038/065016a0.
5. Akpa AO, Ibiam AA, Ugwu C. Anthropometrical study of the pinna among southeast Nigerians. *J Exp Res*. 2013;1:47-50.
6. Iannerelli A. Ear identification, forensic identification series. Fremont, CA: Paramount Publishing; 1989.
7. Krishan K, Kanchan T. Identification: prints-ear. *Encyclopedia of forensic and legal medicine*. In: Identification: prints-ear, CINII Research; 2016. p. 74-80.
8. Meijerman I. Inter and intra-individual variation in ear prints. Leiden University; 2006 Feb 15.
9. Standring S, Ellis H, Healy J, Johnson D, Williams A, Collins P. *Gray's anatomy: the anatomical basis of clinical practice*. *AJNR Am J Neurorad*. 2005 Nov;26(10):2703.
10. McKinney P, Giese S, Placik O. Management of the ear in rhytidectomy. *Plast Reconstr Surg*. 1993 Oct 1;92(5):858-66. doi: 10.1097/00006534-199392050-00012, PMID 8415967.
11. Sharma A, Sidhu NK, Sharma MK, Kapoor K, Singh B. Morphometric study of ear lobule in northwest Indian male subjects. *Anat Sci Int*. 2007 Jun;82(2):98-104. doi: 10.1111/j.1447-073X.2007.00166.x, PMID 17585565.
12. Shireen S, Karadkhekar VP. Anthropometric measurements of human external ear. *J Evol Med Dent Sci*. 2015 Jul 23;4(59):10333-8. doi: 10.14260/jemds/2015/1489.
13. Verma P, Sandhu HK, Verma KG, Goyal S, Sudan M, Ladgotra A. Morphological variations and biometrics of ear: an aid to personal identification. *J Clin Diagn Res*. 2016 May;10(5):ZC138-42. doi: 10.7860/JCDR/2016/18265.7876, PMID 27437349;ZC138.
14. Rani D, Krishan K, Sahani R, Baryah N, Kanchan T. Variability in human external ear anthropometry-anthropological and forensic applications. *Clin Ter*. 2021;172(6):531-41. doi: 10.7417/CT.2021.2374, PMID 34821348.
15. Prasad RJ, Shakya A, Acharya A, Neupane GP. Anthropometric study of the external ear: a comparative study. *Medphoenix*. 2022 Aug 19;7(1):36-41. doi: 10.3126/medphoenix.v7i1.43195.
16. Ferrario VF, Sforza C, Miani A, Tartaglia G. Craniofacial morphometry by photographic evaluations. *Am J Orthod Dentofacial Orthop*. 1993 Apr 1;103(4):327-37. doi: 10.1016/0889-5406(93)70013-E, PMID 8480698.