

Original Article

EFFICACY OF TRIDHAM AND 1,2,3,4,6-PENTA-O-GALLOYL- β -D-GLUCOSE IN REVERSING LIPID PEROXIDATION LEVELS AND MITOCHONDRIAL ANTIOXIDANT STATUS IN 7,12-DIMETHYLBENZENEANTHRACTHENE (DMBA) INDUCED BREAST CANCER IN SPRAGUE-DAWLEY RATS

STALIN RAMAKRISHNAN, KARTHICK DHARMALINGAM, SACHIDANANDHAM T. PANCHANATHAM, SHANTHI PALANIVELU

Department of Pathology, Dr. ALM Post-Graduate Institute of Basic Medical Sciences, University of Madras, Taramani Campus, Chennai 600113, India

Email: stalinrm6@gmail.com

Received: 23 Jun 2016 Revised and Accepted: 22 Jul 2016

ABSTRACT

Objective: To determine the effect of *Tridham* (TD) and 1,2,3,4,6-penta-O-galloyl- β -D-glucose (PGG) on lipid peroxidation levels and mitochondrial antioxidants status in experimental mammary carcinoma.

Methods: *Elaeocarpus ganitrus* (fruits), *Terminalia chebula* (seed coats), *Prosopis cineraria* (leaves), adult female albino rats of Sprague-Dawley strain weighing 170–190 g and 7,12-dimethylbenzanthracene (DMBA) were used for this study. Group I control rats, Group II rats mammary carcinoma induced with DMBA (25 mg in 1 ml olive oil) by gastric intubation. Group III, IV and V DMBA induced rats were treated with TD (400 mg/kg. b. wt/day), PGG (30 mg/kg. b. wt/day) and standard drug, Cyclophosphamide (30 mg/kg. b. wt/day), respectively for 48 d by gastric intubation. Group VI and VII rats served as TD and PGG treated controls, respectively for 48 d by gastric intubation. At the end of the experimental period, the rats were anaesthetized and sacrificed. Mammary glands were isolated and used for biochemical assays and histopathological evaluation.

Results: In rats with cancer, the lipid peroxide levels (LPO) were significantly increased and mitochondrial antioxidant levels were decreased. Treatment with TD and PGG decreased LPO levels and increased mitochondrial antioxidant status in mammary carcinoma bearing rats. Histopathological analysis also confirmed the therapeutic effect of TD and PGG. No significant adverse effect was observed in sole drug treated group of rats.

Conclusion: TD and PGG have definite therapeutic effect in experimental mammary carcinoma and inhibit growth of cancer cells by restoring mitochondrial antioxidant status and energy metabolism to normal states.

Keywords: Breast cancer, Antioxidant, *Tridham*, Pentagalloyl glucose, Phytochemical, oxidative stress, Cyclophosphamide

© 2016 The Authors. Published by Innovare Academic Sciences Pvt Ltd. This is an open access article under the CC BY license (<http://creativecommons.org/licenses/by/4.0/>)
DOI: <http://dx.doi.org/10.22159/ijpps.2016v8i9.13635>

INTRODUCTION

Breast cancer is a serious public health concern, being the second most common of all cancers and by far the most frequent reason of cancer death amongst women throughout world [1]. There is a continuing search for better and more effective herbal plants to treat breast cancer. Mitochondria play an important role in controlling the life and death of a cell. Mitochondria are central to oxidative phosphorylation and much of metabolism. They are also involved in many aspects of cell death. A major site of Reactive Oxygen Species (ROS) production, mitochondria have drawn considerable interest because it was recently discovered that mitochondrial ROS (mtROS) directly stimulate the production of proinflammatory cytokines and pathological conditions as diverse as malignancies, autoimmune diseases and cardiovascular diseases [2].

Reactive oxygen species (ROS) play a critical role in causing mitochondrial changes linked to cancer and metastasis. Increased ROS levels primarily emerging from the mitochondria are a noted feature of transformed cells that are variously attributed to inefficiencies in electron transport at the respiratory chain, increased metabolic demand, reduced ROS scavenging, oncogene-induced replicative stress and altered mitochondrial dynamics [3].

Several modes of cancer therapy, such as chemotherapeutic drugs and radiation, disrupt mitochondrial homeostasis and release cytochrome c, leading to apoptosome formation, which activates the intrinsic pathway of apoptosis. This is modulated by the extent of mitochondrial oxidative stress [4]. Accordingly, strategies are being developed for the targeted delivery of antioxidants to mitochondria [3].

Tridham is a Siddha formulation prepared in our laboratory, consisting of *Terminalia chebula*, *Elaeocarpus ganitrus* and *Prosopis cineraria* in a definite ratio. Previous studies carried out in our laboratory have established its therapeutic effect against AFB1 induced hepatocellular carcinoma rat model as well in cancer cell lines [5, 6].

Terminalia chebula is a deciduous tree, used in traditional medicines. It is reported to contain various biochemical compounds such as tannins, chebulinic acid, ellagic acid, gallic acid, punicalagin, flavonoids etc. It has been reported to have antioxidant, anticancerous, antidiabetic, antibacterial, antiviral, antifungal, antiulcer, antimutagenic, wound healing activities [7]. *Elaeocarpus ganitrus* is a widely used medicinal plant with various phytochemicals such as alkaloids, flavonoids, tannins, glycosides, and ellagic acid derivatives. It has been known to have various pharmacological activities like antioxidative, antitumour, antiasthmatic, antidepressant, antianxiety, antidiabetic, antiviral, and antihypertensive activities [8]. *Prosopis cineraria* is a highly valued plant in the Indigenous Systems of Medicine and it has been used in several ailments such as leprosy, dysentery, bronchitis, asthma, leucoderma, piles, muscular tremors, asthma, rheumatism and inflammations. It is also known to possess anticancer, anthelmintic, antibacterial, antifungal, antiviral and activities [9].

Phytochemical analysis carried out on the herbal formulation, *Tridham*, has established PGG as one of the active constituents present in this formulation. Tannins are predominantly found in plants as the core structure of the higher galloyl glucoses. Tannins are good direct antioxidants. Even the tannin-protein complex can

act as radical scavenger and radical sink. The amount of free PGG varies among different plant species, but is present at sufficient levels to allow direct isolation from a number of oriental herbs and other plants such as *Terminalia chebula* [10], *Rhuschinensis* Mill [11], *Paeonia suffruticosa* [12], *Paeonia lactiflora* [13] and by solvent extraction, liquid-liquid partition and chromatography separation.

Studies have shown the antioxidant potential of 1, 2, 3, 4, 6-penta-O-galloyl- β -D-glucose (PGG), investigated by cell system experiments such as radical detection, antioxidant enzyme assay, lipid peroxidation detection and cell viability assay [14]. With this background the present study was designed to study the therapeutic effect of the drug *Tridham* and PGG, an active phytochemical constituent in the preparation in experimental mammary carcinoma.

MATERIALS AND METHODS

TD drug is a combination of *Terminalia chebula* seed coats (family: Combretaceae), dry seeds of *Elaeocarpus ganitrus* (Syn. *E. sphaericus*) (family: Elaeocarpaceae) and *Prosopis cineraria* leaves (Syn. *P. spicigera* L.) (family: Leguminosae). The three ingredients were collected and given to the Department of Centre for Advance Study (CAS) in Botany, University of Madras, Guindy Campus, Chennai, India for botanical authentication and voucher specimens (CAS BH-16 *Terminalia chebula*, CAS BH-17 *Elaeocarpus ganitrus* and CAS BH-18 *Prosopis cineraria*) of the plant is retained in the department herbarium.

Formulation

The components were then mixed in equal proportions on weight basis to get TD mixture. The extract of TD was prepared in 3:1 (v/w) ratio by adding 30 mL of water to 10 grams of combined TD and mixed well. The mixture was mixed by using a shaker for 12 h. The mixture was subsequently filtered using filter paper, and the clear filtrate (aqueous extract) was collected in a beaker. The filtrate was then lyophilized under vacuum pressure to yield a powder. The lyophilized extract was stored in airtight containers in a dry dark place.

Rats

Female albino rats of Sprague-Dawley strain, aged between 50 to 55 d, were used for the study. The rats were purchased from the Central Animal House Block, Dr. ALM PG IBMS, University of Madras, Taramani Campus, Chennai-600113. They were maintained at an ambient temperature of $25 \pm 2^\circ\text{C}$ and 12/12 h of light/dark cycle. Rats were given standard commercial rat chow and water *ad libitum* and housed under standard environmental conditions throughout the study. The study has got the ethical committee clearance and the experimental animals were handled according to the University and Institutional Legislation, regulated by the Committee for the Purpose of Control and Supervision of Experiments on Animals (CPCSEA), Ministry of Social Justice and Empowerment, Government of India (IAEC No. 01/03/13).

Sources of chemicals

7, 12-dimethylbenz[α]anthracene were obtained from Sigma-Aldrich Fine Chemicals (St. Louis, MO, USA). The rest of the chemicals were obtained from Sisco Research Laboratory (SRL) Mumbai, India and were of analytical grade.

Induction of mammary carcinoma

Mammary carcinoma was induced in rats by a single dose of DMBA dissolved in 1 ml olive oil (25 mg/kg body weight) by method of [15] by gastric intubation. After overnight fasting, control rats were injected with same volume of 1 ml olive oil. After twelve weeks, mammary carcinoma was confirmed by palpation and histopathological examination.

Experimental design

The rats were divided into seven groups of six rats each. *Tridham* and PGG dissolved in distilled water were administered orally using an intragastric tube for a period of 48 d. anticancer drug, Cyclophosphamide was dissolved in 0.5 ml distilled water and used as a reference drug.

Group I: Normal Control rats (received 0.5 ml distilled water)

Group II: DMBA induced rats (25 mg/kg body weight by single dose orally) Vehicle olive oil

Group III: DMBA induced rats treated with *Tridham* (TD: 400 mg/kg b.w./day)

Group IV: DMBA induced rats treated with Pentagalloyl glucose (PGG: 30 mg/kg b.w./day)

Group V: DMBA induced rats treated with Cyclophosphamide (CYC: 30 mg/kg b.w./day)

Group VI: Normal Rats treated with *Tridham* alone (TD: 400 mg/kg b.w./day)

Group VII: Normal Rats treated with PGG alone (PGG: 30 mg/kg body weight/day)

After the experimental period (90 d of induction+48 d treatment), the rats from all seven groups were fasted overnight and sacrificed by cervical decapitation. Mammary gland and liver were immediately excised from the rats and weighed. Small pieces of representative tumour tissue were fixed in 10% formalin for histopathological studies. Viable tumour tissue was then dissected free of grossly necrotic and hemorrhagic area and separated from connective tissue and normal tissue. Portions weighing approximately 500 mg were cut, placed into plastic snap-cap vials and immediately frozen in liquid nitrogen. The vials were placed in a deep-freezer at -72°C and stored until assayed. At the time of assay, tissues were homogenized and used for biochemical assays.

Isolation of mitochondria from mammary gland

Mammary glands were removed and cooled in 0.3 M sucrose-EDTA, pH 7.4, on ice. All subsequent steps were carried out at $0-4^\circ\text{C}$. As much external connective tissue was removed as possible, and the tissues were blotted dry, weighed and minced very finely with small scissors. The tissue was then homogenized in a Potter-Elvehjem homogenizer (Sigma Chemical Co.) using two passes with a loose pestle and two passes with a tight pestle. The homogenate was strained through four layers of 10-gauge cheesecloth and the filtrate was centrifuged at $900 \times g$ for 5 min. The supernatant was centrifuged at $11,500 \times g$ for 10 min, washed twice in 5 ml sucrose-EDTA medium. At each step, the upper fatty layer was carefully removed by aspiration and the walls of the tubes were carefully wiped clean. The final mitochondrial pellet was suspended at 10 mg mitochondrial protein/ml sucrose-EDTA/1% bovine serum albumin (BSA) medium. The purity of the mitochondria was assessed by estimating succinate dehydrogenase activity [16]. Mitochondrial protein was estimated by the method of Lowary *et al.*, [17].

Histopathological analysis

Histopathological evaluation was carried out with mammary gland of control and experimental rats using standard protocols. Mammary gland tissue specimens were fixed in 10% formalin, routinely processed and embedded in paraffin wax. Sections were cut at 4 μm in thickness, stained with hematoxylin and eosin and viewed under light microscope for histopathological evaluation [18].

Biochemical analysis

Assay of mitochondrial lipid peroxides (LPO)

Tissue LPO was measured by the method of Ohkawa *et al.*, (1979) [19] using thiobarbituric acid. Peroxide and ascorbate induced lipid peroxidation was estimated by the method of Devasagayam and Tarachand (1987) [20].

Estimation of the levels of mitochondrial enzymic antioxidants

Superoxide dismutase (SOD) was assayed by the method of Marklund and marklund, (1974) [21]. Catalase (CAT) activity was assayed by the method of Sinha [22] and glutathione peroxidase (GPx) was assayed by the method of Rotruck *et al.*, [23].

Estimation of the levels of mitochondrial non-Enzymic antioxidants

Reduced glutathione (GSH) was determined by the method of Moron *et al.*, [24]. Vitamin C or ascorbic acid was estimated by the method

of Omaye et al., [25] and vitamin E was estimated by the method of Desai [26].

Statistical analysis

Values are given as the mean±SD of six rats. The results were statistically evaluated using Students *t* = test using SPSS 16 (Statistical Package for Social Sciences) software and one-way analysis of variance (ANOVA). Values of *p*<0.05 were considered statistically significant.

RESULTS

Effect of TD and PGG on histological alterations in mammary gland of experimental rats

Fig. 1 shows the histology of breast tissue in control and experimental animals. Normal rats showed mammary gland skin with underlying fibro fatty tissue containing scattered mammary gland ducts and bundles of skeletal muscles (fig. 1a) whereas DMBA-

induced rats showed parts of a tumour composed of hyperchromatic, pleomorphic cells with vesicular nuclei and moderate cytoplasm arranged in nests, sheets and acinar structures with numerous mitotic fig. (fig. 1b). Mammary carcinoma bearing rats treated with TD, PGG and control drug, cyclophosphamide showed foci of necrotic cells and fibro fatty tissue with few ducts (fig. 1c,1d and 1e).

Effect of TD and PGG on lipid peroxidation indices

Fig. 2 shows the effect of administration of the drug *Tridham* on lipid peroxidation and protein oxidation. The extent of lipid peroxidation was significantly higher in the mammary gland of rats with mammary carcinoma (Group II) as compared to control group of rats. The administration of *Tridham* and PGG (Group III and Group IV) significantly reduced DMBA-induced changes in lipid and protein oxidation and increased the antioxidants status. No significant changes were observed in drug control rats when compared to control (Group I).

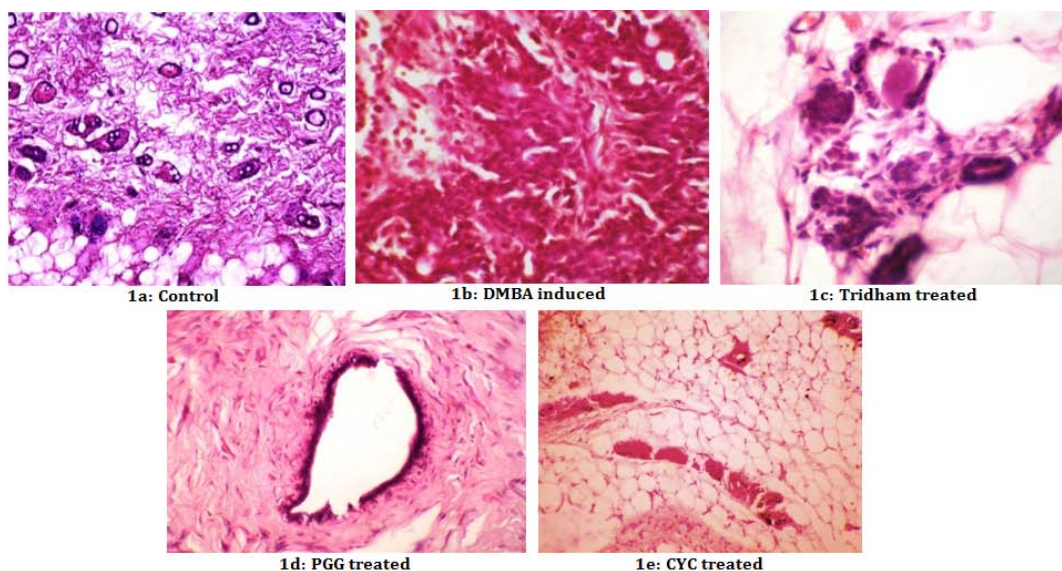


Fig. 1: Histological section of mammary tissue of control and experimental rats

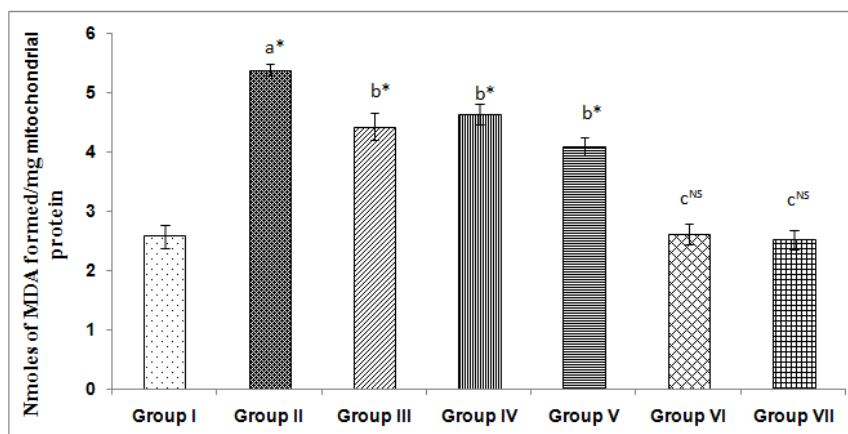


Fig. 2: Effect of TD and PGG on lipid peroxides in mammary gland of control and experimental animals. Values are expressed as mean±SD for six animals. Comparison is made as a-Group I vs Group II; b-Group II vs Groups III, IV and V; c-Group I vs Groups VI and VII. Statistical significance: *P<0.05. NS: Non significant

Effect of TD and PGG on enzymic and non-enzymic antioxidants status

The activities of enzymatic antioxidants, like SOD, CAT and GPx in the mammary tissue of control and experimental rats are

represented in table 1. The status of these enzymes was significantly lowered in DMBA-induced (Group II) rats when compared to control (Group I) rats (*p*<0.05). On drug treatment (Group III and IV), the activities of these enzymes were found to be significantly (*p*<0.05) increased when compared with induced (Group II) rats. The drug

control rats (Group VI and Group VII) did not show any significant changes when compared to control (Group I) rats.

The levels of non-enzymic antioxidants namely GSH; vitamins C and E in mammary tissue of control and experimental rats are represented in table 2. In untreated DMBA-induced (Group II) rats, the levels of

GSH, vitamin C and vitamin E were significantly decreased when compared to control (Group I) rats. In drug-treated (Group III and IV) rats, the levels of GSH and vitamins C and E ($p < 0.05$) were significantly increased when compared with disease prone (Group II) rats. Drug control (Group VI and VII) rats did not show any significant variations when compared with control (Group I) rats.

Table 1: Effect of 'Tridham' and 'PGG' on activities of mitochondrial enzymatic antioxidants in mammary gland of control and experimental animals

Parameters	Group I	Group II	Group III	Group IV	Group V	Group VI	Group VII
Superoxide dismutase (unit/min/mg protein)	11.23±0.34	6.22±0.54 ^{a*}	9.61±0.29 ^{b*}	9.48±0.27 ^{b*}	9.57±0.31 ^{b*}	11.26±0.25 ^{cNS}	11.16±0.23 ^{cNS}
Catalase (μ _mol of H ₂ O ₂ consumed/min/mg protein)	3.23±0.19	1.32±0.09 ^{a*}	2.29±0.15 ^{b*}	2.34±0.12 ^{b*}	2.48±0.11 ^{b*}	3.2±0.18 ^{cNS}	3.13±0.14 ^{cNS}
Glutathione peroxidase (μ g of GSH consumed/min/mg protein)	6.43±0.14	3.87±0.12 ^{a*}	5.4±0.11 ^{b*}	4.45±0.15 ^{b*}	5.31±0.19 ^{b*}	6.39±0.13 ^{cNS}	6.44±0.16 ^{cNS}

Values are expressed as mean±SD for six animals. (group I, control rats; group II, tumour induced; group III, tumour induced+TD treated; group IV tumour induced+PGG treated; group V, DMBA induced+CYC treated; group VI, control+TD; group VII PGG+control). Comparison is made as a-Group I vs Group II; b-Group II vs Groups III, IV and V; c-Group I vs Groups VI and VII. Statistical significance: * $P < 0.05$. NS: Non-significant.

Table 2: Effect of 'Tridham' and 'PGG' on activities of mitochondrial non enzymatic antioxidants in mammary gland of control and experimental animals

Parameters	Group I	Group II	Group III	Group IV	Group V	Group VI	Group VII
Vitamin C (mg/g wet tissue)	15.65±0.47	9.69±0.61 ^{a*}	13.17±0.57 ^{b*}	13.99±0.44 ^{b*}	13.58±0.49 ^{b*}	15.5±0.64 ^{cNS}	15.47±0.52 ^{cNS}
Vitamin E (mg/g wet tissue)	22.16±0.3	14.47±0.92 ^{a*}	18.7±0.72 ^{b*}	19.6±0.88 ^{b*}	20.12±1.8 ^{b*}	22.1±1.93 ^{cNS}	21.96±0.43 ^{cNS}
Reduced glutathione (μ g/mg protein)	8.12±0.32	4.09±0.39 ^{a*}	6.15±0.47 ^{b*}	6.78±0.5 ^{b*}	6.5±0.48 ^{b*}	8.04±0.29 ^{cNS}	8.15±0.38 ^{cNS}

Values are expressed as mean±SD for six animals. (group I, control rats; group II, tumour induced; group III, tumour induced+TD treated; group IV tumour induced+PGG treated; group V, DMBA induced+CYC treated; group VI, control+TD; group VII PGG+control). Comparison is made as a-Group I vs Group II; b-Group II vs Groups III, IV and V; c-Group I vs Groups VI and VII. Statistical significance: * $P < 0.05$. NS: Non-significant.

DISCUSSION

In recent years, there has been considerable emphasis on the identification of plant products with potent antioxidant property as possible anti carcinogens. Screening of various bioactive compounds from plants has led to the discovery of new medicinal drug which have efficient protection and treatment roles in against various diseases [27]. Compelling data from laboratory studies, epidemiological investigations and human clinical trials indicate that flavonoids from plant sources have an important role on cancer prevention and therapy. Epidemiological studies suggest that flavonoids play an important role in the prevention of carcinogenesis [28, 29].

Lipid peroxidation has been hypothesized to be a major mechanism of cell damage by free radicals. Oxidative stress resulting from the imbalance between pro-oxidant and antioxidant states, damages DNA, proteins, cell membranes and mitochondria and seems to play a role in human breast carcinogenesis [30]. Increased levels of lipid peroxides observed by us in the cancer bearing animals are consistent with these reports.

Apart from the enzymic antioxidants, non-enzymic antioxidants such as, GSH, vitamin C and vitamin E also play a vital role in protecting the cells from oxidative stress. The levels of these antioxidants were significantly lowered in the experimental animals with mammary carcinoma. Mitochondrial GSH plays a critical role in maintaining cell viability through the regulation of mitochondrial inner membrane permeability by maintaining sulphhydryl groups in the reduced state. The GSH level was restored to near normal level in drug treated rats, which could be attributed to the antioxidant potency of the formulation.

Oxidative stress resulting from an imbalance between prooxidant and antioxidant status seems to play an important role in breast cancer [31]. Improper balance between production of ROS and antioxidant defense system have been defined as oxidative stress in various pathological conditions [32]. Primary antioxidants such as SOD, GPx, CAT and GST

protect the cells against damage caused by reactive oxygen metabolites [33]. The reduction in antioxidant level indicates the inability of these defense systems to scavenge the enormous quantity of free radicals produced during mammary carcinoma development.

Non-enzymic antioxidants like GSH, vitamin E and vitamin C have been shown to ameliorate adverse effects associated with free radical damage in cancer therapy and to reduce the recurrence of breast cancer [34]. The lowered levels vitamin E and vitamin C are not sufficient to counter the high levels of reactive oxygen species produced in breast cancer. This may lead to oxidative stress, leading to cellular and molecular damage thereby resulting in cell proliferation and malignant progression [31]. GSH serves as substrate for glutathione peroxidase [GPx], an enzyme that functions to remove H₂O₂ that oxidizes it to GSSG. Vitamin E has an operative role in cancer. It is an excellent lipid soluble chain breaking antioxidant in the presence of co-operative antioxidants like vitamin C, carotenoids, etc. [35]. Vitamin E prevents lipid peroxidation and this prevents membrane damage and modification of low-density lipoproteins [36].

Upon administration of *Tridham* and PGG to mammary carcinoma rats, the activities of enzymic antioxidants and non-enzymic antioxidants were increased when compared to diseased rats. This may be due to the additive or synergistic action of flavonoids, isoflavonoids and ascorbic acid present in the drug. Flavonoids and isoflavonoids have potent antioxidant activity relevant to cancer [37, 38]. Glycoside linked flavonoids are responsible for antioxidants effects [39]. This accounts for the anti tumour property of the drug through modulating the ROS and lipid peroxidation. Flavonoids also play an important role in the prevention of breast cancer, prostate cancer and atherosclerosis [40].

CONCLUSION

The above experimental results obtained indicate that the drug has definite therapeutic efficacy against experimental mammary carcinoma. Due to its efficacy therapeutic property and non-toxic

nature, it may be considered as a safe pharmacological drug in the field of cancer therapy without adverse effects.

CONFLICT OF INTERESTS

Declared none

REFERENCES

- Ferlay J, Soerjomataram I, Dikshit R, Eser S, Mathers C, Rebelo M. Cancer incidence and mortality worldwide: sources, methods and major patterns in globocan 2012. *Int J Cancer* 2015;136:359-86.
- Xinyuan L, Pu F, Jietang M, Eric TC, Hong W, Xiao FY. Targeting mitochondrial reactive oxygen species as novel therapy for inflammatory diseases and cancers. *J Hematol Oncol* 2013;6:19.
- Hamanaka RB, Chandel NS. Mitochondrial reactive oxygen species regulate cellular signaling and dictate biological outcomes. *Trends Biochem Sci* 2010;35:505-13.
- Song IS, Kim HK, Jeong SH, Lee SR, Kim N, et al. Mitochondrial peroxiredoxin III is a potential target for cancer therapy. *Int J Mol Sci* 2011;12:7163-85.
- Vijaya R, Ravindran J, Sachdanandam P, Shanthi P. Potential antioxidant role of tridham in managing oxidative stress against aflatoxin-b1-induced experimental hepatocellular carcinoma. *Int J Hepatol* 2012. <http://dx.doi.org/10.1155/2012/428373>.
- Ravindran J, Vijaya R, Sachdanandam P, Shanthi P. Potential therapeutic role of Tridham in human hepatocellular carcinoma cell line through induction of p53 independent apoptosis. *BMC Complementary Altern Med* 2013;13:323.
- Suryaprakash DV, Sreesatya N, Sumanjali A, Meena V. Pharmacological review on *Terminalia chebula*. *Int J Res Pharm Biomed Sci* 2012;3:2.
- Amitdadhich, Anirudha Rishi, Gargisharma Subhash Chandra. Phytochemicals of *Elaeocarpus* with their therapeutic value: a review. *Int J Pharm Biol Sci* 2013;4:591-8.
- Stellaa R, Narayanan N. Pharmacognostical and antimicrobial studies of the stem barks of *Prosopis Cineraria* (L) druce. *Res Rev: J Pharmacogn Phytochem* 2009;1:115-8.
- Ahn MJ, Kim CY, Lee JS, Kim TG, Kim SH. Inhibition of HIV-1 integrase by galloyl glucoses from *Terminalia chebula* and flavonol glycoside gallates from *Euphorbia pekinensis*. *Planta Med* 2002;68:457-9.
- Huh JE, Lee EO, Kim MS, Kang KS, Kim CH, Cha BC, et al. Penta-O-galloyl-beta-D-glucose suppresses tumor growth via inhibition of angiogenesis and stimulation of apoptosis: roles of cyclooxygenase-2 and mitogen-activated protein kinase pathways. *Carcinogenesis* 2005;268:1436-45.
- Oh GS, Pae HO, Oh H, Hong SG, Kim IK, Chai KY, et al. *In vitro* anti-proliferative effect of 1,2,3,4,6-penta-O-galloyl-beta-D-glucose on human hepatocellular carcinoma cell line, SK-HEP-1 cells. *Cancer Lett* 2001;1741:17-24.
- Cavalher-Machado SC, Rosas EC, Brito Fde A, Heringe AP, Oliveira RR, Kaplan MA, et al. The anti-allergic activity of the acetate fraction of *Schinus terebinthifolius* leaves in IgE induced mice paw edema and pleurisy. *Int Immunopharmacol* 2008;8:1552-60.
- Mei JP, Kyoung AK, Rui Z, Dong OK, Zhi HW, Keun HL, et al. Antioxidant properties of 1,2,3,4,6-penta-O-galloyl-beta-D-glucose from *Elaeocarpus sylvestris* var *ellipticus*. *Food Chem* 2009;115:412-8.
- Welsch CW. Factors affecting the growth of carcinogen induced rats mammary carcinomas. A review and tribute to charles brenton huggins. *Cancer Res* 1985;45:3415-43.
- Slater EC, Bonner WD. Effect fluoride on succinate oxidase system. *Biochem J* 1952;52:185-96.
- Lowry OH, Rosenbrough NJ, Farr AL, Randall RJ. Protein measurement with the Foli's phenol reagent. *J Biol Chem* 1951;193:265-76.
- Culling CFA. Handbook of histopathological and histochemical techniques. 3rd ed. Butterworth and Co., London; 1974. p. 69.
- Ohkawa H, Ohishi N, Yagi K. Assay for lipid peroxides in animal tissues by thiobarbituric acid reaction. *Anal Biochem* 1979;95:351-8.
- Devasagayam TPA, Tarachand V. Decreased LPO in the rat kidney during gestation. *Biochem Biophys Res Commn* 1987;45:469-74.
- Marklund S, Marklund G. Involvement of superoxide anion radical in the autooxidation of pyrogallol and a convenient assay for superoxide dismutase. *Eur J Biochem* 1974;47:469-74.
- Sinha AK. Colorimetric assay of catalase. *Anal Biochem* 1972;47:389-94.
- Rotruck JT, Pope AL, Ganther HE, Swanson AB, Hajeman DG, Hoekstra WG. Selenium-biochemical role as a component of glutathione purification and assay. *Science* 1973;179:588-90.
- Moron MS, Depierre JW, Mannervik B. Levels of glutathione, glutathione reductase and glutathione S-transferase activities in rat lung and liver. *Biochim Biophys Acta* 1979;582:67-78.
- Omaye ST, Turnbull JD, Sauberlich HE. Selected methods for the determination of ascorbic acid in animal cells, tissues, and fluids. *Methods Enzymol* 1979;62:3-11.
- Desai ID. Vitamin E analysis methods for animal tissues. *Methods Enzymol* 1984;105:138-47.
- Margret R, Murugan N, Praveen KP, Mimal VS. Christudas *in vitro* studies on alpha-glucosidase inhibition, antioxidant and free radical scavenging properties of tecoma stans. *Int J Pharm Pharm Sci* 2015;7:44-9.
- Diane F, Birt H, Weiqun W. Dietary agents in cancer prevention. *Flavonoids Isoflavonoids* 2001;90:157-77.
- Kandaswami C, Middleton E. Free radical scavenging and antioxidant activity of plant flavonoids. *Adv Exp Med Biol* 1994;366:351-76.
- Agnieszka Jeziarska-Drutel, Steven A Rosenzweig, Carola A Neumann. Role of oxidative stress and the microenvironment in breast cancer development and progression. *Adv Cancer Res* 2013;119:107-25.
- Khanzode SS, Muddeshwar MG, Khanzode SD, Dakhale GN. Antioxidant enzymes and lipid peroxidation in different stages of breast cancer. *Free Radical Res* 2004;38:81-5.
- Hussain SP, Hofseth LJ, Harris CC. Tumor suppressor genes: at the crossroads of molecular carcinogenesis, molecular epidemiology and human risk assessment. *Lung Cancer* 2001;2:7-15.
- Ray G, Batra S, Shukla NK, Deo S, Raina V, Ashok S, et al. Lipid peroxidation, free radical production and antioxidant status in breast cancer. *Breast Cancer Res Treat* 2000;59:163-70.
- Borek C. Dietary antioxidants and human cancer. *Integr Cancer Ther* 2004;3:333-41.
- Burton PB, Hogben CE, Joannou CL, Clark AG, Hsuan JJ, Totty NF, et al. Heart fatty acid binding protein is a novel regulator of cardiac myocyte hypertrophy. *Biochem Biophys Res Commun* 1994;205:1822-8.
- Stahl W, Sies H. Antioxidant defense: vitamins E and C and carotenoids. *Diabetes* 1997;2:14-8.
- Cesquini M, Torsoni MA, Stoppa GR, Ogo SH. t-BOOH-induced oxidative damage in sickle red blood cells and the role of flavonoids. *Biomed Pharmacother* 2003;57:124-9.
- Liu LZ, Fang J, Zhou Q, Hu X, Shi X, Jiang BH. Apigenin inhibits expression of vascular endothelial growth factor and angiogenesis in human lung cancer cells: implication of chemoprevention of lung cancer. *Mol Pharmacol* 2005;68:635-43.
- Chakraborty S, Roy M, Taraphdar AK, Bhattacharya RK. Cytotoxic effect of root extract of *Tiliaco raracemos* and oil of *Semecarpus anacardium* nut in human tumour cells. *Phytother Res* 2004;18:595-600.
- Guo Q, Rimbach G, Moini H, Weber S, Packer L. ESR and cell culture studies on free radical-scavenging and antioxidant activities of isoflavonoids. *Toxicology* 2002;179:171-80.

How to cite this article

- Stalin Ramakrishnan, Karthick Dharmalingam, Sachidanandham T Panchanatham, Shanthi Palanivelu. Efficacy of *Tridham* and 1,2,3,4,6-penta-O-galloyl-B-D-glucose in reversing lipid peroxidation levels and mitochondrial antioxidant status in 7,12-dimethylbenzanthracene (DMBA) induced breast cancer in sprague-dawley rats. *Int J Pharm Pharm Sci* 2016;8(9):288-292.