

Case Study

STUDY ON VARIATIONS IN THE BRANCHING PATTERN OF ARCH OF AORTA

GAVISHIDDAPPA A. HADIMANI^{1*}, ISHWAR B. BAGOJI¹, BALAPPA M. BANNUR², SHARDHA BAI RATHOD³

¹Lecturer, ²Professor and Head Dept. of Anatomy, ³Asst. Prof. Dept of Dentistry, Blde University's Shri B M Patil Medical College, Hospital and Research Centre, Vijayapur, Karnataka, India, 586103.

Email: gavish.hadimani@yahoo.com

Received: 13 May 2015 Revised and Accepted: 06 Jul 2015

ABSTRACT

The most common branching pattern of the aortic arch in humans comprises of three great vessels, during the routine dissection for 1st MBBS we encountered variations in the branches of arch of aorta, so the study was conducted to know the percentage and common type of variations. The study was performed on thirty hearts, among the 30 hearts 28 were adult formalin preserved cadavers and two were pre-dissected separate hearts with the aortic arches en-bloc. The sex and age of the cadavers were not assessed in the study. A study was conducted for a period of two years. The purpose of the study was to measure the percent of variation in the branching pattern of an arch of aorta. The most common branching pattern of the aortic arch in humans comprises of three great vessels; first, the brachiocephalic trunk, then the left common carotid artery and finally the subclavian artery. In the present study the most common aortic arch branching pattern was found in 86.67%, additional artery that is four branches were observed in 10% of the cases and two arteries from the arch of aorta, were noted in 3.33% of the case studied. Different branching patterns of the arch of aorta observed in this study and these can assist surgeons in performing safe and effective surgeries in the superior mediastinum.

Keywords: Common carotid artery, Vertebral artery, Subclavian artery, Left brachiocephalic trunk.

INTRODUCTION

The most common branching pattern of the aortic arch in humans comprises of three great vessels; first, the brachiocephalic trunk, then the left common carotid artery and finally the subclavian artery. This pattern occurs in 65-80% of the instances [1].

Arterial derangements within the thorax are common, complex and can assume many diverse configurations. These derangements in origin and course of the main vessels occurring either individually or in combination with other cardiovascular defects are mostly explainable on ontogenic basis, which can thus be blamed for a myriad of clinically relevant anomalies [2].

The major branches of arch of an aorta are the outstanding ways for blood supply to the head and upper limb, and are of particular interest in clinical angiography. The proximal segment of these branches and of the aortic arch is common sites for atherosclerosis with clinical consequences for blood supply to the brain [3]. Anomalies of origin and distribution of these branches can cause changes in cerebral haemodynamics that may lead to cerebral abnormalities [4].

CASE REPORT

This study was performed on thirty hearts, among the 30 hearts 28 were adult formalin preserved cadavers and two pre-dissected separate hearts with the aortic arches en-bloc obtained from the Department of Anatomy. The sex and age of the cadavers were not to be assessed in this study. Study was conducted during the period from 2012-2014.

In the present study, the most common aortic arch branching pattern was found in 26 (86.67%) of 30 specimens. In this pattern the three major branches that are brachiocephalic trunk, left common carotid artery, and left subclavian artery originated independently from the arch of aorta [fig. 1]. The variations in aortic arch regarding its branching pattern were observed in the remaining 4 (13.33%) hearts.

In three cadavers (10%) an additional artery was noted in addition to the three branches and four branches had their origin from the upper convex surface of the arch. The additional branch was traced and found to be left vertebral artery. It had an independent origin from the aortic arch. It was situated between the lineages of the left common carotid and the left subclavian arteries.

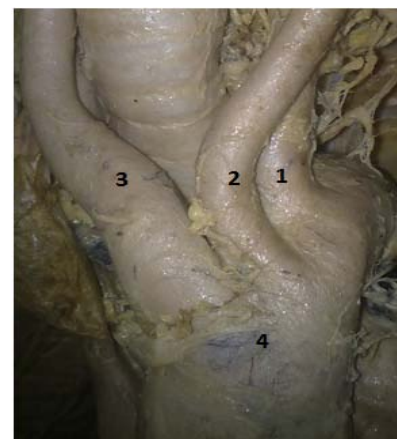


Fig. 1: Three branches arising from the arch of aorta, 1-Left subclavian, 2-Left Common carotid Artery, 3-Brachiocephalic trunk, 4-Arch of aorta

The arising sequence of the four arteries on aortic arch from right to left was brachiocephalic trunk, left common carotid artery, left vertebral artery and left subclavian artery [fig. 2, 3]. One of the brachiocephalic trunk shows trifurcating termination where the brachiocephalic trunk is terminated by dividing into three branches, namely 1) right common carotid artery, 2) right vertebral artery, 3) right subclavian artery [fig. 3].

In one cadaver (3.33%) only two branches originated from the arch of aorta, 1st was brachiocephalic trunk and the second one was common trunk for both left common carotid artery and left subclavian artery. The common trunk which originated from the arch of the aorta can be called as left brachiocephalic trunk [fig. 4].

DISCUSSION

Anatomical variations in the major vessels have been reported earlier. The critique of literature shows many variations. The Aortic Arch anomalies are also associated with chromosome 22q11 deletion [5].

In the present study, the three major branches of the arch of aorta originated independently in 26 (86.67%) cases. This finding was almost similar to that of Shin *et al.* [6] (84%) in other studies by Lippert and Pabst where 70% of patients had this common branching pattern and Paraskevas *et al.* who found it in only 65% of hearts [7].

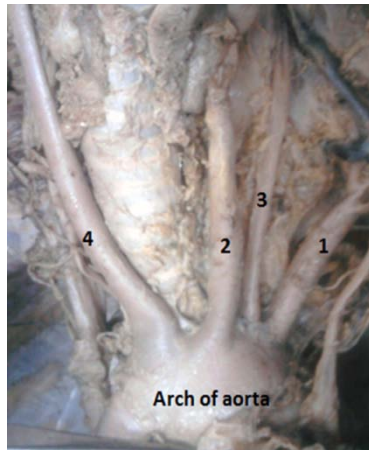


Fig. 2: Four branches arising from the arch of aorta, 1-Left subclavian, 2-Left Common carotid Artery, 3-Left vertebral artery, 4-Brachiocephalic trunk

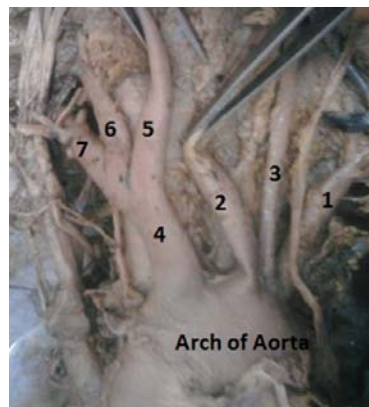

Fig. 3: Four branches arising from the arch of aorta and the common trunk since 5,6and7: 1-Left subclavian artery, 2-Left Common carotid Artery, 3-Left vertebral artery, 4-Brachiocephalic trunk, 5-Right common carotid artery, 6-Right vertebral artery, 7-Right subclavian artery

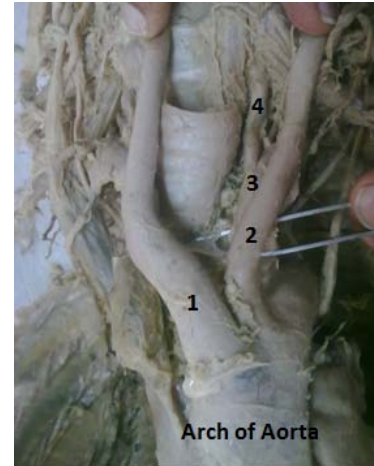


Fig. 4: Two branches from arch of aorta, 1-Brachiocephalic trunk, 2-Left brachiocephalic trunk, 3-Left subclavian artery, 4-Left vertebral artery

In the present study, an additional artery was noted in 3 (10%) cadavers out of four variations and thus, four branches had their origin from the arch. An independent separate origin of the left vertebral artery from the arch of an aorta was identified between the left common carotid artery and left subclavian artery. Shin *et al.* found this variation in 5.8% of the cases [6]. In accord with the present results Shin *et al.* found that the most frequent variant (2.4-5.8%) is the left vertebral artery, arising directly from the arch of the aorta between the left common carotid artery and left subclavian artery. Paraskevas *et al.* also stated that the left vertebral artery may arise between the left common carotid and the subclavian arteries [7]. While Best and Bumpers reported a case in which the right vertebral artery originated directly from the aortic arch [8]. Similar variations have been described in earlier studies [9, 10].

In the study one (3.33%) of the specimen shows only two great vessels originated from the upper convex surface of the aortic arch. The first was brachiocephalic trunk and the second was common trunk, which comprised the left common carotid artery and left subclavian artery. The common trunk can be called as left brachiocephalic trunk because which give similar branches like right brachiocephalic trunk. Such cases were not reported to the best of our cognition, while Paraskevas *et al.* [7] found similar variation in 27% of the cases where the common trunk gave rise to brachiocephalic trunk and left common carotid artery, but left subclavian artery aroused separately from an arch of aorta. Similar to Paraskevas *et al.* other authors like Best and Bumpers, and Beigelman *et al.* found it in 8% of their studied cases [8, 11]. Table 1 shows a comparison of the present study with the other references.

Table 1: Comparison of present study with previous study

	Shin <i>et al.</i> [6]	Paraskevas <i>et al.</i> [7]	Best and Bumpers <i>et al.</i> [8]	Beigelman <i>et al.</i> [11]	Present study
Three arteries	84%	65%			26 (86.67%)
Four artery	5.8%	2.4-5.8%			3 (10%)
Two artery		27%	8%	8%	1 (3.33%)

CONCLUSION

To conclude finally, the different branching patterns of the arch of aorta observed in this study and these can assist surgeons in performing safe and effective surgeries in the superior mediastinum. Furthermore, it is recommended to search for other variations of supra aortic arteries of the neck that may accompany them.

CONFLICTS OF INTERESTS

All authors declare that there is no conflict of interest

REFERENCES

1. Mligiliche NL, Isaac ND. A three branches aortic arch variant with a bi-carotid trunk and a retro-esophageal right subclavian artery. *Int J Anatomical Variations* 2009;2:11-4.
2. Nathan H, Seidel MR. The association of a retrosophageal right subclavian artery, a right-sided terminating thoracic duct, and a left vertebral artery of aortic origin: anatomical and clinical considerations. *Acta Anat (Basel)* 1983;117:362-73.
3. Zamir M, Sinclair P. Origin of brachiocephalic trunk, left carotid and left subclavian arteries from the arch of human aorta. *Invest Radiol* 1991;26:128-33.

4. Bernardi L, Dettori P. Angiographic study of a rare anomalous origin of vertebral artery. *Neuroradiol* 1975;9:43-7.
5. Momma K, Matsuoka R, Takao A. Aortic arch anomalies associated with chromosome 22q11 deletion (CATCH 22). *Pediatr Cardiol* 1999;20:97-102.
6. Shin Y, Chung Y, Shin W, Im S, Hwang S, Kim B. A morphometric study on cadaveric aortic arch and its major branches in 25 Korean adults: the perspective of endovascular surgery. *J Korean Neurosurg Soc* 2008;44:78-83.
7. Paraskevas G, Agios P, Stavrakas M, Stoltidou A, Tzaveas A. Left common carotid artery arising from the brachiocephalic trunk: a case report. *Cases J* 2008;1:83.
8. Best IM, Bumpers HL. Anomalous origins of the right vertebral, subclavian, and common carotid arteries in a patient with a four-vessel aortic arch. *Ann Vascular Surgery* 2002;16:231-4.
9. Hadimani GA, Bagoji IB, Bannur BM, Bulagouda RS, Patil BG, Sahana BN. Variation in the origin of left vertebral artery with increase in the length of brachiocephalic trunk. *Int J Curr Res Rev* 2013;5:6-9.
10. Hadimani GA, Desai SD, Bagoji IB, Sahana BN. Bilateral variation in the origin of vertebral artery. *J Pharm Sci Res* 2013;5:196-8.
11. Beigelman C, Mourey-Gerosa I, Gamsu G, Grenier P. New morphologic approach to the classification of anomalies of the aortic arc. *Eur Radiol* 1995;5:435-42.